

Drawing Damaged Bodies:

British Medical Art in the Early Twentieth Century

SAMUEL J. M. M. ALBERTI

SUMMARY: Historians are acutely aware of the role of art in medicine. Elaborate early modern works catch our eye; technical innovations attract analysis. This paper beats a different path by examining three little-known artists in early twentieth-century Britain who deployed what may seem like an outdated method: drawing. Locating the function of pencil and ink illustrations across a range of sites, we take a journey from the exterior of the living patient via invasive surgical operations to the bodily interior. We see the enduring importance of delineation against a backdrop of the mechanization of conflict and of imaging.

KEYWORDS: First World War, medical illustration, pathology, surgery, wounds

The mechanized conflict that wreaked havoc upon the human body in the early twentieth century stimulated a range of responses from the medical profession, including new technologies to diagnose and record injuries and pathologies. Radiology, improved photography, new printing techniques, and motion pictures were available to those who practiced and trained in anatomy, pathology and surgery. And yet during the First World War and its aftermath, older, simpler techniques endured: medical artists continued to draw with pen and pencil. Where did these practices sit within accelerating modernity and new modes of representation?

Historians have long been acutely aware of the role of art in medicine. We know a great deal about elaborate early modern works, from Albinus to Da Vinci, and technical innovations in the following centuries. But if we want to understand the everyday function of medical illustrations, we should include in our studies not only the most stunning and advanced depictions, but also smaller, simpler, everyday pictures that helped doctors to learn and to practice. Many such images from this period are photographs, but they were also hand-drawn. To demonstrate the marked endurance of the latter in an era associated with the former, here I discuss the work of little-known British medical artists in the early twentieth century who used deceptively simple hand-drawn techniques across a range of sites. I argue that to understand the role of the image in medicine—and surgery in particular—we need to look to media we might not classify as masterworks. We also need to look in different places, at their sites of production. One place historians of this period have already looked in some detail is the plastic surgery unit of the Queen’s Hospital in Sidcup Kent where the surgeon–artist Henry Tonks wielded his pastels so effectively in portraits of servicemen with devastating facial injuries.¹ But Tonks’s work was only one facet of a rich and varied visual culture even within Sidcup. From among the

contributors to this “image-saturated discipline of medicine” that extended far beyond Kent, I explore the work of the three pathological draftsmen I originally encountered while studying medical aspects of the First World War, stimulated in part by the centenary of the conflict.²

The choice of Kirkpatrick Maxwell, Dulcie Pillers, and Robert Matthews is therefore partly pragmatic: unlike other illustrators of this period, bodies of their original work survive (although barely, in Maxwell’s case) where others’ did not—which itself tells us about the lack of value placed upon these graphics. More strategically, their distinct artistic practices afford comparison between sites, and the works selected here chronologically span the 1910s, 1920s, and 1930s. One of these draftsmen is a woman; the gendering of the medical gaze has been eloquently addressed elsewhere, but Pillers’s work points to the growing number of women involved in this craft, which would become especially marked after the Second World War.³

More than their differences, however, what unites them makes them useful as the focus of study. They were selected because all three were prolific yet have received scant historical attention; they were selected because they worked across a range of venues; they were selected because although their skills encompassed healthy anatomy, creating universalized standards for textbooks that were read by generations of medical students, they all also depicted the damaged body; they were selected because all three went on to become involved in the professional community of medical artists in Britain; but most of all they were selected because against the grain of clinical photography, they all used the pencil not the camera.

Their works were “utility graphics,” rarely considered within canonical art history, yet which dominate modern Western visual experience. Medicine is littered with them, as are other areas of professional practice: archaeological site plans, technical drawings, scientific diagrams,

and mathematical flowcharts. In the words of James Elkins, they are “half pictures or hobbled versions of full pictures, [unfairly considered] bound by the necessity of performing some utilitarian function and therefore unable to mean more freely.” When considered more carefully, however, “far from being inexpressive, they are fully expressive, and capable of as great and nuanced a range of meaning as any work of fine art.”⁴ Those I consider here were rapidly drawn, sometimes published, sometimes kept on file next to other media. They were neither framed nor exhibited in any gallery, yet are rich in meaning, technique, and style.

Their techniques varied, but I want to present them as *delineation*: they use basic materials, they lack coding and generalizing, and they have precise and detailed rendering of boundaries. This classification is based on that of pathological artist Lucy Lyons, who practices delineation herself, basing her work on close observation and intense looking. To delineate, she argues, requires a level of understanding of the object of study.⁵ Often found in architecture and cartography, delineation is the extraction of particular elements, simplification, and clarification without caricature, emphasizing what the camera (usually) cannot. The delineator selects what is important and renders it with lines, a close study of the object based on the artists’ on-site encounter with it. Delineating, and studying others’ delineations, brings out unobserved details; and, crucially, it is undertaken *in situ*. This geographical significance brings us to the central intentions of this study.

My basic aim in assessing the location and function of these delineations is corrective. I want to draw our attention to this overlooked practice, to its overlooked practitioners in overlooked places, in a relatively overlooked period.⁶ The reasons for this neglect are not entirely clear, but the dearth of art historical attention after Gray’s *Anatomy* may be a symptom of the

distinction between *art* and *illustration*.⁷ I explore the form and function of Maxwell's, Pillers's, and Matthews's medical artworks not as high art, but as utility graphics; not *merely* nor *simply* but *revealingly* illustrative, as Berkowitz has recently emphasized.⁸

My specific objectives in pursuit of this underlying aim to explore sight and site are threefold: to understand *who* was undertaking pathological delineation, *where*, and *why*. As well as understanding the biographies of the three artists, answering the first will lead us to the medical patrons with whom their careers and credibility were entwined, including surgeons Sir George Makins, William Hey Groves, and David Middleton Greig. Answering the second will involve establishing a historical geography of sites for medical illustration in this period, from bedside to theater to museum.⁹ Medical art was prevalent across these spaces; despite the practice of obscuring the spatial context of illustration, its value depended heavily, I will argue, on the artists' location.

This begs the final question: why delineate? Other media were available, and feasible; although unlike Tonks's work, for example, we don't have directly comparable photographs, the specter of photography looms throughout what follows.¹⁰ The reasons for use of the pencil and pen rather than the camera lie in the intended use of these images, especially for training; but nonetheless, I will conclude, drawing and photography developed and endured *in dialogue*.

Situating Medical Art

First, however, some context. The three artists discussed here were part of a long European trajectory of depicting the human body, which has already been eloquently described.¹¹ More specifically, they were heirs to a gritty British tradition that physically and visually situated the

artists within medical spaces discernable in artwork associated with the eighteenth-century physician and man-midwife William Hunter. The “grand naturalism” that Jan van Rymdyk introduced to the representations of the gravid uterus for Hunter in *Anatomia uteri humani gravidi* (1774) marked a disjuncture from the metaphor-laden settings of his Continental predecessors.¹² The artist locates himself (and therefore the viewer) in the immediate vicinity of the cadaver, which was no longer animated but very clearly *dead*.¹³ William’s younger brother John, as well as gathering and commissioning artwork as part of his anatomical endeavors, valued portraits of his patients as clinical proxies, translating the bedside encounter.¹⁴ Another brace of brothers, John and Charles Bell, continued this tradition: Charles’s “beautiful simplicity” and the pulleys and ropes holding up John’s cadavers showing that the artist was figuratively if not literally in the dissection room.¹⁵ More specifically, Lucy Lyons and others have traced pathological delineation in the sense considered here to another Scot, the morbid anatomist and medical artist Robert Carswell (1793–1857). “You should see these Delineations,” he wrote, “that you may appreciate their value *not as art, but as instruments of medical science* by means of which more precise, more accurate and more perfect information may be acquired and communicated respecting the various and numerous organic changes to which the human body is subject.”¹⁶

A different kind of representation emerged with the stark, normalized “remorsely sober woodcuts” of Henry Gray’s *Anatomy. Descriptive and Surgical* (1858).¹⁷ They exhibit a studied plainness, “a pragmatic anatomy” that set a benchmark for Anglophone medical artists.¹⁸ Although the illustrations were isolated, “thoroughly dead and in pieces,” their interiority located them in the dissection room again.¹⁹ Martin Kemp has dubbed Henry Vandyke Carter’s

innovative illustrations “style-less” but noted that this “manner is as much a style as any mode of presentation and exhibits its own kind of contrived rhetoric.”²⁰ (They were also, it should be noted, *placeless*.) This much-emulated technique was a powerful strand of a frank, fragmented, and business-like descriptive graphic tradition that endured in British medicine, as we shall see.

In the later nineteenth century, this descriptive tradition developed in both concert and tension with the medical photography, mirroring the symbiotic relationship between camera and brush in realism.²¹ Just as the realists used quasi-photographic codes and framings in their compositions, so too in medical places, Kemp argues, the camera “alter[ed] the parameters of representation in medicine,” infusing “a rhetoric of reality.”²² Although clinical photography did not become widespread for training and teaching until later in the century, photography had the impact of reinforcing the already austere style of medical art and reinforcing standardization. During the First World War and in the decades that followed, photography was in widespread use in medical settings that included the hospital ward, the asylum, and the medical museum.²³

By this time, photography was at the heart of a cluster of technical innovations.²⁴ Novel applications of the camera itself included photomicrography and stereoscopic anatomy.²⁵ Introducing another dimension, almost as soon as motion pictures became feasible they were applied to medical purposes, as for example in the Instruction Laboratory of the U.S. Army Medical Museum.²⁶ Radiology developed with breathtaking rapidity in the early 1900s and especially during the First World War.²⁷ There could be no doubt, of course, as to the proximity of the filmmaker, photographer, or radiologist to the patient (or corpse).

Still, among all this innovation, those who practiced medical art—*hand-drawn* medical art—began to emerge as a distinct professional community. In North America, training programs

were available in the interwar period, such as those at the Department of Medical Art at the University of Toronto (from 1925) and the University of Illinois (1921), which gradually brought the practice into the university space. Perhaps most significant was the Department of Art as Applied to Medicine at Johns Hopkins, founded by the expatriate Saxon Max Brödel in 1910–11. The Anglo-Australian neurosurgeon Hugh Cairns had studied in Baltimore and later dispatched the illustrator Audrey Arnott to study with Brödel. The only Briton to do so, she became a leading light in medical illustration in the United Kingdom, training other influential artists including Dorothy Davison and Margaret McLarty. This interwar community, which included the three who feature below, coalesced into the Medical Artists' Association, founded in 1949.²⁸

By this point, with the prominence of Brödel and, after the war, Frank Netter, Anglophone historiographical focus tends to shift across the Atlantic.²⁹ This obscures the budding professional cohort of medical illustrators in United Kingdom, whose output was testament to the enduring demand for older techniques. Medical students were still encouraged to draw as they had a century before, and their instructors made liberal use of blackboards and wallcharts in this period in the lecture theater (an important site I will not consider here in detail).³⁰ Students were especially encouraged to depict variations and abnormalities in the dissection room: this disciplined their vision and in effect collected the pathology. Surgeons often became skilled artists, none more so than Henry Tonks, who forsook medicine to teach art at the Slade School in London. During the First World War, Tonks generated a renowned series of touching pastel portraits from plastic surgery wards. He also made elegant single line delineations to help plan operations, often alongside and even *on* clinical photographs: adapted and hybrid clinical photography was not uncommon.³¹

Coloring, extraction, and overdrawing photographs were evident in publication too. It took the medical book trade a long time to introduce photography on a large scale—technical conservatism that was partly economical. While they made use of cheaper photographic half-tones and electrotype reproductions, publishers were still not about to ditch their existing stock of illustrations and blocks wholesale, but rather brought in new artworks gradually alongside their existing images, including those by Maxwell, Pillers, and Matthews. The production costs of even new textbooks could be reduced by deploying secondhand blocks, which could be used up to a quarter of a million times.³² It is not surprising, then, that publishers were slow to exploit new media; but eventually as it became economical, photography was introduced into most anatomical textbooks. X-rays appeared in *Cunningham's Textbook* in 1922, but not in Gray's until 1938.³³ By this time, argues Martin Kemp, "Gray's famous book had become a hodge-podge of styles and little short of a visual disaster."³⁴ Let us now consider these styles, these spaces, and the artists responsible—beginning with the delineations of "A.K.M."

Kirkpatrick Maxwell: Art in the Military Ward

A. Kirkpatrick Maxwell was born in Annan in southern Scotland in 1884.³⁵ After demonstrating an artistic bent at school, he apprenticed to a lithographer in Glasgow with a view to joining his grandfather's printing business. He also took evening classes in art, and with this combination of drawing and etching skills, he was introduced to Edward Bles, a zoologist at the University of Glasgow who engaged him to illustrate his work on the clawed toad.³⁶ This work, first undertaken in the laboratory, brought Maxwell's work to the attention of the wider scientific community and led to commissions from across the British Isles. He became especially in

demand as a medical illustrator, covering diverse fields including anatomy, embryology, histopathology, and proctology over the course of what would be a long career.

In the interwar period, Maxwell continued to work in laboratory settings, based in London at the University College Hospital Department of Anatomy and Embryology. He later spent time in New Zealand, but returned to Britain during the Second World War and settled in Cambridge. If “A.K.M.” (as he signed himself) is remembered, it is as a dissection-room illustrator for Gray’s *Anatomy, Descriptive and Applied* from the 1930s. He also contributed to Hamilton Bailey’s *Surgery of Modern Warfare*, Quain’s *Anatomy*, and Boyd and Hamilton’s *Embryology*, among others.³⁷ He drew all the plates for the textbook that would become *Faber’s Anatomical Atlas*.³⁸ He died in 1975, a quiet *doyen* of the medical art profession.

Of central concern here is Kirkpatrick Maxwell’s work during the First World War; this is geographically significant at the level of both region and site.³⁹ Soon after the outbreak of conflict in Europe, the director-general of the Army Medical Services at the War Office in London, Sir Alfred Keogh, began to gather material for the medical history of the war.⁴⁰ (In this he and his committee followed the example set by the U.S. surgeon general after the Civil War.)⁴¹ This would include photographs and other clinical illustrations.⁴² The Medical Research Committee (MRC, predecessor to the Medical Research Council) was instrumental in organizing this effort.⁴³ With the encouragement of the editorial board of the new *British Journal of Surgery*, the MRC funded two artists in France, their work to “be preserved as a national collection to illustrate for future study the various types of wound and disease met with in the war.”⁴⁴ Likewise the American Expeditionary Forces sent eight trained artists to the Western Front in 1918, and the U.S. Army Medical Museum’s Instruction Laboratory, noted earlier for its

pioneering medical filmmaking, was also staffed by illustrators and modelers during the war.⁴⁵ Medical illustrators traveled to unlikely places.

Camera and pencil worked side by side toward the end of the war; but at first this was not the case.⁴⁶ The MRC draftsmen were Sydney Sewell, who had already illustrated Gray's *Anatomy*, and Kirkpatrick Maxwell.⁴⁷ The latter had first ventured to France in 1915 at the invitation of the surgeon Sir George Makins and had sketched some of the first victims of poison gas after the Second Battle of Ypres. He returned at the behest of the MRC and as a sergeant in the Royal Army Medical Corps was stationed at the makeshift pathological laboratory in the Casino in Boulogne, run by the larger-than-life bacteriologist Almroth Wright. There, Maxwell's familiarity with the laboratory space and skills at the microscope were put to good use, combining lens and hand. He also depicted postmortem specimens; but his most striking works were of living patients in the hospital and at casualty clearing stations closer to the front. "Students will remain heavily indebted to Sgt Maxwell for the beauty and accuracy of these permanent records," wrote the MRC's Sir Walter Morley, who would acknowledge not only Maxwell's "professional skill, but also his untiring industry and devotion to duty which brought many hardships with it."⁴⁸ Crucially, such hardships were borne on location, at a bedside close to the theater of war, lending credibility to the artwork he made there.

Maxwell generated over a thousand images in France. These were sent back to the Royal College of Surgeons of England, which was housing the Army Medical War Collection on behalf of military medical services from across the Commonwealth. A selection was displayed in the college's Hunterian Museum from 1917. Curator Arthur Keith felt that Maxwell's "drawings made by the bedside record appearances which cannot be preserved or perpetuated in any other

way” and that he had “succeeded in rendering a permanent and faithful record of conditions which could not be recorded except by pen and brush.”⁴⁹ By contrast, although the camera was used extensively on hospital wards, whether for reportage or clinical purposes, photography was rarer at the front, presumably due to the equipment necessary.⁵⁰

Maxwell’s drawings for George Makins were published as early as 1915, and in the decade that followed were used in War Office medical manuals and in textbooks, in periodicals such as the *British Journal of Surgery*, and eventually in the *Medical History of the Great War*.⁵¹ Makins probably also used Maxwell’s pieces in lectures and teaching.⁵² In a twist of fate, however, most of the originals were destroyed when the Royal College was bombed during the Blitz in the next world war. Maxwell, who at Sir Cecil Wakeley’s call had signed up again to sketch wounded personnel, in 1953 donated an album of his original Great War work to the college archives when Wakeley was president: it is these that survive for historical analysis.⁵³

Figure 1 is a deceptively simple example of Maxwell’s work. It shows how to use a Thomas splint, a traction device for treating fractures first described by Hugh Owen Thomas in 1875 but brought into mass usage by his nephew Robert Jones during the First World War. Maxwell drew this at the casualty clearing station at Merville, northern France, but there is nothing here to show the chaos of the mobile hospital. Rather, Maxwell’s careful, gentle pencil draws the viewer’s eye to the crucial elements depicted: the device and the patient’s leg. Unusually for Maxwell, the patient is not identified. The blanket, the stretcher—and indeed the rest of the body—fade into the distance, isolating the injury and its treatment. While the extraneous elements and the shading are sketchy, Maxwell is bold and precise in his outline of the bars, the frame, the straps, and, especially, the leg. The darker lines serve to accentuate the

very center of the piece, from the knee to the toe, from which we can assume a Medical Corps practitioner would discern how to elevate the limb, position the splint, and tie the fabric straps to the frame. Maxwell's combination of shading with bold and lighter strokes emphasizes the tension in the straps and ties, and the softness of the leather-clad ring. His eye for detail, crucial in his anatomical work, is evident in the rivets in the stretcher and straps, the knots, and the shading in the handle. This combination of shading, isolation, and detail was ideal for publication—presumably intentionally—as we can also see in Figure 2, of another iconic First World War treatment, the Carrel-Dakin method for irrigating wounds.

Some of Maxwell's more striking works involve more of the patient. Whereas the leg in the splint is stationary and gives little indication of the experience of the patient, the latter emerges more strongly in Figure 3, which is likely to have been among Maxwell's first works produced during the conflict. G. A. Scott was recovering from the asphyxiating effects of phosgene gas two days previously: he is not in peaceful repose but slumped against the undrawn pillow, mouth ajar. Once again Maxwell's eye for detail emerges when one looks closer. Scott's stubble hints as to the time he has been comatose; Maxwell used subtle color in the original to emphasize the pallor of the patient. Scott's face is isolated but not excised from its context—the shading hints at the pillow, and from there the ward; the outline of his shirt alludes to the rest of his body, but unlike his face it is uncolored, auxiliary to the main purpose of the work.

Surprisingly, Maxwell's mentor and patron George Makins appears in the corner of the work. Like the heroic physicians of the nineteenth century, he is depicted as a benign figure.⁵⁴ He looks down at both the patient and the artist who has assumed a position next to Scott. From Makins's peripheral position on the page we infer that Maxwell had not set out to juxtapose

doctor and patient; but it does serve to remind us that Maxwell was there in the clinical setting, which he has carefully excluded to isolate the condition. “Gassed” he scrawled on the bottom of the work: enough said.

The contrasts with the published version of this work (Figure 4) in the *Surgical History of the War* are revealing of the process of translation from bedside to print.⁵⁵ Maxwell often traced his originals onto tracing paper, which he penciled underneath and outlined onto board. He then painted over the highlights with a glue solution that did not hold the subsequent wash; he finally worked powdered lead over darker areas.⁵⁶ In Scott’s case, however, Maxwell seems to have used pastel, possibly in combination with his usual technique—and perhaps in unknowing homage to Henry Tonks—rendering contrast between light and dark more striking. The hair, eyebrows, and stubble are darker, as are the formerly delicate shadows. So too the color of Scott’s eyelids, nose, and ears as more dramatic, and a greenish tinge to his skin emphasizes the effects of phosgene. Makins has exited stage left, but the other striking details—pillow, shirt, and collar button—remain. In transition from drawing to pastel, the focus and meaning of the image has changed.

Of the album of work that survived, the most striking is Figure 5. This work was originally paired with a sketch of the operation that the patient would endure—a genre we will explore in more detail in the following section. Unlike its clinical counterpart, however, Maxwell blends strong elements of high art in this ostensibly medical illustration. (Perhaps this is why there is no evidence of a published version of this work.) Here almost the whole body of the patient is depicted in isolation. Once again, the viewer’s eye is drawn to the center of the illustration, a small splash of color the evidence of a most likely fatal wound—vivid entry and

exit wounds and a trail of bruising following the path of the bullet between them. (Coloring was an advantage available to the hand-drawn illustrator, of course, but not easily to the photographer.)

The patient lies supine, exposed and vulnerable, his nudity unnecessary for the present purposes but aesthetically striking: only his crooked right leg spares his modesty. His head is leaned back—but not in the throes of agony as one might expect from such a wound. Nor do his limbs or posture reveal any discomfort, his hands resting gently on the sheet and his thigh. He bears neither bandage nor dressing, whether for Maxwell's benefit or in anticipation of his surgery. Beyond the wound, his nudity is emphasized by Maxwell using a similar subtle color scheme to Scott above—fingernails and delicate skin tones at the contours of his body contrasting with the dark shaded background near the wound and the plain sheets that once again frame the flesh of the patient. Knowingly or not, in this work Maxwell harks back to the clinical illustrations by Charles Bell of wounds inflicted in a conflict a century before (Figure 6). There are strong echoes of Tonks's near-contemporary work, in the fleshy youth of the soldier, his fragility, his innocence.⁵⁷ And like Tonks, Maxwell also carries tender religious overtones, resonating with Renaissance lamentations of the Christ. The soldier bears his stigmata in his gut rather than his hand; but he too has been sacrificed.

In these artworks the conflict appears inscribed into the soldier's body, but Maxwell has discretely removed the setting. The paradox is that his proximity is important to render the illustrations credible, but in making them useful and, crucially, translatable, he removes the wartime ward. And so although this work appears to contrast starkly with that of the next artist I

consider, as does their locale, this tactic is also evident. If we look closely, we find her reasons for delineating had strong parallels.

Dulcie Pillers: Art in the Operating Theater

Whereas Maxwell concentrated on the wounded patient in the military ward during the First World War, the second artist to be discussed here demonstrates the role of the illustration in another clinical context: the operating theater. Whether because she was female, or because she was less prolific in publication, we know less about Dulcibel Mary Pillers than we do about Maxwell. She was born in Bristol in 1892 and by the 1911 census she was living in Tyndalls Park and studying art in the city.⁵⁸ Her career involved sufficient medical illustration for her to be one of the founder members of the Medical Artists' Association of Great Britain, although she was not present at the inaugural meeting in Oxford (at which Maxwell was awarded an honorary life membership).⁵⁹ Pillers remained in Bristol and died there in 1961.

Like many invisible technicians, the evidence of her labor is bound up in the work of her collaborator–patron Ernest William Hey Groves, surgeon to the Bristol General Hospital and professor of surgery at Bristol University. Leading up to and during the First World War, Hey Groves, the son of an engineer, applied his mechanical background to orthopedic operations, and he was subsequently regarded as a pioneer in orthopedics as the formal specialism took shape. He was also tireless on paper, publishing multiple editions of surgical textbooks and editing the *British Journal of Surgery* for twenty-seven years from its founding in 1913.⁶⁰

Hey Groves's early works, such as the first edition the *Synopsis of Surgery* (1908), had no pictures;⁶¹ he then began to introduce X-rays and some recycled diagrams and other

illustrations.⁶² It is not clear how they met, but Hey Groves engaged Pillers as an illustrator shortly after the First World War—the first evidence in print is the 1922 edition of *On Modern Methods of Treating Fractures*.⁶³ “Miss Pillers,” he credited her, “has taken great pains to carry out my personal instructions.”⁶⁴ He valued her clean, crisp style, which suited his requirements to represent metal equipment and bone (Figure 7). Unlike Maxwell’s, Pillers’s textbook illustrations were sparse and diagrammatic, more suited to woodcut blocks that enabled cheap, mass-produced publications. They were akin to the often-repurposed diagrams on woodblocks used by instrument manufacturers in this period in their large print run catalogues.⁶⁵

Like Maxwell, however, her most striking work is a cluster of illustrations stemming from First World War injuries: this time in peacetime Britain rather than wartime France. With an influx of devastating compound fractures caused by gunshot wounds, Hey Groves had set about improving the plate-on-bone techniques developed before the war by William Arbuthnot Lane. He experimented with indirect fixation via external pins and grafted animal bone into the fracture; and he had Pillers draw them.

Pillers completed nearly a hundred pen and watercolor operational illustrations of the bone-grafting operations between 1919 and 1922,⁶⁶ most likely from observation within the operating theater. For while there is no direct evidence for precisely where Pillers undertook this work, we know that medical artists Dorothy Davison and Margaret McLarty drew in theater in the interwar period.⁶⁷ All three were founders of the Medical Artists’ Association; like Maxwell, McLarty illustrated Hamilton Bailey’s *Surgery of Modern Warfare*.⁶⁸ She later wrote, “In the operating theatre it is much to the advantage of an artist that he can watch and draw an operation. . . . I have always received the utmost consideration in this respect in numerous

operating theatres . . . the drawings made while watching an actual operation will be much more ‘alive’ than those adapted from books.”⁶⁹

This hectic environment was known to be a challenge for artists. After witnessing his first operation, Daryl Lindsay, Tonks’s protégé at Sidcup, had despaired: “How was I going to translate what looked like a mess of flesh and blood into a diagram that a student could understand?”⁷⁰ And yet this was precisely the value of the hand-drawn over the confusing black-and-white mess of the operational photograph. Like Davison, Pillers likely sketched rapidly with pencil in theater then redrew, finishing or at least tidying the images afterward with Hey Groves’s input. “It is wise to make as many notes as possible in the theatre,” advised McLarty, “both drawings and written observations. [The artist] should try to have enough material on paper from which to make several detailed drawings.”⁷¹ From the detail, then, it seems very likely Pillers watched from the surgeon’s elbow. Artist worked side by side with clinician in the inner surgical sanctum.

Photography was yet of use for bodily interior, unable to pick out pertinent details for the surgeon.⁷² Figures 8 and 9, by contrast, show the qualities of Pillers’s work that made delineation so valuable. The operations on Private Humphries’s forearm in June 1919 and Lance Corporal Whiting’s upper arm a year later are highly sanitized, especially in their lack of blood. Like her nineteenth-century predecessors, was her “desire to repress the blood’s signifying power” removing Hey Groves’s practice from butchery?⁷³ Certainly its absence makes clearer the core of the main element at the upper part of Figure 8, showing the pink fibrous periosteum wrapping the grafted bone, which in both images is colored a pale ivory. A slight dotted square to the right of the graft site indicates the unseen insert of the new bone, an established practice in medical art

to render the invisible visible. In Whiting's case these interior outlines are larger, extending to either end of the humerus in black and the inserted graft in dark red.

But in the operation itself, the surgeon had no such luxury: he needed to see. So in Figure 8, two of Humphries's extensor muscles are drawn out of the way above the graft. Their position being important to the operation mechanism; they are colored an especially vivid red, textured to show their sinewy structure (in her black-and-white diagrams of similar operations, she used fine lines to achieve the equivalent effect).⁷⁴ So too the small detailed radial vessel, the clamping of which is also crucial. The rest of the open wound is rendered in a discrete, undistracting pink. The interior of Whiting's limb is darker, but still a simple flat wash that draws attention to the details at the center. The grafted bone seems to float in isolation within a hollow limb, the better to focus the eye on the procedure.

Whereas Whiting's damaged flesh at the edge of his wound is visible, Pillers did not color the finger extensors that frame Humphries's wound at all. They blend in with the fabric that disguises the surrounding skin then fades off into the distance—just as Maxwell's blankets did. Clips tuck them back, subtle watercolor reflections attesting to their metallic material; as do the disembodied clamps and retractors radiate from the center, especially in Figure 8, hinting at the tension in peeling back the edges of the flesh. The instruments fade out as they point toward invisible hands, a common feature of operation illustrations that harked back to medical waxworks with disembodied practitioners' hands floating around the body of the patient. Between the instruments at other points of the compass are five dotted pointers reaching out to abbreviated identifications of the anatomical features in her clear small-capped hand. Many of

Pillers's operative works are annotated in this way, redolent of the "halo" of labels first introduced by Gray and Vandyke Carter.

On the same page, Pillers deploys subsidiary illustrations to provide the backstory of the main event, rendering Figure 8 a clockwise sequence over time. Two pairs of details show how the grafts were inserted into the patients' bones. With devastating simplicity, in pure black and white at the top of Figure 9, Pillers demonstrated the terrible jagged bone that resulted from the original injury. Parenthetically, Hey Groves's habit of sawing off the overgrown bone, the results of which can be seen at the bottom, actually hindered grafting. Below Humphries's operation, meanwhile, Pillers includes his X-ray, just as Davison did in some of her drawings of neurological operations in the following decade; Pillers's images were later stored alongside the relevant X-rays.⁷⁵ Even with the expansion in use during the war, radiology was still a young diagnostic technique, its result by no means obvious to interpret.⁷⁶ Pillers has chosen redraw the X-ray relevant to explain it, with a simple color scheme.

Only one published version of this series of orthopedic operations has yet been identified.⁷⁷ If not for reproduction in Hey Groves's articles and textbooks, what then was their purpose? Many of those that survive are backed onto colored paper or card that served as mounts, hinting at their use in lectures and/or teaching in the 1920s. Certainly, they were later used as an exhibition for heritage purposes in Bristol in the 1970s and again in 1989, for conferences such as that of the British Orthopaedic Association. But their original purpose seems to have been for record and training. We don't know what Pillers intended, but McLarty later recalled having been "rather horrified when entering an operating theatre to find a series of her pictures, drawn some years before, arranged in front of the surgeon on three trolleys." She

modestly added, “One of the guest surgeons mentioned afterwards that he had studied these drawings most carefully before he operated on his first case of this type.”⁷⁸

R. W. Matthews: Art in the Medical Museum

The final site for consideration is the medical museum, which remained a key space for medicine in the twentieth century.⁷⁹ In her exploration of “anatomical intermediality,” Elizabeth Hallam has shown that in the medical museum, material practices were closely bound with the visual and textual.⁸⁰ Curators collected and displayed images and texts alongside specimens and models. We can see this in the work of early twentieth-century medical artists: Kirkpatrick Maxwell, for example, was sent by the MRC to draw specimens from the Army Medical War Collection as well as the living patient.⁸¹ The draftsman presented here to illustrate the role of the artist in the medical collection, however, is R. W. Matthews. A close study of his work in the Royal College of Surgeons of Edinburgh museum completes the trilogy of delineators by (slightly) expanding the geographical and chronological focus of this study, bringing the story back to Scotland and from the 1910s and 1920s into the 1930s.

At around the same time that Maxwell trained in Glasgow, Robert Wilson Matthews, born in Edinburgh 1880, studied lithography and design at the Edinburgh College of Art and the Royal Scottish Academy Life School. Working mainly as a freelance illustrator in the interwar period, he undertook medical commissions from the early 1920s. He became a favored draftsman for the University of Edinburgh anatomists, illustrating orangutan dissections and *Cunningham’s Textbook of Anatomy* for Professor J. C. Brash, as well as *Regional Anatomy* for lecturer E. B. Jamieson; Matthews also undertook work in anesthetics, obstetrics, pathology, physiology, and

surgery.⁸² His work was described by a fellow medical artist as “pleasing and anatomically accurate.”⁸³ He is perhaps best known for his work with Aberdeen anatomist Robert Lockhart from the 1940s on the innovative *Anatomy of the Human Body*, finally published in 1959.⁸⁴ Many illustrations were from embalmed and dissected cadavers and from specimens in the Aberdeen Anatomy Museum. By this time, Matthews was on the staff of the Edinburgh publisher E&S Livingstone, which he had joined in 1946. Like Pillers, Matthews also made drawings from life for surgeons, and was a founder member of the Medical Artists’ Association in 1949.

It is his work with surgeon David Middleton Greig at the Royal College of Surgeons of Edinburgh that will concern us here. While practicing in Dundee, Greig became an authority on bone pathology, building an extensive collection of pathological osteology and plaster casts of orthopedic deformity.⁸⁵ Upon retirement in 1921, he took up the post of conservator (curator) at the Royal College and brought his collection with him. He continued his pathological research on the collection, and it was to work on this that he first engaged Matthews around 1921.

Matthews’s subjects in the Royal College included living patients, an extensive pediatric series, as well as drawings of specimens (comparable to Dorothy Davison’s depictions of specimens for the surgeon Sir Geoffrey Jefferson in Manchester).⁸⁶ Matthews worked in ink, pencil, and watercolor, collaborating with Greig until the surgeon’s death in 1936.

From their partnership, I will focus here on representations of one patient—first depicted in Figure 10. She lived with bone disorders of her skull, hands, feet, and knees—and especially, her spine.⁸⁷ She was a patient of Greig’s, but it is not possible to determine the location of this drawing. With no visible indication of any discomfort, her deformities are masked by the fabric around her shoulders and neck; the angle of the portrait—for it is a portrait—discreetly

disguising her oxycephaly (prolonged skull). She meets the viewers' eye, unlike the patients in Maxwell's works described above. Having long outlived her life expectancy, in this tender work the patient gazes at Matthews from rheumy eyes with a gentle sadness—or is it resignation? For she must have been aware Greig and Matthews were waiting patiently; when she died, in her sixties, Greig secured her skeleton for the museum.

Figures 11 and 12 are different views of her spine, posterior and anterior: Figure 11 showing ossification of the ligaments from disuses and Figure 12 demonstrating dextroconcave lumbar scoliosis with vertebral osteosis.⁸⁸ Drawing at life size, Matthews used pencil in different hardnesses, and a white pencil for the subtle highlights—for example at the tip of the rib in the center of Figure 11—and a delicate penumbra around the edge of the image in Figure 12. Matthews thereby renders striking texture and depth, more than is visible looking at the specimen itself under normal light; the contrasts heightened, the hooks and lines of skeletal articulation absent, the bone forever a pure white that the specimen never was. In Figure 11 her over-ossified and agonizingly curved spine tumbles down out of the picture toward the viewer, leading the eye toward the worst afflicted area at the lower left (the bottom of her spine). In contrast to her portrait, there is little humanity here. Matthews has rendered the skeleton a landscape.⁸⁹ It has rocky ridges and peaks, and an awful gap visible in the anterior view (Figure 12) between the first and second lumbar vertebra is redolent of a ravine—a painful chasm.

Such geological comparisons are matters of interpretation: what is undeniable is that Matthews has isolated the spine on the page, radically decontextualizing the specimen from the patient. Like Lucy Lyons's delineations, they “appear to ‘float’ as there is no pictorial surface for it to rest upon.”⁹⁰ The specimen was already isolated and fragmented, especially in the removal

of the ribs—unusual for scoliosis specimens, and redolent of the visual butchered transactions of the thighs of the pregnant patient depicted by Jan van Rymdyk in William Hunter’s *Gravid Uterus*.⁹¹ And like van Rymdyk, Matthews isolates the spine even more in the image than the decontextualization of the specimen, extracting the specimen even from its display case or storage rack (see Figure 13). Unlike Maxwell or Pillers, Matthews clearly demarcates the edge of the field of vision. Only his autograph intrudes in the viewers’ visual exposure to scoliosis: no other text, no museum showcase, no drifting fabric, no label. Although no contemporary photographs of the spine survive, even recent photography like Figure 13 demonstrates the striking difference between Matthews’s hand and the camera’s lens.

The isolation worked well in Greig’s publications relating to the condition. Greig secured funding from the Carnegie Trust for the Universities of Scotland to illustrate his bone pathology work (the same fund that allowed the Glasgow zoologist Edward Bles to contract the young Kirkpatrick Maxwell), and we can assume he used this to pay the freelance Matthews.⁹² In their series of articles in the *Edinburgh Medical Journal*, reproductions of Matthews’s images therefore joined the research record in this area. “The object of the present communication,” as Greig wrote in one of his Matthews-illustrated articles, “is to give in some detail, *along with adequate illustrations*, the anatomical topography of the bones.” And although on the same page Greig discussed the “advent of efficient radiography” as a visual diagnostic tool, Greig still turned to pencil delineations.⁹³ Matthews augmented Greig’s reputation, just as Maxwell’s and Pillers’s work did their surgical patrons.

Among other delineations of this patient’s spine Matthews prepared is one of marked difference in style, and arguably far better suited for publication—a clear ink lateral view of the

entire spine (Figure 14). The original shows the penciled measurement lines typical of publication preparation, which are not evident in the published version; in Greig's article it appears as an engraving within the page of text rather than a separate photomechanical plate as Figures 11 and 12 were.⁹⁴ Matthews's pencil drawings, meanwhile, remained in the museum collection of the Royal College of Surgeons of Edinburgh. Tellingly, they are catalogued with the museum specimens, not by the archive, and they were assigned a subreference number of the spine. Also tellingly, photographs of the specimen in the record postdate the drawings and are of different angles, so Matthews could not have used them. Rather, they served a distinct function in the medical museum: specimen, images, and case history combine to offer an intermedial record of bone disease.

The Place of Pathological Delineation

The three medical artists discussed above, in different spaces over three decades, all give us clues as to why drawing endured in an increasingly crowded visual domain. In closing I will reflect on their relationships and users to understand *who* medical art was for; I will consider their sites of practice to understand *where* it was undertaken; and finally discuss the relationship of their work with photography—*why* did they draw, when other media were readily available?

The professional fates and identities of Maxwell, Pillers, and Matthews were closely tied with medical practitioners, who clearly valued anatomical, pathological, and surgical art. Just as historians of anatomical illustration have detailed the intense relationship between anatomist and artist, it is clear that these artists' careers and reputation rose and fell with medical patronage.⁹⁵ By the grace of the surgeon, then, the medical artist became part of the team.⁹⁶

Margaret

McLarty noted that in operative drawing, “the smooth efficiency which surrounds the patient is the result of a team of experts working together, and [the artist] becomes part of the team.”⁹⁷

Makins, Hey Groves, and Greig (and many others during their careers) caused these artworks to be made and kept. But it was a mutually constitutive relationship. The artwork then became the surgeons’ property, which they used to shore up their own careers, displaying them in lectures, publishing in research papers and textbooks, and/or retaining them for instruction and clinical record. Some of the artworks discussed here may never have been used or consulted; but they are interesting because of the value placed in their production. Insofar as we know anything about the consumption of these images, it was by fellow practitioners and researchers, and (especially) students.

These audiences used the originals and their reproductions in specific spaces. Seldom have historians considered the *places* for medical art, yet such attention has revealed how prevalent these crafts were across the sites for twentieth-century medicine. Here we have spent most of our time in the operating theater, ward, and museum, but it is clear that the dissection room, lecture theater, and laboratory were sites for drawing too.⁹⁸ In all these sites, the artists’ products were imbued with authority by the proximity of the delineator to the object/subject of study. Even the angle of the artist and viewer—either straight on or slightly elevated as a physician would be at the bedside—emphasized immediacy. Like the (nonmedical) war art of the First World War, its authenticity was closely linked with the artist *having been there*. In making placeless art, place was nonetheless important in establishing credibility.

These conclusions may be drawn of other illustrative media, other utility graphics, and other genres. There were other media available in (most of) these spaces. The question remains,

then, *why draw*? These skills endured, I have argued, because of the advantages of delineation. The works examined here demonstrate the importance of clarity, of selection of details, and, ironically given the value placed upon location, of decontextualization. Delineation isolated particular elements for the viewer's benefit, whether bone grafts or a Thomas splint; delineation emphasized with color, line, or space. As McLarty advised, "The main highlights should be on, or around, the centre of interest. The eye should never be led away from the focal point to glistening fat or instruments, which probably play an unimportant part in the drawing."⁹⁹ Diachronic developments could be juxtaposed, as in Pillers's details of certain elements at different times in the surgery. They are exercises in visual restraint, with limited or no background and quiet details: medical illustration removed the noise. The blankness around the graphic makes it more visible, and sometimes more shocking, drawing attention to that which surgeon and artist considered significant. We can infer from these stylistic elements their practical and pedagogic functions.

To further understand the value of these deceptively simple graphics I will close by contrasting their utility with the medium that has acted as "the other" throughout—photography. What were the benefits of drawing against this backdrop of "mechanical objectivity" generally, and the increase in clinical photography specifically?¹⁰⁰ The camera could indiscriminately capture the entire field of vision in an instant; this could be too much detail, especially for operative images.¹⁰¹ Whether in the interior or on the surface, the pencil could pick out and pinpoint the important elements, indicate depth of field, and draw attention to detail—a subtle thick line and texture rendering the image intelligible. Artists could even provide intimacy and psychological depth like their war artist contemporaries.¹⁰² "A photograph is able to show a

subject,” argues Lyons, “but cannot claim to present knowledge and visual understanding of an encounter in the same way as the action of drawing it can.”¹⁰³ The photograph offered information, the drawing offered meaning. A drawing, Brödel argued, “shows more than a photograph can ever do”; the camera “does not analyze, interpret or treat.”¹⁰⁴ A generation after Brödel, McLarty would continue to hold that “the selective eye of the artist is unlikely to be replaced by the camera in illustrating surgery.”¹⁰⁵ Institutional medical illustration would thrive after the Second World War even as color photography became more practicable; and nonphotographic modes of illustration are commissioned to this day.

Clinical photography nevertheless became integral to medical recording and training in this period. There is no conundrum here, no outright competition between technologies, but rather a mutual compensation. Photography has influenced and interrelated with (other forms of) art from its genesis; what the geographical element of this study has shown is the differences in the way these media related to each other across sites. In the hospital ward, for example, portraits of the living patient were available, and drawing and photograph were used side by side, or even combined. Here I have concentrated on isolated delineations, but many others were hybrid, mixed with photographs and other media. The graphics from the other sites were influenced by or compensated photography. We can be confident the camera was on their minds.

Drawing and photography were only two of a range of media available to the clinician in the early twentieth century. To pull our focus out from this binary opposition is to see them alongside specimens, X-rays, motion pictures, diagrams, wallcharts, stereoscopes, microscopy, and more. They coexisted in complementary ways as part of anatomical intermediality.¹⁰⁶ In the museum, for example, this medical bricolage comprised drawings of the dead patient alongside

specimens and models. So too this dense visual field overlapped and intersected with the written

word, especially in Maxwell's and Pillers's work (in Matthews's case, the labels and object record were separate but juxtaposed). But these were not *mere* illustrations, subsidiary to the text; image and word invoked different meanings. The delineation endured because it sat alongside other media in these sites, providing a unique view of the damaged body.

SAMUEL J. M. M. ALBERTI is Keeper of Science and Technology at National Museums Scotland and Honorary Professor at the University of Stirling Centre for Environment, Heritage and Policy. Previously he was Director of Museums and Archives at the Royal College of Surgeons of England. His books include *Morbid Curiosities: Medical Museums in Nineteenth-Century Britain* (2011).

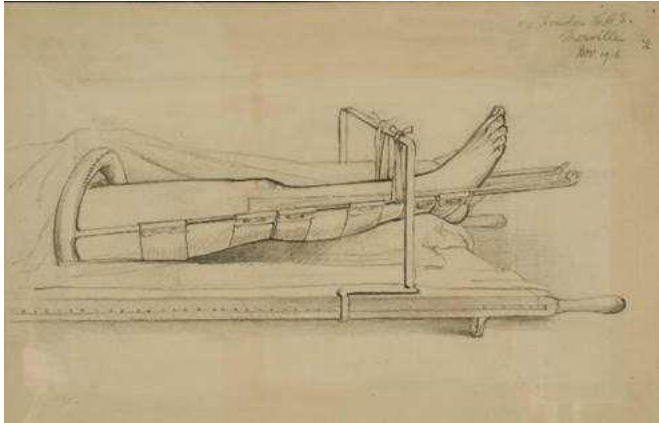


Figure 1. A. Kirkpatrick Maxwell, “*A Thomas Splint in Use at the Casualty Clearing Station at Merville, Northern France,*” 1916. Pencil on paper, 19 × 27 cm. MS0023/1, Archives of the Royal College of Surgeons of England.

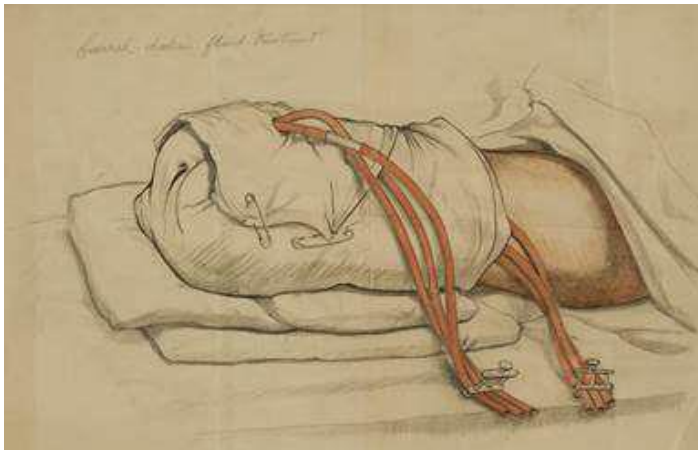


Figure 2. A. Kirkpatrick Maxwell, “*Carrel-Dakin Fluid Treatment,*” 1916. Pencil on paper, 19 × 23 cm. MS0023/1, Archives of the Royal College of Surgeons of England.

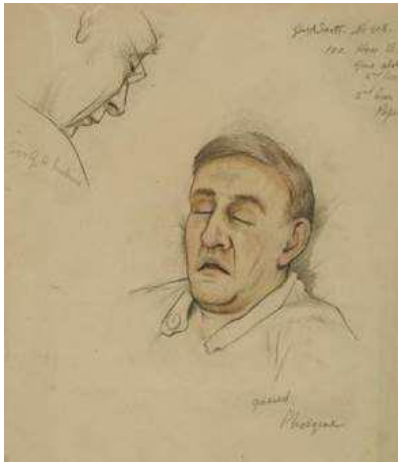

Figure 3. A. Kirkpatrick Maxwell, “George A. Scott,” 1916. Pencil and watercolor on paper, 12 × 16 cm. MS0023/1, Archives of Royal College of Surgeons of England.



Figure 4. A. Kirkpatrick Maxwell, “The Face of a Soldier Suffering from the Effects of Phosgene Gas Poisoning.” In William G. Macpherson et al., eds., *History of the Great War Based on*

Official Documents. Medical Services, 13 vols. (London: HMSO, 1921–25), vol. 2, pl. IV.

Wellcome Collection. CC BY.

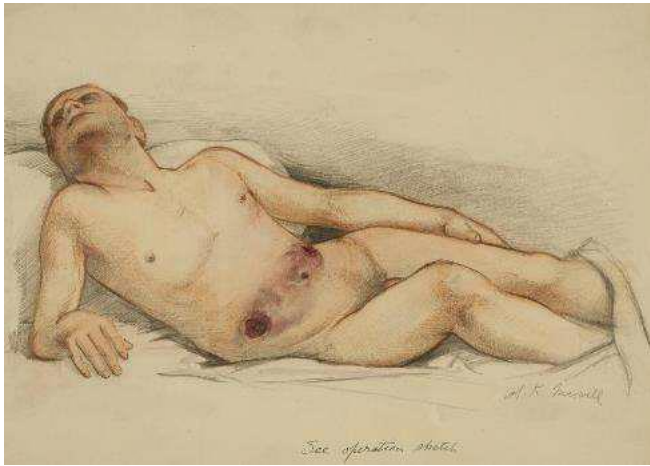


Figure 5. A. Kirkpatrick Maxwell, “*Gunshot Wound to the Abdomen*,” 1916. Pencil and watercolor on paper, 21 × 28 cm. MS0023/1, Archives of the Royal College of Surgeons of England.

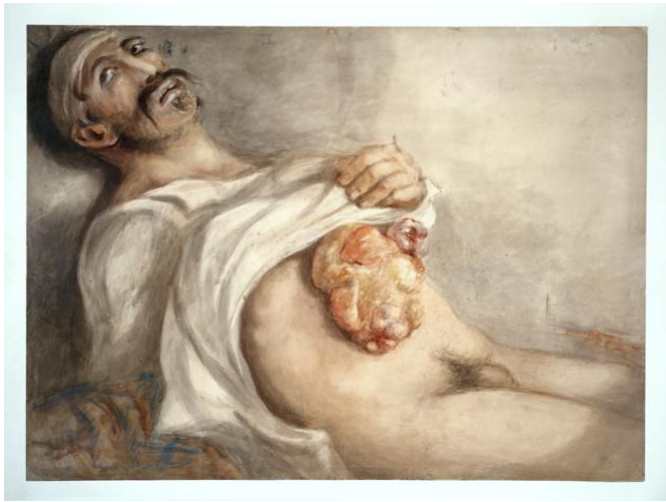

Figure 6. Charles Bell, “*Sabre Wound to Abdomen, Peltier, Belgian Hospital, 2 July. Wounded at the Battle of Waterloo,*” 1836. Watercolor on paper. RAMC/95/1/9, Wellcome Collection L0028898. CC BY.

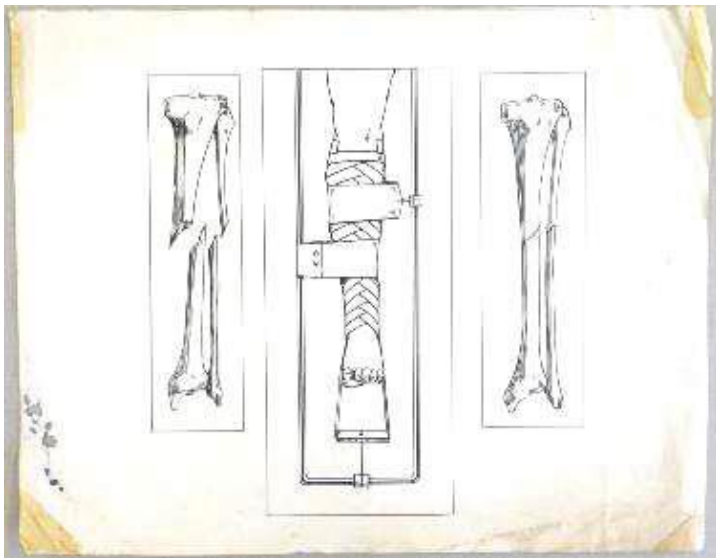


Figure 7. Dulcibel Pillers, “*Combination of Lateral and Axial Pulls,*” ca. 1924. Ink on paper, 14 × 12 cm. MS0529/5/4, Archives of the Royal College of Surgeons of England.

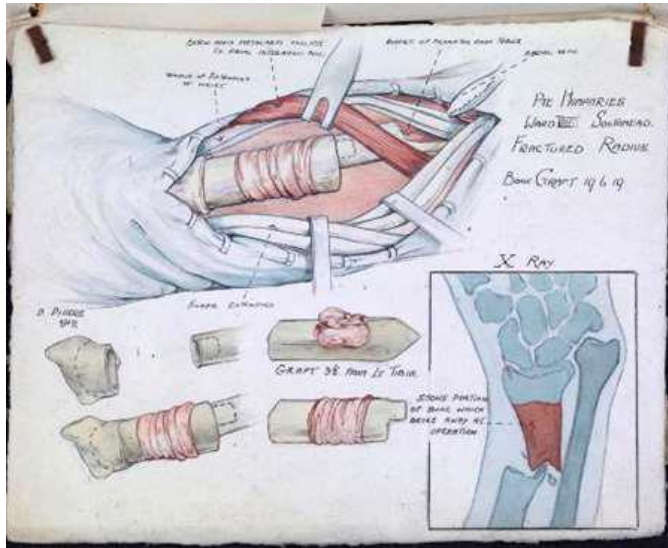


Figure 8. Dulcibel Pillers, “*Pte Humphries*,” 1919. Ink and wash on paper, 23 × 36 cm.

MS0529/2/22, Archives of the Royal College of Surgeons of England.

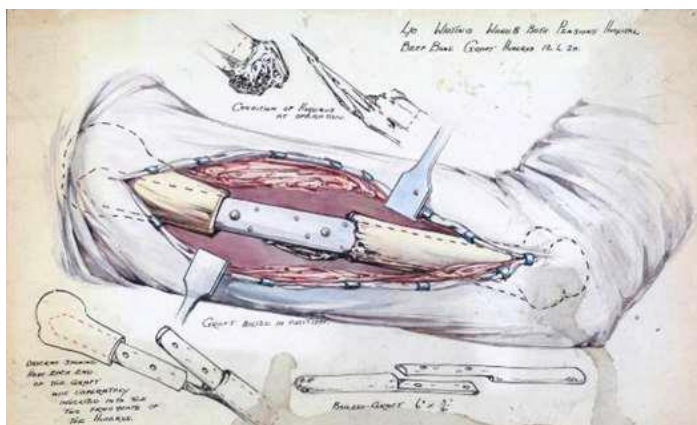


Figure 9. Dulcibel Pillers, “*L/C Whiting*,” 1920. Ink and wash on paper, 20 × 36 cm.

MS0529/2/24, Archives of the Royal College of Surgeons of England.

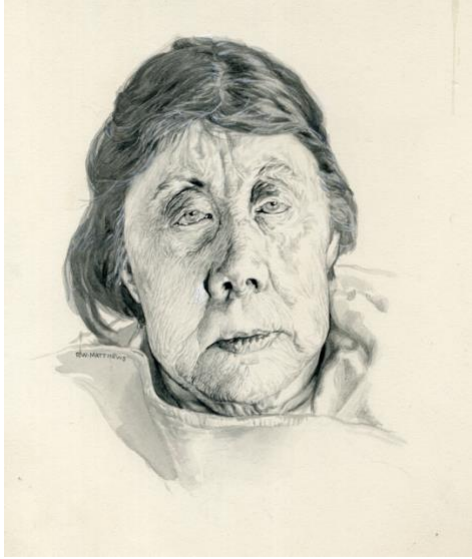

Figure 10. R. W. Matthews, "*Oxycephaly*," 1935. Pencil and wash on paper, 18 × 15 cm.

GC.9644-3, Royal College of Surgeons of Edinburgh Museum.

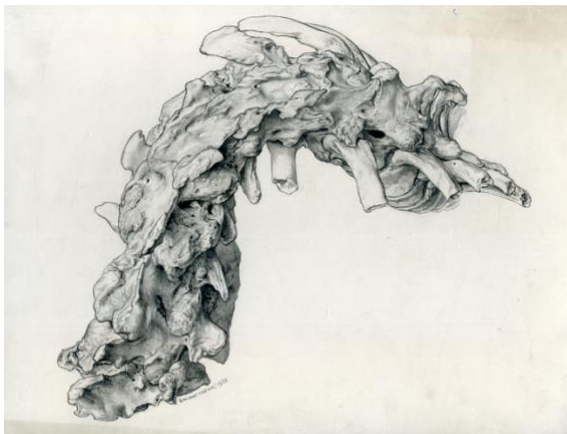


Figure 11. R. W. Matthews, "*Posterior Aspect of the Bones of the Spine from the 8th Thoracic to the 5th Lumbar Vertebra Showing Scoliosis and Osteosis*," 1933. Pencil on paper, 49 × 28 cm.

GC.9644-2, Royal College of Surgeons of Edinburgh Museum.

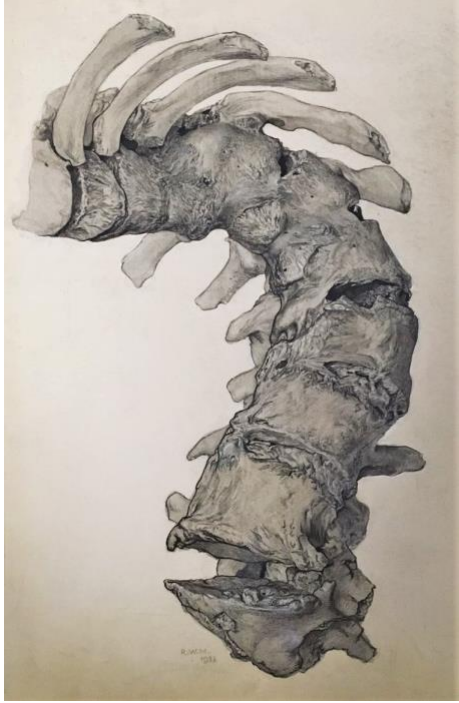

Figure 12. R. W. Matthews, “*Anterior Aspect of the Spine from the 8th Thoracic to the 5th Lumbar Vertebra,*” 1933. Pencil on paper, 49 × 28 cm. GC.9644-1a, Royal College of Surgeons of Edinburgh Museum.

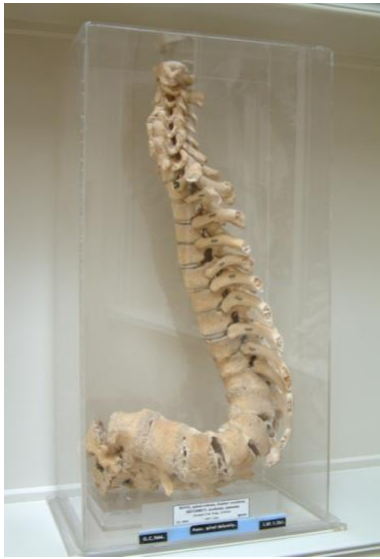

Figure 13. Photograph of GC.9644, 2008, Royal College of Surgeons of Edinburgh Museum.

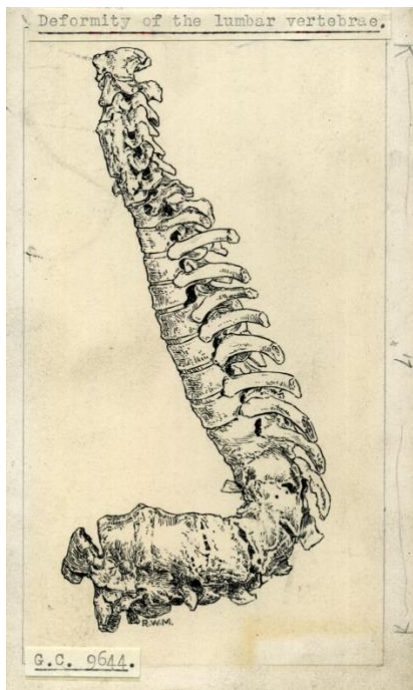


Figure 14. R. W. Matthews, "Spine," 1933. Ink on paper, 19 × 13 cm. GC.9644, Royal College of Surgeons of Edinburgh Museum.

Research was undertaken while the author was Director of Museums and Archives at the Royal College of Surgeons of England and James M. Graham Visiting Professor, University of Edinburgh Clinical Surgery. My thanks to Peter Alberti, Rohan Almond, Stephanie Amiel, Gordon Bannister, Carin Berkowitz, Keren Hammerschlag, Chris Henry, Kristin Hussey, Ed Juler, Louise King, Louise Wilkie, and three referees.

¹ On Tonks, see Samuel J.M.M. Alberti, ed., *War, Art and Surgery: The Work of Henry Tonks and Julia Midgley* (London: Royal College of Surgeons, 2014); Andrew Bamji, *Faces from the Front: Harold Gillies, the Queen's Hospital, Sidcup, and the Origins of Modern Plastic Surgery* (Solihull: Helion, 2017); Suzannah Biernoff, "Flesh Poems: Henry Tonks and the Art of Surgery," *Vis. Cult. Brit.* 11, no. 1 (2010): 25–47; Suzannah Biernoff, "The Rhetoric of Disfigurement in First World War Britain," *Soc. Hist. Med.* 24, no. 1 (2011): 666–85; Suzannah Biernoff, *Portraits of Violence: War and the Aesthetics of Disfigurement* (Ann Arbor: University of Michigan Press, 2017); Emma Chambers, "Fragmented Identities: Reading Subjectivity in Henry Tonks' Surgical Portraits," *Art Hist.* 32, no. 3 (2009): 578–607; Marjorie Gehrhardt, *The Men with Broken Faces: Gueules Cassées of the First World War* (Bern: Peter Lang, 2015). On the medical history of the war more generally, see Mark Harrison, *The Medical War: British Military Medicine in the First World War* (Oxford: Oxford University Press, 2010).

² Klaus Hentschel, *Visual Cultures in Science and Technology: A Comparative History* (Oxford: Oxford University Press, 2014), 229; Samuel J.M.M. Alberti, "The 'Regiment of Skeletons': A

First World War Medical Collection,” *Soc. Hist. Med.* 28, no. 1 (2015): 108–33; Elizabeth Hallam, *Anatomy Museum: Death and the Body Displayed* (London: Reaktion, 2016).

³ On the large proportion of female medical artists from the 1940s—seventeen of the twenty-five founder members of the Medical Artists’ Association of Great Britain were women—see Patricia M. A. Archer, “A History of the Medical Artists’ Association of Great Britain 1949–1997” (Ph.D. diss., University College London, 1998); for established work on gender and the medical gaze, see, for example, Lisa Cartwright, *Screening the Body: Tracing Medicine’s Visual Culture* (Minneapolis: University of Minnesota Press, 1995); Roberta McGrath, *Seeing Her Sex: Medical Archives and the Female Body* (Manchester: Manchester University Press, 2002).

⁴ James Elkins, “Art History and Images That Are Not Art,” *Art Bull.* 77, no. 4 (1995): 553–71, quotation on 553–54; Hentschel, *Visual Cultures* (n. 2).

⁵ Lucy Lyons, “Delineating Disease: A System for Investigating *Fibrodysplasia Ossificans Progressiva*” (Ph.D. diss., Sheffield Hallam University, 2009).

⁶ For an eloquent example of pathological illustration in an earlier period, see Domenico Bertoloni Meli, “The Rise of Pathological Illustrations: Baillie, Bleuland, and Their Collections,” *Bull. Hist. Med.* 89, no. 2 (2015): 209–42; for a recent study of the visual culture of medicine in the early twentieth century, see Michael Sappol, *Body Modern: Fritz Kahn, Scientific Illustration, and the Homuncular Subject* (Minneapolis: University of Minnesota Press, 2017).

⁷ For remarks on this neglect of “working images” in anatomy, see, for example, Kim Sawchuk, “Animating the Anatomical Specimen: Regional Dissection and the Incorporation of Photography in J.C.B. Grant’s *An Atlas of Anatomy*,” *Body Soc.* 18, no. 1 (2012): 120–50.

⁸ Carin Berkowitz, “Introduction: Beyond Illustrations: Doing Anatomy with Images and Objects,” *Bull. Hist. Med.* 89, no. 2 (2015): 165–70; See also Biernoff, “Flesh Poems” (n. 1); Horst Bredekamp, Vera Dünkel, and Birgit Schneider, eds., *The Technical Image: A History of Styles in Scientific Imagery* (Chicago: University of Chicago Press, 2015).

⁹ On regionality, spaces, and circulation of science, see David N. Livingstone, *Putting Science in Its Place: Geographies of Scientific Knowledge* (Chicago: University of Chicago Press, 2010); the historical geography of medicine is not as established, but see, for example, Chris Philo and John V. Pickstone, “Unpromising Configurations: Towards Local Historical Geographies of Psychiatry,” *Health and Place* 15, no. 3 (2009): 649–56; Christopher Lawrence and Michael Brown, “Quintessentially Modern Heroes: Surgeons, Explorers, and Empire, c.1840–1914,” *J. Soc. Hist.* 50, no. 1 (2016): 148–78. For an analysis of the geography of medical illustration in another sense—region rather than venue—see Nancy Stepan, *Picturing Tropical Nature* (Ithaca, N.Y.: Cornell University Press, 2001).

¹⁰ Alberti, *War, Art and Surgery* (n. 1). For a juxtaposition of official (rather than medical) war art with photography in this period, see Sue Malvern, *Modern Art, Britain and the Great War: Witnessing, Testimony and Remembrance* (New Haven, Conn.: Yale University Press, 2004).

¹¹ See, for example, Kenneth B. Roberts and J. D. W. Tomlinson, *The Fabric of the Body: European Traditions of Anatomical Illustration* (Oxford: Clarendon, 1992); Martin Kemp and Marina Wallace, *Spectacular Bodies: The Art and Science of the Human Body from Leonardo to Now* (Berkeley: University of California Press, 2000); Michael Sappol, *Dream Anatomy* (Bethesda, Md.: National Library of Medicine, 2006).

¹² William Hunter, *Anatomia uteri humani gravidi tabulis illustrata* (Birmingham: John Baskerville, 1774).

¹³ Janis McLarren Caldwell, “The Strange Death of the Animated Cadaver: Changing Conventions in Nineteenth-Century British Anatomical Illustration,” *Lit. Med.* 25, no. 2 (2006): 325–57.

¹⁴ Douglas Hugh James, “Portraits of John Hunter’s Patients,” *Med. Human.* 39 (2013): 11–19.

¹⁵ John Bell, *Engravings, Explaining the Anatomy of the Bones, Muscles and Joints* (Edinburgh: John Paterson, 1794); Carin Berkowitz, *Charles Bell and the Anatomy of Reform* (Chicago: University of Chicago Press, 2015); Sappol, *Dream Anatomy* (n. 11).

¹⁶ Cited in Lyons, “Delineating Disease” (n. 5), 10, emphasis added. See Robert Carswell, *Pathological Anatomy. Illustrations of the Elementary Forms of Disease* (London: Longman, 1838); Samuel J.M.M. Alberti, *Morbid Curiosities: Medical Museums in Nineteenth-Century Britain* (Oxford: Oxford University Press, 2011); Russell C. Maulitz, *Morbid Appearances: The Anatomy of Pathology in the Early Nineteenth Century* (Cambridge: Cambridge University Press, 1987).

¹⁷ Kemp and Wallace, *Spectacular Bodies* (n. 11), 32; Ruth Richardson, *The Making of Mr Gray's Anatomy: Bodies, Books, Fortunes, Fame* (Oxford: Oxford University Press, 2008).

¹⁸ Roberts and Tomlinson, *Fabric of the Body* (n. 11), 585; Sawchuk, "Animating the Anatomical Specimen" (n. 7).

¹⁹ Caldwell, "Strange Death" (n. 13), 343.

²⁰ Martin Kemp, "Style and Non-style in Anatomical Illustration: From Renaissance Humanism to Henry Gray," *J. Anat.* 216 (2010): 192–208, quotation on 192.

²¹ Medical photography has its own body of scholarship: classic Anglophone texts include Daniel Michael Fox and Christopher Lawrence, *Photographing Medicine: Images and Power in Britain and America since 1840* (New York: Greenwood, 1988); Bettyann Holtzmann Kevles, *Naked to the Bone: Medical Imaging in the Twentieth Century* (New Brunswick, N.J.: Rutgers University Press, 1997). On realism and photography, see, for example, the standard Linda Nochlin, *Realism* (London: Penguin, 1971).

²² Martin Kemp, "'A Perfect and Faithful Record': Mind and Body in Medical Photography before 1900," in *Beauty of Another Order: Photography in Science*, ed. Ann Thomas (New Haven, Conn.: Yale University Press, 1997), 120–49, quotations on 120 and 123.

²³ Jason Bate, "At the Cusp of Medical Research: Facial Reconstructive Surgery and the Role of Photography in Exchanging Methods and Ideas (1914–1920)," *Vis. Cult. Brit.* 17, no. 1 (2016): 75–98; Hallam, *Anatomy Museum* (n. 2); Beth Linker, "Shooting Disabled Soldiers: Medicine and Photography in World War I America," *J. Hist. Med.* 66, no. 3 (2011): 313–46.

²⁴ For a helpful discussion of the teaching resources available to anatomists at this time, see Salim Al-Gailani, “The ‘Ice Age’ of Anatomy and Obstetrics: Hand and Eye in the Promotion of Frozen Sections around 1900,” *Bull. Hist. Med.* 90, no. 4 (2016): 611–42.

²⁵ David Waterston and D. J. Cunningham, eds., *The Edinburgh Stereoscopic Atlas of Anatomy*, 5 boxes (Edinburgh: T. C. & E. C. Jack, 1905–6).

²⁶ Cartwright, *Screening the Body* (n. 3); Linker, “Shooting Disabled Soldiers” (n. 23).

²⁷ For contrasting angles on the history of X-rays, see Cartwright, *Screening the Body* (n. 3); Vera Dünkel, “X-Ray Vision and Shadow Image: On the Specificity of Early Radiographs and Their Interpretations around 1900,” in Bredekamp, Dünkel, and Schneider, *Technical Image* (n. 8), 116–25; Kevles, *Naked to the Bone* (n. 21).

²⁸ Archer, “History of the Medical Artists’ Association” (n. 3); Reuben D. Johnson and Willow J. Sainsbury, “Audrey Juliet Arnott (1901–1974): The Legacy of an Artist in Neurosurgery,” *J. Vis. Commun. Med.* 32, nos. 3–4 (2009): 88–90; Reuben D. Johnson and Willow J. Sainsbury, “The ‘Combined Eye’ of Surgeon and Artist: Evaluation of the Artists Who Illustrated for Cushing, Dandy and Cairns,” *J. Clin. Neurosci.* 19, no. 1 (2012): 34–38; Peter D. Mohr, “Dorothy Davison (1890–1984): Manchester Medical Artist and Her Work for Neurosurgeon Sir Geoffrey Jefferson (1886–1961),” *J. Med. Biog.* 25, no. 2 (2017): 130–37.

²⁹ Ranice W. Crosby and John Cody, *Max Brödel: The Man Who Put Art into Medicine* (New York: Springer-Verlag, 1991); Francine Mary Netter, *Medicine’s Michelangelo: The Life and Art of Frank H. Netter, MD* (Hamden, Conn.: Quinnipiac University Press, 2013).

³⁰ Bate, “At the Cusp of Medical Research” (n. 23); Carin Berkowitz, “The Beauty of Anatomy: Visual Displays and Surgical Education in Early-Nineteenth-Century London,” *Bull. Hist. Med.* 85, no. 2 (2011): 248–78.

³¹ Hallam, *Anatomy Museum* (n. 2); Kemp, ““Perfect and Faithful Record”” (n. 22); Sappol, *Body Modern* (n. 6); Sawchuk, “Animating the Anatomical Specimen” (n. 7).

³² Christopher Hoolihan, “Wood Engraving and the Illustration of American Surgical Texts during the Nineteenth Century,” *Can. Bull. Med. Hist.* 15 (1998): 351–78; Claire L. Jones, *The Medical Trade Catalogue in Britain, 1870–1914* (London: Pickering & Chatto, 2013).

³³ Daniel John Cunningham, *Cunningham’s Textbook of Anatomy*, ed. Arthur Robinson, 5th ed. (London: Frowde, 1922); Henry Gray, *Anatomy, Descriptive and Applied*, ed. Thomas Baillie Johnston with James Whillis, 27th ed. (London: Longmans, Green, 1938).

³⁴ Kemp, “Style and Non-style” (n. 20), 206.

³⁵ Alberti, ““Regiment of Skeletons”” (n. 2); Archer, “History of the Medical Artists’ Association” (n. 3); R. M. Bell and Archibald Edmund Clark-Kennedy, “A. Kirkpatrick Maxwell: An Illustrated Appreciation,” *Med. Biol. Illus.* 23, no. 1 (1973): 17–22; Soraya De Chadarevian, *Designs for Life: Molecular Biology after World War II* (Cambridge: Cambridge University Press, 2002); Patrick Elliott, “Notable Names in Medical Illustration. A. Kirkpatrick Maxwell,” *J. Audiovisual Media Med.* 22, no. 1 (1999): 130–31.

³⁶ Edward J. Bles, “The Life-History of *Xenopus laevis*, Daud,” *Trans. Roy. Soc. Edinburgh* 41, no. 3 (1905): 789–821.

³⁷ Gray, *Anatomy* (1938) (n. 33); Hamilton Bailey, ed., *Surgery of Modern Warfare*, 3 vols. (Edinburgh: E. & S. Livingstone, 1940–41); Jones Quain, *Quain's Elements of Anatomy*, ed. Edward Albert Sharpey-Schäfer, Johnson Symington, and Thomas Hastie Bryce, 11th ed., vol. 1, *Embryology* (London: Longmans, Green, 1908); William James Hamilton, James Dixon Boyd, and Harland W. Mossman, *Human Embryology (Prenatal Development of Form and Function)*, 3rd ed. (Cambridge: Heffer, 1962).

³⁸ Ian M. Burdon and Sarah Macdonald, eds., *Anatomical Atlas for Nurses and Students* (London: Faber and Faber, 1938).

³⁹ On distinguishing between region and site, between space and place, in the historical geography of science, see Livingstone, *Putting Science in Its Place* (n. 9).

⁴⁰ William G. Macpherson et al., eds., *History of the Great War Based on Official Documents. Medical Services*, 13 vols. (London: HMSO, 1921–31).

⁴¹ U.S. Army Surgeon General's Office, *The Medical and Surgical History of the War of the Rebellion*, 6 vols. (Washington, D.C.: Government Printing Office, 1870–88).

⁴² Alberti, ““Regiment of Skeletons”” (n. 2).

⁴³ National Health Insurance, *Fourth Annual Report of the Medical Research Committee 1917–1918* (London: HMSO, 1918); Landsborough Thomson, *Half a Century of Medical Research*, 2 vols. (London: HMSO, 1973–75).

⁴⁴ National Health Insurance, *Second Annual Report of the Medical Research Committee 1914–1915* (London: Causton, 1915), 33; Samuel J.M.M. Alberti, “Surgery 1913: The Genesis of the *British Journal of Surgery*,” *Brit. J. Surg.* 100 (2013): S6/4-9.

⁴⁵ Linker, “Shooting Disabled Soldiers” (n. 23); James R. Wright Jr. and Leland B. Baskin, “Pathology and Laboratory Medicine Support for the American Expeditionary Forces by the US Army Medical Corps during World War I,” *Arch. Path. Lab. Med.* 139, no. 9 (2015): 1161–72.

⁴⁶ Bate, “At the Cusp of Medical Research” (n. 23).

⁴⁷ Henry Gray, *Anatomy, Descriptive and Applied*, ed. Robert Howden, 18th ed. (London: Longmans, Green, 1913).

⁴⁸ Bell and Clark-Kennedy, “A. Kirkpatrick Maxwell” (n. 35), 19.

⁴⁹ Arthur Keith, *A Guide to the Exhibition of the Army Medical Collection of War Specimens, Opened October 11th, 1917* (London: Taylor & Francis, 1917) quotations on 5, 18.

⁵⁰ Malvern, *Modern Art, Britain and the Great War* (n. 10).

⁵¹ George H. Makins, “On the Vascular Lesions Produced by Gunshot Injuries and Their Results,” *Brit. J. Surg.* 3, no. 11 (1915): 353–421; Army Medical Services, *Memorandum on the Treatment of Injuries in War: Based on Experience of the Present Campaign, July 1915* (London: HMSO, 1915); Army Medical Services, *Injuries and Diseases of War: A Manual Based on Experience of the Present Campaign in France, January 1918* (London: HMSO, 1918); *British Journal of Surgery* Correspondence Concerning Illustrations Made for Medical

Research Committee, 1915–21, Medical Research Committee and Medical Research Council Files, FD 1/1955, the National Archives, Kew, UK.

⁵² Cf. Mohr, “Dorothy Davison” (n. 28).

⁵³ A. Kirkpatrick Maxwell, notebook, 1914–18, MS0023, Royal College of Surgeons of England Archives, London (hereafter R.C.S. Eng. Archives). One further watercolor was donated in 1960: see James Patterson Ross—Sir John McNee, March 25, 1960, R.C.S. Eng. Archives.

⁵⁴ Bridget L. Goodbody, “‘The Present Opprobrium of Surgery’: *The Agnew Clinic* and Nineteenth-Century Representations of Cancerous Female Breasts,” *American Art* 8, no. 1 (1994): 32–51; Mary Hunter, *The Face of Medicine: Visualising Medical Masculinities in Late Nineteenth-Century Paris* (Manchester: Manchester University Press, 2015); Lawrence and Brown, “Quintessentially Modern Heroes” (n. 9).

⁵⁵ Macpherson et al., *History of the Great War* (n. 40), vol. 2, pl. IV.

⁵⁶ Margaret C. McLarty, *Illustrating Medicine and Surgery* (Edinburgh: Livingstone, 1960), 81.

⁵⁷ Especially *Saline Infusion* (1915), as considered in Biernoff, “Flesh Poems” (n. 1).

⁵⁸ Louise King, “Treasures from the Collections: Illustrations of Orthopaedic Operations,” *Bull. Roy. Coll. Surg. England* 98, no. 4 (2016): 178.

⁵⁹ Among those who did attend were David Tompsett of the Royal College of Surgeons of England and Dorothy Davidson of Manchester. Archer, “History of the Medical Artists’ Association” (n. 3).

⁶⁰ Alberti, “Surgery 1913” (n. 44).

- ⁶¹ Ernest W. Hey Groves, *A Synopsis of Surgery* (Bristol: Wright 1908).
- ⁶² Ernest W. Hey Groves, *On Modern Methods of Treating Fractures* (Bristol: Wright, 1916); Ernest W. Hey Groves, *Surgical Operations: A Textbook for Students and Nurses*, 2nd ed. (Oxford: Oxford University Press, 1925).
- ⁶³ Ernest W. Hey Groves, *On Modern Methods of Treating Fractures*, 2nd ed. (Bristol: John Wright, 1922).
- ⁶⁴ Ernest W. Hey Groves, *A Synopsis of Surgery*, 7th ed. (Bristol: Wright 1925), iii.
- ⁶⁵ Jones, *Medical Trade Catalogue* (n. 32).
- ⁶⁶ Dulcibel Pillers and Ernest W. Hey Groves, Papers of Pillers and Hey Groves, 1918–33, MS0529, R.C.S. Eng. Archives.
- ⁶⁷ Archer, “History of the Medical Artists’ Association” (n. 3); Mohr, “Dorothy Davison” (n. 28).
- ⁶⁸ Hamilton Bailey, ed., *Surgery of Modern Warfare*, 3rd ed., 6 vols. (Edinburgh: E. & S. Livingstone, 1944).
- ⁶⁹ McLarty, *Illustrating Medicine* (n. 56), 86.
- ⁷⁰ Daryl Lindsay, “The Sir Richard Stawell Oration; Five Men,” *Med. J. Aust.* 45, no. 3 (1958): 61–65, quotation on 62, cited in Biernoff, “Flesh Poems” (n. 1), 32.
- ⁷¹ McLarty, *Illustrating Medicine* (n. 56), 86.
- ⁷² Kemp, ““Perfect and Faithful Record”” (n. 22).
- ⁷³ Goodbody, ““Present Opprobrium of Surgery”” (n. 54), 43–44.

⁷⁴ For example, Dulcibel Pillers, “Pensioner Packer,” 1920, MS0529/2/4, R.C.S. Eng. Archives.

⁷⁵ Mohr, “Dorothy Davison” (n. 28); Dulcibel Pillers and Ernest W. Hey Groves, Papers of Pillers and Hey Groves, 1918–33, MS0529, R.C.S. Eng. Archives.

⁷⁶ Barron H. Lerner, “The Perils of ‘X-ray Vision’: How Radiographic Images Have Historically Influenced Perception,” *Perspect. Biol. Med.* 35, no. 3 (1992): 382–97; Dünkel, “X-Ray Vision” (n. 27).

⁷⁷ Groves, *On Modern Methods of Treating Fractures*, 2nd ed. (n. 63), 263.

⁷⁸ McLarty, *Illustrating Medicine* (n. 56), 97. On the use of photography in meetings and teaching in this period, see Bate, “At the Cusp of Medical Research” (n. 23).

⁷⁹ Samuel J.M.M. Alberti and Elizabeth Hallam, eds., *Medical Museums: Past, Present, Future* (London: Royal College of Surgeons of England, 2013).

⁸⁰ Hallam, *Anatomy Museum* (n. 2).

⁸¹ Alberti, “‘Regiment of Skeletons’” (n. 2); see, for example, George H. Makins, “Specimens Showing the Effects of Gunshot Injury on the Heart and Blood-Vessels: Now on Exhibition in the Museum of the Royal College of Surgeons of England,” *Brit. J. Surg.* 8, no. 29 (1920): 107–32, fig. 67.

⁸² Daniel John Cunningham, *Cunningham’s Text-Book of Anatomy*, ed. E. B. Jamieson and J. C. Brash, 7th ed. (Oxford: Oxford University Press, 1937); E. B. Jamieson, *Illustrations of Regional Anatomy*, 6th ed., 7 vols. (Edinburgh: E. & S. Livingstone, 1946).

⁸³ Clifford Shepley to Dorothy Davison, ca. October 20, 1948, cited in Archer, “History of the Medical Artists’ Association” (n. 3), 104.

⁸⁴ R. D. Lockhart, G. F. Hamilton, and F. W. Fyfe, *Anatomy of the Human Body* (London: Faber and Faber, 1959); Hallam, *Anatomy Museum* (n. 2).

⁸⁵ David Middleton Greig, *Clinical Observations on the Surgical Pathology of Bone* (Edinburgh: Oliver and Boyd, 1931); Violet Tansey and D.E.C. Mekie, *The Museum of the Royal College of Surgeons of Edinburgh* (Edinburgh: Royal College of Surgeons of Edinburgh, 1982); Dawn Kemp with Sara Barnes, *Surgeon’s Hall: A Museum Anthology* (Edinburgh: Royal College of Surgeons of Edinburgh, 2009); Iain M. C. Macintyre, *Chamber of Curiosities: A Short History and Guide to Surgeons’ Hall Museums* (Edinburgh: Someone, 2015).

⁸⁶ Mohr, “Dorothy Davison” (n. 28). For a striking watercolor of a diseased spine, see R. W. Matthews, “Congenital Scoliosis with Posterior Rachishisis,” ca. 1930, GC.5387-2, Royal College of Surgeons of Edinburgh Museums; for an example of pencil drawings of bone, see David M. Greig, “Intertarsal Developmental Anklyosis,” *Edinburgh Med. J.* 42, no. 1 (1935): 21–37.

⁸⁷ David M. Greig, “Acrodysplasia. Type: Syndactylic Oxycephaly,” *Edinburgh Med. J.* 42, no. 11 (1935): 537–60.

⁸⁸ David M. Greig, “Scoliotic Vertebral Osteosis,” *Edinburgh Med. J.* 42, no. 4 (1935): 205–20.

⁸⁹ See also the illustrations of her skull in Greig, “Acrodysplasia” (n. 87). For another comparison of landscape and anatomical illustration, see Lawrence and Brown, “Quintessentially Modern Heroes” (n. 9).

⁹⁰ Lyons, “Delineating Disease” (n. 5), 262.

⁹¹ Hunter, *Anatomia uteri humani gravidi* (n. 12); Ludimilla Jordanova, *Sexual Visions: Images of Gender in Science and Medicine between the Eighteenth and Twentieth Centuries* (Hemel Hempstead: Harvester Wheatsheaf, 1989).

⁹² Bles, “Life-History” (n. 36); Greig, “Intertarsal Developmental Anklyosis” (n. 86); Greig, “Scoliotic Vertebral Osteosis” (n. 88).

⁹³ Greig, “Intertarsal Developmental Anklyosis” (n. 86), 21, emphasis added.

⁹⁴ Greig, “Scoliotic Vertebral Osteosis” (n. 88), 214.

⁹⁵ See, for example, Nick Hopwood, “Artist versus Anatomist, Models against Dissection: Paul Zeiller of Munich and the Revolution of 1848,” *Med. Hist. Suppl.* 51, no. 3 (2007): 279–308; Richardson, *Making of Mr Gray’s Anatomy* (n. 17).

⁹⁶ Johnson and Sainsbury, ““Combined Eye”” (n. 28).

⁹⁷ McLarty, *Illustrating Medicine* (n. 56), 102.

⁹⁸ See, among many examples, “Erwin F. Faber with John Heisler, M.D., Sketching Dissection, c. 1908,” photograph 86H05MQA, Sturgis/Faber Box 1 #21, College of Physicians of Philadelphia Digital Library, <http://www.cppdigitallibrary.org/items/show/4365>.

⁹⁹ McLarty, *Illustrating Medicine* (n. 56), 69; Johnson and Sainsbury, ““Combined Eye”” (n. 28).

¹⁰⁰ Lorraine Daston and Peter Galison, *Objectivity* (New York: Zone, 2007).

¹⁰¹ James Whillis, “Anatomical Illustration,” *Med. Biol. Illus.* 1 (1951): 66–73.

¹⁰² Biernoff, “Flesh Poems” (n. 1); Kemp, ““Perfect and Faithful Record”” (n. 22); Malvern, *Modern Art, Britain and the Great War* (n. 10).

¹⁰³ Lyons, “Delineating Disease” (n. 5), 23.

¹⁰⁴ Sawchuk, “Animating the Anatomical Specimen” (n. 7), 142; Max Brödel, “Testimonial Dinner to Howard Atwood Kelly on His Seventy-Fifth Birthday,” *Bull. Johns Hopkins Hosp.* 53, no. 2 (1933): 65–109.

¹⁰⁵ McLarty, *Illustrating Medicine* (n. 56), 96.

¹⁰⁶ The phrase is Hallam’s, as fully explored in her *Anatomy Museum* (n. 2); see also Alberti, *Morbid Curiosities* (n. 16); Al-Gailani, “‘Ice Age’ of Anatomy” (n. 24); and on bricolage in textbooks, see Sawchuk, “Animating the Anatomical Specimen” (n. 7).