

Thesis  
1387

**Studies on the Inflammatory Response of the  
Striped Snakehead *Channa striatus* (Fowler)**

by

**Supranee Chinabut**

**A Dissertation submitted to the University of  
Stirling for the Degree of Doctor of Philosophy**

**Institute of Aquaculture,  
University of Stirling**

**June, 1989.**



### Declaration

I declare that this thesis represents results of research conducted by me at the National Inland Fisheries Institute, Thailand and the Institute of Aquaculture, University of Stirling, during the period 1986-1989. The literature consulted has been cited, and where appropriate, collaborative help has been acknowledged.

This work has not been submitted for any other degree.

Candidate:

S. Chinabut.

Supervisor:

Date:

Acknowledgements

I would like to acknowledge the International Development Research Centre (IDRC) for providing me a grant to work on the research described in this thesis and the Department of Fisheries, Thailand for allowing my absence from routine work during my studies at the Institute of Aquaculture, University of Stirling, Scotland.

I gratefully acknowledge Prof. R.J. Roberts for his supervision, reading the draft manuscript for the thesis, his support and all of the help and the hospitality he gave to me throughout the study period and before. Special thanks are also due to Dr. Kamonporn Tonguthai, head of the Fish Health Unit, National Inland Fisheries Institute (NIFI), for her encouragement, various suggestions and support.

I also wish to express my sincere thank to Dr. A.M. Bullock, at the Scottish Marine Biological Association (SMBA) for his help on preparation the wounded skin sections of the experimental fish and all his advice on the histological and photographic techniques, which were useful to my research work. Thanks are due also to Mr. R.B. Stewart, Chief Technician, Audiovisual Aids Unit, University of Stirling, who helped with the photographic preparation. Thanks are also merited to all of the technical staff at the Institute of Aquaculture, for their help and kindly cooperation.

(11)

Thank is due to Dr. Kok Leong Wee, at the Asian Institute of Technology (AIT), Bangkok, for the information and publications on the biology of the snakehead fish that he provided.

Mention is also due to, Mr. Pornlerd Chanratchakool, the biologist and all the technicians in the histopathological laboratory, NIFI, for looking after the experimental fish, preparing holding facilities and histological work preparation.

My deepest gratitude is also due to my parents, my husband, Dr. Narong and Patsuda my daughter, who give me their love and understanding.



Abstract

Experiments were carried out to define the cellular response of snakehead fish, *Channa striatus* (Fowler), to integumental ulceration; chronic granulomatosis associated with the standard irritant Freund's adjuvant; bacterial septic abscessation due to *Aeromonas hydrophila*, and focal exposure to the aquatic phycomycete *Achlya debaryana*. Following exposure, the pathogenesis of the resultant lesion was followed by means of histopathological examination of sequentially sampled specimens.

In the case of integumental ulceration, small artificially induced wounds had re-epithelialized within the remarkably short space of 2-3 hours after incision. Large numbers of macrophages were found throughout the degenerated muscle area at 4-5 hours but had completely disappeared from the area of defect by day 6-12. Small numbers of polymorphonuclear leucocytes were observed only at the very earliest stage after wounding. The wounded site was restored to normal condition by around 21-28 days.

Chronic granulomata were invoked by injection with Freund's complete adjuvant. Macrophage infiltration was particularly active in the early stages after the inoculation and started to decrease by day 21. It started to take on an epithelioid configuration within 24 hours of its development. Fibrosis and vascularization

(iv)

were seen at about the same time, around day 4. The regeneration of myofibres had strongly developed by day 6 and the new muscle bundles had replaced the area of fibrosis almost completely by the 28<sup>th</sup> day. The granulomata lesions were still extant, albeit in a very modified, and highly fibrosed form, by the end of the experiment (11 weeks).

The acute inflammatory response was demonstrated in the snakehead by injection with the bacterium, *Aeromonas hydrophila*. An ulcerative wound developed by day 2 after the inoculation. PMN showed a marked response to the bacterial infection and had infiltrated into the inflammatory area by the second hour after the injection. Bacterial colonies, found in the inflammatory area, were very closely related to these PMN clusters. Fibrosis started to encapsulate the necrotic area around 30-36 hours post injection. The lesion began to heal by day 7 to 10 and the healing process was completed around day 28.

A very mild inflammatory response occurred in the snakehead injected with the fungus, *Achlya debaryana*. Some infiltrated PMN and lymphocytes migrated into the inoculated site at the early stages of the experiment, but macrophage activity dominated in the necrotic muscle area. Fibrosis, new capillaries, and regenerated muscle fibres were found by day 3-4 and the lesion was completely healed around day 6.

## Table of Contents

	page
Acknowledgements	(i)
Abstract	(iii)
Table of Contents	(v)
List of Tables	(x)
List of Figures	(xi)
Chapter 1: General Introduction	
i: The Biology of the Striped Snakehead	
Introduction	1
Taxonomy	3
Anatomy and Physiology	3
Distribution	6
Feeding and Behaviour	7
Breeding Biology	8
Culture	10
ii: Snakehead Ulcerative Disease	11
iii: Aims of the Present Study	13
Chapter 2: Integumental Wound Healing in the Striped Snakehead	
Introduction	14
Review of the Literature	16
Fish Skin	16
Cuticle	17
Epidermis	17
Club Cells	19
Sacciform Granular Cells	20
Mucous Cells	21
Eosinophilic Granular Cells	22
Sensory Organs	22
Basement Membrane	24
Dermis	25
Stratum spongiosum	25
Scales	25
Pigment cells	27

	page
Stratum compactum	28
Hypodermis	29
Snakehead Skin	29
Wound Healing in Fish	33
Relationship Between Temperature and Wound Healing	37
Vitamin C and Wound Healing	40
The Migration of the Epidermis	44
Fibrosis in Fish	45
Muscle Regeneration in Fish	47
Experimental Design	49
i: Pilot Study	50
Materials and Methods	50
Fish	50
Aquaria Holding	50
Wounding Procedure	50
Sampling Procedure	51
Fixation for Histology	51
Staining Procedures	51
Results	52
Discussion	52
ii: Definitive Study	54
Materials and Methods	54
Fish	54
Aquaria Holding	54
Wounding Procedure	54
Sampling Procedure	55
Fixation and Staining Procedures	55
Results	57
Gross Pathology	57
Histopathology	58
Discussion	84

	page
<b>Chapter 3: Chronic Inflammation in the Striped Snakehead</b>	
Introduction	96
Review of the Literature	97
Inflammation	97
The Inflammatory Response in Fish	99
Experimental Inflammation in Fish	100
Cells Involved in the Teleost Inflammatory Response	105
Macrophages	105
Melanin-Containing Cells	108
Neutrophils	109
Lymphocytes	110
Plasma Cells	111
Giant Cells	111
Eosinophilic Granular Cells	113
Epithelioid Cells	115
Fibroblasts	115
The Tuberculous Lesion in Fish	115
Experimental Design	119
Materials and Methods	119
Experimental Fish	119
Aquaria and Water	119
Injection	120
Sampling Procedure for Histology	120
Results	121
Histopathological Changes	121
Discussion	142
<b>Chapter 4: Effect of <i>Aeromonas hydrophila</i> Infection on the Wound Healing and Cellular Inflammatory Response of the Striped Snakehead</b>	
Introduction	148
Review of the Literature	150
Biology of <i>Aeromonas hydrophila</i>	150

	page
Pathogenesis of <i>A. hydrophila</i> Infection	154
Temperature and Bacterial Haemorrhagic Septicaemias	159
Experimental Design	160
Materials and Methods	160
Fish	160
Aquaria Holding	160
Experimental Infection	161
Sampling Procedures	162
Histological Procedures	162
Staining Procedures	162
Results	163
Gross Pathology	163
Pathological Observation	164
Discussion	184
 Chapter 5: Effect of <i>Achlya dabaryana</i> Infection on the Wound Healing and Cellular Inflammatory Response of the Striped Snakehead	
Introduction	189
Review of the Literature	191
General Information on Sprolegniasis	191
Experimental Studies on <i>Saprolegniaceae</i>	192
Temperature and Fungal Infection	195
Fungus Toxicity	196
The biology of <i>Achlya</i>	196
Experimental Design	199
Materials and Methods	200
Fish	200
Aquaria Holding	200
Preparation of inocula	200
Injection	201
Sampling Procedures	201
Fixation and Staining for Histology	201

(ix)

	page
<b>Results</b>	<b>202</b>
<b>Histopathological Observations</b>	<b>202</b>
<b>Discussion</b>	<b>207</b>
<b>Chapter 6: General Discussion</b>	<b>211</b>
<b>References</b>	<b>217</b>

(x)

List of Tables

	page
Table 1: Showing optimum vitamin C requirements of different fishes as determined by various workers.	43
Table 2: Histology of skin repair and cellular inflammatory response to skin wounds in snakehead.	82
Table 3: The complete epithelialization time requirement in different fish species.	85
Table 4: Thickness of the epidermis and the time required for complete epithelialization of wound in different fishes.	86



## List of Figures

	page
Fig. 1. The normal snakehead fish.	2
Fig. 2. Diagram of normal snakehead skin.	30
Fig. 3. Diagram of normal snakehead (a) and diagram showed wounding position on experimental fish.	56
Fig. 4. The picture of wounded skin at 15 minutes after the incision, showed marked haemorrhage (H) and muscle necrosis (MN). (H & E) X 200	61
Fig. 5. The fibrinous exudate (arrow) was formed at the wounded site by 30 minutes after incision. (H & E) X 200	61
Fig. 6. Epidermal cells were migrating (arrow) down into the depth of the wound by 1 hour. (H & E) X 200	63
Fig. 7. By 2 hours after the incision, the epithelialization was completed. (H & E) X 200	63
Fig. 8. The picture of muscle fibre degeneration with some haemorrhage at 2 hours. (H & E) X 800	64
Fig. 9. By 3 hours after wounding, the thickened re-joined epidermis covered the area of the defect. (H & E) X 375	64
Fig. 10. The inflammatory dermis at 3 hours after wounding showed hyperaemia and melanin containing cells (arrow). (H & E) X 800	65
Fig. 11. The degenerated muscle bundles at 3 hours after the incision showed myophagia. (H & E) X 800	65
Fig. 12. Thrombocytes in the exudate at 5 hours after the incision. (H & E) X 800	67
Fig. 13. This picture demonstrates the presence of melanin pigments in the intermyotomal fascia adjoining the affected myotome 7 hours after the incision. (H & E) X 800	67
Fig. 14. By 8 hours after the incision macrophages (MC) containing phagocytosed melanin were migrating through the stratum spongiosum. (H & E) X 800	70
Fig. 15. By 8 hours after the incision focal nodular polymyositis was present. (H & E) X 375.	70
Fig. 16. By 9 hours after the incision an obvious melanin layer was apparent below the basement membrane of the new epidermis. (H & E) X 800	72

- Fig. 17. The newly joined epidermis at 24 hours after wounding showed intra and inter cellular oedema, but the sectioned dermis had not joined yet. (H & E) X 100 72
- Fig. 18. The enlargement of Fig. 17. showed intra and inter cellular oedema of the epidermal cells which covered the sectioned dermis and some exudate. (H & E) X 200 74
- Fig. 19. By day 3 after ulceration the wounded area showed new muscle regeneration (arrow) within the fibrosing replacement tissue. (H & E) X 800 74
- Fig. 20. Macrophages with lipofuscin in the cytoplasm (arrow) found within the area of fibrosis by day 4. (H & E) X 800 76
- Fig. 21. The healing lesion at day 4 demonstrating the active fibrous connective tissue joined the ends of sectioned dermis. (H & E) X 80 77
- Fig. 22. Active fibrosis and vascularization were found in the healing lesion by day 4. (H & E) X 800 77
- Fig. 23. By day 5 after wounding the dermis was almost completely re-joined by fibrous connective tissue. (Van Gieson) X 200 78
- Fig. 24. The scale bud re-formed in the stratum spongiosum around day 5 after the incision. (H & E) X 400 78
- Fig. 25. By day 14 after the incision the dermis was completely joined and new scales were formed. (H & E) X 400 81
- Fig. 26. By day 21 after wounding, new muscle bundles extended throughout the defect. (H & E) X 400 81
- Fig. 27. The injection site with Freund's Complete Adjuvant showed massively swollen muscle cell resulting from attempts of sarcolysis (MN). Note also thickening of cell boundary as a result of myopathy (arrow) and mild haemorrhage at 30 minutes after the injection. (H & E) X 400 122
- Fig. 28. The inflammatory area at 1 hour after the FCA injection showed swollen muscle cell with a mild inflammatory cellular response. (H & E) X 800 122
- Fig. 29. By 1 hour after the FCA injection considerable numbers of inflammatory cells had migrated to the defect area. (H & E) X 800 123

- Fig. 30.** This photograph demonstrates marked myopathy and macrophages (MC) at 2 hours after the inoculation. (H & E) X 800 123
- Fig. 31.** A distinct increase in numbers of macrophages especially around blood vessels was apparent at 12 hours after the FAC injection. (H & E) X 800 125
- Fig. 32.** Bacterial colonies at edges of the lacuna. (ZN) X 800 125
- Fig. 33.** By 24 hours after the FCA injection considerable numbers of macrophages and melanocytes were found around the blood vessels. (H & E) X 800 127
- Fig. 34.** The mycobacterial colonies were clustered at the edges of the lacunae at 2 days after the FCA inoculation. (H & E) X 800 127
- Fig. 35.** Sequestration of adjuvant within a honeycomb of epithelioid cells. (H & E) X 200 128
- Fig. 36.** By day 4 after the FCA injection there was extensive spread of fibroblasts (arrow) throughout the area between the adjuvant lacunae. (H & E) X 200 128
- Fig. 37.** New capillaries were formed in the fibrosis area at 4 days after the FCA injection. (H & E) X 800 129
- Fig. 38.** Freund's complete adjuvant granuloma after 6 days. The significant feature is the giant cell (G) surrounded by the epithelioid cells. (H & E) X 800 129
- Fig. 39.** Granulation and giant cell (arrow) was generalized within the sequestered oil lacunae at day 6 after the FCA injection. (H & E) X 200 130
- Fig. 40.** By 6 days after the FCA inoculation regenerated muscle fibres and new capillaries were prominent features of in the fibrosis area. (H & E) X 800 130
- Fig. 41.** Muscle fibre buds and capillaries were found in the defect area around day 6 of the FCA experiment. (H & E) X 800 132
- Fig. 42.** Melanin pigments (MP) around the granulomata and dead macrophages with lipofuscin in the centre observed by day 7 after the FCA injection. (H & E) X 800 134

	page
Fig. 43. Typical granulomata at the centre of the lesion, with prominent melanin pigment at day 14 after the FCA injection. (H & E) X 200	134
Fig. 44. By day 28 after the FCA inoculation fibroblasts, macrophages and lymphocytes were marked in the central lesion. (H & E) X 800	135
Fig. 45. Distinctive melanization around the FCA granulomata at day 28 after injection. (H & E) X 200	136
Fig. 46. Small foci of caseation with lymphocytes, eosinophilic granular cells and macrophages, found at day 28 after the FCA injection. (H & E) X 800	136
Fig. 47. Melanization around the various sizes of granulomata at day 35 after the FCA injection. (H & E) X 200	138
Fig. 48. By day 42 after the FCA inoculation, eosinophilic granular cells, macrophages and some vacuoles were observed in the caseous necrotic area. (H & E) X 800	138
Fig. 49. Large lacuna with dense epithelioid capsule surrounded by melanin pigments at day 49 after the FCA injection. (H & E) X 800	139
Fig. 50. By 56 days after the FCA injection the macrophage bridges were still developing deviding the lacuna into smaller and smaller size. (H & E) X 800	139
Fig. 51. Dense melanin pigments occurred around the granuloma at 63 days after the FCA injection. (H & E) X 400	141
Fig. 52. Lacuna filled with necrotic sacrificed epithelioid debris and surrounded by dense melanin pigments. (H & E) X 800	141
Fig. 53. Sarcoplasmic degeneration at the injection site with focal haemorrhage at 1 hour after the bacterial injection. (H & E) X 800	166
Fig. 54. By 2 hours after the bacterial injection some lymphocytic infiltration with a few polymorpho-nuclear leucocytes and macrophages had occurred. Bacterial colonies can also be observed. (H & E) X 800	166

	page
<b>Fig. 55. Severe muscle degeneration was marked by 2 hours after the bacterial injection. (H &amp; E) X 800</b>	167
<b>Fig. 56. Both PMN and bacterial colonies were found within mycosarcoplasma and in the inter-myofibrillar space at 3 hours after the injection. (H &amp; E) X 800</b>	167
<b>Fig. 57. By 3 hours after the injection blood vessels were engorged with leukocytes and red blood cells. (H &amp; E) X 800</b>	168
<b>Fig. 58. The junction between normal and necrotic muscle bundles at 4 hours after injection. (H &amp; E) X 400</b>	168
<b>Fig. 59. By 6 hours after the injection some melanin pigments were found around the blood vessel. (H &amp; E) X 800</b>	170
<b>Fig. 60. The clusters of bacterial colonies surrounded by PMN were very obvious in the necrotic area by 8 hours after injection. (H &amp; E) X 800</b>	170
<b>Fig. 61. By 8 hours after injection with <i>Aeromonas</i> degeneration of sarcoplasm with cellular debris was observed. (H &amp; E) X 800</b>	171
<b>Fig. 62. Bacterial colonies spread throughout the myopathic area at 8 hours after the injection. (H &amp; E) X 800</b>	171
<b>Fig. 63. By 10 hours after injection myophagia was observed. (H &amp; E) X 800</b>	172
<b>Fig. 64. The blood vessel showed diapedesis of leukocytes and extensive inflammatory cells around the vessel at 12 hours after aeromonad injection. (H &amp; E) X 800</b>	172
<b>Fig. 65. By 18 hours after the injection more bacterial colonies associated with muscle necrosis and cellular infiltration were observed. (H &amp; E) X 800</b>	174
<b>Fig. 66. By 24 hours after the injection further sarcolysis had occurred. (H &amp; E) X 800</b>	174
<b>Fig. 67. Fibroblasts (arrow) developed to encapsulate the necrosis area by 30 hours after the injection. (H &amp; E) X 400</b>	175

- Fig. 68. Lymphocyte (arrow) accumulation and haemorrhage (H) were found at the edges of the lesion at 30 hours after the injection. (H & E) X 400 175
- Fig. 69. By 36 hours after the injection the myonecrosis had extended further towards the skin. (H & E) X 200 176
- Fig. 70. The epithelioid cells had migrated from the skin at the edge of the lesion into the centre of the ulcer by 36 hours after the injection. (H & E) X 80 176
- Fig. 71-72. The fibroblasts and macrophages forming an investing wall around the focus of the infection area by 36-42 hours after the injection. (H & E) X 200 177
- Fig. 73. The ring of fibroblasts and macrophages separated the necrotic material and normal muscle by 48 hours after the injection. (H & E) X 800 178
- Fig. 74. Fibrous connective tissue (arrow) surrounded the necrotic material at 48 hours after the injection. (H & E) X 400 178
- Fig. 75. Macrophages, containing lipofuscin in the cytoplasm, encapsulated by fibroblasts at day 4 after the injection. This is an example of a follicular granuloma in the process of formation. (H & E) X 800 180
- Fig. 76. Regenerating muscle fibres developing in the fibrosis area by day 4 after the injection. (H & E) X 800 180
- Fig. 77. By day 5 after the injection new capillaries (arrow) were formed in the fibrosis area at the outer layer of the lesion. (H & E) X 400 182
- Fig. 78. Showing the regenerating fibres in the fibrosis area by 6 days after the injection. (H & E) X 800 182
- Fig. 79. Showing focal macrophages with lipofuscin in the cytoplasm, PMN and advancing new muscle fibre regeneration at day 7 after the aeromonad injection. (H & E) X 400 183
- Fig. 80. Damaged myotomes 6 hours after the fungus injection. (H & E) X 800 203
- Fig. 81. Infiltration of PMN, macrophages and lymphocytes in between the necrotic myofibres at 12 hours after injection of fungus. (H & E) X 800 203

	page
Fig. 82. Small number of macrophages observed adjacent to the degenerated muscle bundles at 24 hours after injection. (H & E) X 800	205
Fig. 83. By 48 hours after injection the necrotic myofibrils were increased with dominant active macrophages and some fibroblasts. (H & E) X 800	205
Fig. 84. Myophagic macrophages 2 days after fungal injection. (H & E) X 800	206
Fig. 85. Muscle regeneration development taking place in the lesion 4 days after injection. (H & E) X 800	206
Fig. 86. By 5 days after the injection some macrophage centres with lipofuscin accumulated (arrow) were found in the area of muscle regeneration. (H & E) X 800	208

**CHAPTER 1: GENERAL INTRODUCTION**

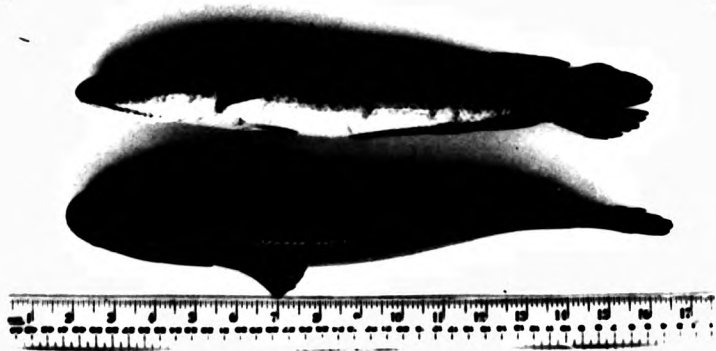


## 1. THE BIOLOGY OF THE STRIPED SNAKEHEAD

## INTRODUCTION

*Channa striatus* (Fowler 1937) was first described by Bloch in 1793 as *Ophicephalus striatus* (Yapchiongco and Demonteverde 1959; Misra 1959). It is an air breathing (labyrinthine) freshwater fish belonging to the family Channidae, Order Channiformes (Greenwood et al., 1966). Striped snakehead and murrel are the common names used for this species. It is a freshwater fish but it is able to live in low salinity brackish water (Tungtongphairoj 1981). *C. striatus* is one of the commonest of the staple food fish in the Asian countries (Raj 1916; Smith 1965). Arumugam (1966) considered the snakehead to be a particularly excellent food fish, since the flesh is very firm, white, free from intermuscular bones and of a most agreeable flavour. The flesh of the snakehead varies to some degree in flavour depending on the water it inhabits, those living in streams and rivers tasting better than those from swamps or ponds, the latter having a muddy flavour ( Arumugam 1966; Deraniyagala 1929; Smith 1965;). Snakehead is usually marketed alive, thus obtaining a better price, but salted dried snakehead is valuable in some Asian countries. The Thai dish *pla chon tom yam* , a delicious lemon fish soup, is produced from farmed stock in Thailand.

**Fig. 1. The normal snakehead fish**



#### TAXONOMY

According to Smith (1965) there are 8 species of snakehead to be found in Thailand. Altogether there are 30 named species of snakehead described in the literature (Wee 1982). *Ophicephalus striatus* Bloch, *Ophiocephalus striatus* Bleeker and *Ophiocephalus vagus* Sauvage are all synonyms for *Channa striatus* (Fowler). The characteristic taxonomic features of *C. striatus* which differentiate it from the other snakeheads are as follows:

- Vomer and palatines with a more or less continuous pluriserial band of small teeth, none of them canine.

- No ocellus at base of caudal fin; a posterior row of about five canine teeth on each ramus of lower jaw; lateral line 52 to 57, dropping abruptly by two rows at the 17<sup>th</sup> and 20<sup>th</sup> perforated scale; scales in transverse line series 4 to 5.5-1/8 to 10 not counting the lateral line; dorsal rays 37 to 45; anal ray 21 to 27; back dark green, dark brown, or black; side usually with dark stripes running obliquely upward above, obliquely downward below; underparts white, irregularly blotched with black or brown.

#### ANATOMY AND PHYSIOLOGY

The Latin nomenclature *Ophicephalus* means snakehead fish (*ophis* = snake, *cephalus* = head). The name of the genus being derived from the striking resemblance of such fish to that of serpents. The scales

on the head are also enlarged and thickened like the capital shields of a snake (Arumugam 1966).

The body of the snakehead is subcylindrical, elongate and compressed posteriorly. The head is depressed with large, lateral eyes. The rounded snout is less than twice the diameter of the eye. The maxillary extends from behind the border of the eye, and the fish has thus a very large gape. The lower jaw is prominent, and the cleft of the mouth is rather oblique. The openings of the opercula are wide, with the membrane of the two sides being connected beneath the isthmus. In the jaw there are 5-6 rows of teeth. These are enlarged, pointed and backward facing, facilitating the grasping of the prey firmly in the mouth on capture. There are 4-5 rows of teeth on the vomer and palatine bones.

Snakeheads have a single, long spineless dorsal fin and a shorter anal fin. The caudal fin is rounded and completely separated from both the dorsal and anal fins. The paired pelvic fin is near to the vent and to the anal fin. They can move or crawl a certain distance over the ground, when it is moist, by using their pectorals and caudal fin. The lateral line has a downward curve, from the head and usually encompasses two perforate scales, at the level of the seventeenth to the twentieth scale.

The colour of all snakeheads varies considerably with the nature of the waters they inhabit and ranges from olive green to dark brown dorsally, and white to yellow abdominally, with a white throat. There

are about 15 transverse irregular dark streaks, or spots or bands on the side of the body, which are wider than the interspace ( Arumugam 1966; Smith 1965; Yapchiongco and Dermontiverde 1959). When excited the colour can change but *C. striatus* cannot do this as completely or rapidly as *O. marulius* ( Deraniyagala 1929; Misra 1959; Raj 1916; Smith 1965; Weber & Beaufort 1922; Yapchiongco and Dermontiverde 1959). Young snakeheads are generally more or less yellow-orange in colour and possess bright reddish orange longitudinal bands extending along the lateral side of the body. These originate from behind the eyes and terminate at the base of the caudal fin.

Above the true gill chamber, there is, on either side, a suprabranchial cavity. This contains an auxiliary or accessory respiratory organ similar to, but not as well developed as, that of the clariid catfishes (Weber and Beaufort 1922). These highly vascularised organs serve as a means for the fishes to breathe from air. Thus they are able to live in semi-fluid mud, in waters having very little dissolved oxygen, or even survive out of water for long periods of time (24 hours) if the skin and breathing organ remain moist (Hora 1935; Munshi 1962, 1976; Saxena 1967). Dehadrai (1962) stated that *C. striatus* could live out of water for more than 28 hours. In the dry season snakeheads can be buried in the soft bottom mud and hibernate until the next rainy season (Arumugam 1966; Hora 1935; Ling 1977; Raj 1916; Smith 1965). It is also interesting to note that along with

this development of the air-breathing habit, there is a reduction in the size of the gills.

It is their habit to move to the upper layer of the water periodically to engulf a small amount of air from the surface (Vivekanandan 1976). Several studies have shown that if specimens in the aquarium are prevented from reaching the surface by some device such as wire mesh placed two inches below the surface of the water, they will generally die within 24 hours, indicating an absolute dependence on air breathing (Aldaba 1931; Yapchiongco and Demonteverde 1959). Vivekanandan (1977) found that surfacing frequency was depth dependent for fish of less than 20 g body weight. Wee (1982) explained that the phenomenon of "hanging" at the surface by snakeheads may be regarded as a condition in which an accumulation of oxygen debt and the resulting fatigue having reached a maximum threshold, the exhausted fish "hang" on to the surface, repaying the oxygen debt and exchanging respiratory gases.

#### DISTRIBUTION

The snakeheads are native to freshwaters throughout Asia, Southeast Asia and Africa. Some species are found in the southern part of China and they have been introduced to Hawaii and the United States of America (Jordan 1907). They are found commonly in rivers, swamps, canals, lakes, ponds, marshes, ricefields, flooded lowland and ditches. The genus is relatively hardy and is adaptable to both lowland and mountain

(Ling 1977; Smith 1985; Yapchiongco and Demonteverde 1959). Its optimum temperature range is 26-30° C (Banerjee 1974; Ling 1977), but it can survive down to temperature as low as 11-14° C. Temperatures below 11° C however are fatal to them (Bhattacharya 1946; Mookerjee et al., 1948).

#### FEEDING AND BEHAVIOUR

*C. striatus* is a carnivorous fish, feeding on aquatic worms, insects, small fishes and other small aquatic animals. It prefers live food and eating the young of its own species is not at all uncommon (Arumugam 1966; Ling 1977). They snap actively at any moving object in the water. In natural waters they prefer to feed at night time (Tungtongphairoj 1981). Migration is a biologically significant behavioural feature of the snakehead life cycle, with a definite spawning run taking place in addition to foraging migrations in the search for food (Yapchiongco and Demonteverde 1959). Cultured snakehead in the ponds can be induced to accept trash fish and pellets, after training for a period of time. Willey (1910) reported the snakehead to be a fish species whose size limit is practically indefinite. Whilst this is probably an exaggeration, certainly the more food it receives of the right kind, the quicker and the larger it grows.

The larvae of *C. striatus* initially take in protozoa, and unicellular and multicellular algae as food, but they rapidly assume their carnivorous mode of life.



Larval rearing of snakeheads is extremely difficult and no proper technology exists to achieve this. Thus snakeheads can only be cultured on the basis of capture of wild fry. The fry are predominantly insectivorous in their feeding habits, consuming principally dipteran larvae, copepods and daphnia or moina. Even in the young fry, the active carnivorous activity exemplified in the adult can readily be noticed (Hookerjee *et al.*, 1948).

#### BREEDING BIOLOGY

Snakeheads are monogamous; the female is much larger than the male (Alikunhi 1957; Yapchiongco and Demonteverde 1959). The time to maturation and the spawning season of *C. striatus* depends critically on the prevailing climatic conditions. Principal precipitating factors in inducing the onset of sexual maturation and spawning are the environmental triggers of water temperature and rainfall (Alikunhi 1953; Parameswaran *et al.*, 1970; Qasim and Qayyum 1961). The snakehead becomes mature in about 12-18 months at a size of 21-30 cm. in length (Aldaba 1931; Arumugam 1966; Ling 1977; Smith 1965; Tungtongphairoj 1981).

Spawning generally takes place in the rainy season. Adult snakeheads go in pairs, mate and build their nest by cutting aquatic vegetation with the mouth to create a clear, but protected nest in shallow water near the edge of the canal or lake. The diameter of the nest is 10-11 inches. The nest is merely a receptacle to receive the eggs and a place for courtship (Wee 1982).

Under favorable conditions, *C. striatus* can breed throughout the year ( Aldaba 1931; Deraniyagala 1929; Parameswaran & Murugesan 1976; Tungtongphairoj 1981; Yapchiongco and Demonteverde 1959;). In some regions however they spawn twice a year from January to October (Ling 1977; Raj 1916; Tungtongphairoj 1981). Both male and female fish protect the eggs and the young, and they do not seem to take any food during the period of guarding. The young are protected, in a nurse school of hundreds of small fry, until they are able to fend for themselves. FAO (1975) and Ling (1977) reported that mature snakehead can be induced to spawn by hypophysation, but Parameswaran and Murugesan (1976) reported that while spawning could indeed be induced by such treatment, in the absence of the behavioural and environmental cues associated with the normal courtship and spawning process the parents did not demonstrate parental care of eggs or brood after hypophysation.

The eggs, which are large, about 1.25-1.50 mm. in diameter, are transparent, golden-yellow or amber in colour and are positively buoyant in the nest (Arumugam 1966; Raj 1916; Smith 1965 ). They contain a single large oil globule exterior to the golden-yellow yolk. The number of ova produced varies with the size of the female, but fecundity is around 4,000-5000 (Parameswaran & Murugesan 1976). The hatching time of the eggs varies from 21 hours to 3 days after fertilization. They do not all hatch at the same time, and the hatching rate is generally dependent upon the ambient temperature ( Aldaba

1931; Arunugam 1966; Deraniyagala 1929; Mookerjee et al., 1948; Parameswaran & Murugesan 1976; Smith 1965; Yapchiongco & Demonteverde 1959). The fry and fingerling of *C. striatus* school together until they reach a length of 5-6 cm. and then they separate. Throughout South East Asia, they are collected from natural water in large numbers for culture during the rainy season.

#### CULTURE

*C. striatus* is the species most commonly cultured. It may be farmed in ponds or in cages. Its culture began mainly in the Mekong Basin (Pantulu 1976), and it became popular in Thailand in the 1960s and spread to the neighboring countries early in the 1970s (Ling 1977). *C. striatus* is the fastest growing of the snakehead family and is less cannibalistic in tendency than the others (Alikunhi 1957). In ponds it can attain 25-27 cm. in less than 14 months and yield of 258 kg. per acre can be achieved in 6 months (FAO 1972). The maximum growth rate that has been reported was growth to 40 cm. in length and 620 g. in weight in eight and a half months (Murugesan 1978).

Pandian (1980) and Wee (1982) recommended culturing *C. striatus* in shallow waters at habitat temperatures of 27-32° C. A feeding rate of 25.5 percent b.w./day was shown by Wee (1982) to provide the optimum conversion efficiency, at least for the small 0.9g fish, which he studied. The optimum density for growth and conversion for *C. striatus*, under his conditions, was 1g of biomass per litre of water (Wee 1982).

## ii: SNAKEHEAD ULCERATIVE DISEASE

As is indicated above, the striped snakehead is a fish species of considerable economic importance, in Thailand and in other countries of the Southeast Asian Region, both for culture and because it provides a major component of the freshwater fishery associated with rice field culture.

During the period 1982-1989 a serious epizootic ulcerative disease spread throughout the Southeast Asian region, (Tonguthai 1985) involving several ricefield species but principally snakehead.

The lesions observed clinically on the snakeheads and the other rice field fishes were essentially similar, except that in snakeheads many more severe cases, with chronic lesions, were seen than in the other species. This suggests the probability that the snakehead, a notoriously tough fish, was surviving longer and thus was able to show more severe lesions than other species which had succumbed before this stage was reached.

According to Roberts et al., (1986) the gross lesion were described as flat circumscribed, haemorrhagic ulcers, although often in early stages they were simply areas of acute dermatitis forming rosacea. In more advanced lesions the features were often those of severe bacterial ulceration with necrosis of underlying muscle fibres. The overall impression of affected fish, other than those of the earliest stages, was of a marked

bacterial involvement, and extension from ulcerated skin to muscle, and in late stages, to some viscera.

This disease is currently (1989) still active and spreading beyond Thailand, into Burma, Laos and other neighbouring countries and has now extended to Sri Lanka and Bangladesh. Recent work has shown that a rhabdovirus, of previously undescribed type, can on occasion be isolated from the tissues of such fish but that the principal cause of death is the involvement of secondary invaders (Frerichs *et al.*, 1986; Roberts *et al.*, 1986).

### iii: AIMS OF THE PRESENT STUDY

During efforts to trace the cause, and the epizootiology, of the devastating condition known as Epizootic Ulcerative Syndrome (EUS), it became obvious that there was little or no basic histopathological knowledge on the cellular defences and inflammatory and wound healing capability of this important family of tropical fishes.

The present study was instigated in order to try to define, at least for one species of striped snakehead, the basic cellular responses, in healthy fish, to a series of standard physical and chemical insults involving tissue inflammation and repair, and to relate these to the cellular responses to the types of secondary pathogen found in the epizootic condition.

**CHAPTER 2: INTEGUMENTAL WOUND HEALING**  
**IN THE STRIPED SNAKEHEAD**

## INTRODUCTION

The integument, and its accessory structures, serves many purposes in fishes. The most obvious, of course, is its physical function as the investing membrane of the body, but another principle role is protection against pathogenic agents and mechanical damage (Fletcher 1978; Ingram 1980; Jakowska 1963; Roberts 1975b). Thermal adjustment to the environment, and osmoregulation, are made in part through the skin, especially in the embryo and it may also serve as a respiratory organ, and as a receptor of stimuli (Cameron & Endean 1973; Jakowska 1963; Rosen & Coenford 1971; Van Oosten 1957).

The protective capacity against pathogens, provided by the skin, is again partly physical. The scales and fibrous tissue of the dermis prevent penetration or limit the subsequent spread of, for example, parasitic copepods, or helminth larvae. It also provides, however, a wide range of other mechanisms which limit, inhibit or destroy potentially invasive agents. These include the continual secretion of mucus onto the surface, which subsequently sloughs with its parasitic burden, to the environment (Pickering 1974), the presence of lysosomes (Fletcher & Grant 1968; Fletcher & White 1973), proteolytic enzymes (Hjelmeland *et al.*, 1983), complement component (Harrel *et al.*, 1976; Nelson & Gigli 1968), and antibodies (DiConza & Halliday 1971; Fletcher & Grant 1969).



The precise role of the immune system in the protective function of the integument is not known, although Harris (1972) has suggested a major surface immunity capability for the epidermal surface, and Peleteiro & Richards (1985) have described and defined an extensive supra-basal layer of lymphocytes in the epidermis of salmonids, which also appears to occur in the skin of many other fishes.

The skin of the snakehead is particularly complex in structure and especially difficult to study histologically. This is because of the extreme delicacy of the epidermis and the presence in the dermis of the very thick scales which underlie it. This also makes study of the process of wound repair, and the healing of ulcers, very difficult, due to the technical problems of cutting histological sections through skin tissues. Thus, although ulceration of snakehead skin and its healing are of critical economic importance during the current epizootic, no reports are available to show how such pathophysiological processes occur. Such an understanding is essential to underpin any research on the ulcerative condition.

## REVIEW OF THE LITERATURE

### FISH SKIN

Although the finer detail of the structure of the skin varies widely among the different groups of the teleost fishes it has a number of features in common. It does however differ significantly from the exposed skin of other vertebrates, most notably at the surface, where, in fishes, unkeratinised living epidermal cells, capable of mitotic division, are in direct contact with the environment. Fish skin is also the only barrier to the often very significant osmotic pressure differences between the *milieu interieure* and the external water. Many and varied are the other environmental factors against which it is proof. For example major variations in pH, and temperature, environmental pathogens and a wide range of anthropogenic chemical substances against which it is ill adapted and which increase in level and diversity annually, all require to be actively controlled by skin function. Aspects of the structure and physiology of the skin of a wide range of teleosts have now been studied ( Brown & Wellings 1970; Bullock & Roberts 1975; Fishelson 1972; Hawkes 1974).

Teleost skin is composed of a number of distinctive layers (Fig. 2 ). The distal layer is the cuticle, which overlies the external cellular layer, the epidermis; the dermis is the mid layer and composed principally of fibrous tissue, the basal hypodermal layer is the inner layer, abutting on the musculature.

### Cuticle

The cuticle is a complex of cell protoplasm, sloughed cells and goblet cell mucus which has been released onto the surface to form a non-living external surface ( Bullock & Roberts 1978; Whitear 1970). It is, under normal circumstances, 1-2 micron thick. It is norma'ly secreted onto the epidermal surface, from the specialized apocrine mucous gland cells, and from the cell fluids and organelles of sloughed degenerate Malpighian cells (Bremer 1972; Merrilees 1974; Whitear 1970). Lester and Desser (1975) have shown that the cuticle of the euryhaline three-spined stickleback, *Gasterosteus aculeatus* L. sloughs off at regular intervals.

The cuticle is normally difficult to demonstrate in histological preparations as it is liable to loss of its very delicate attachment from the surface of the outermost layer of Malpighian cells during preparation of sections for microscopy (Hawkes 1974).

### Epidermis

The epidermis is derived directly from the ectoderm of the embryo ( Van Oosten 1957). It is a stratified squamous epithelium comprised principally of Malpighian cells, and covers the entire body surface. The teleost epidermis is particularly unusual in that all of the component cells are living and cells capable of mitotic division can be found at all levels, apart from those surface layer cells which are about to slough into the cuticle as part of its replacement from below

(Henrickson 1967; Roberts *et al.*, 1970). The number of cell layers and thus the thickness of the epidermis varies not only with the species but also with the particular site on the body and with the age of the fish. In pelagic fish, the ventral epidermis is the thicker (Bullock & Roberts 1975; Limsuwan *et al.*, 1986 ). The thickness of brown trout, *Salmo trutta* L. epidermis was found to fluctuate rhythmically during successive annual cycles and the epidermal thickness of the male to be significantly greater than of the female ( Pickering 1977). Roberts and his co-workers (1971) reported that the thickness of plaice skin, *Pleuronectes platessa* L. was remarkably consistent over the body surface but varied with age. Hildemann (1959) suggested that hormonal changes altered the thickness and complexity of the epidermis and Pickering and Richards (1980) showed that the salmonid epidermis, at least, changed its thickness and proportions of the different cellular components in response to both internal and external stimuli, including hormonal modification.

Teleost epidermis is composed principally of relatively small basophilic cells, the filament-containing Malpighian cells. It also contains various types of unicellular glands, such as mucous cells, club cells, eosinophilic granule cells and sacciform granular cells, as well as the special sense organs associated with taste, touch and proprioception. Fish epidermal cells are not, as in higher vertebrates, able to be designated into specific layers in respect to a distinct

sequence of differentiation of Malpighian cells. Thus it is not possible to subdivide the fish epidermis into stratum germinativum or basal layer, middle layer and surface layer.

The basal layer is composed of a single layer of cuboidal or columnar cells with oval or spherical nucleus (Henrickson & Matoltsy 1968 a,b; Merrilees 1974; Mittal & Munshi 1971). There are lymphatic spaces between these cuboidal or columnar cells and small numbers of lymphocytes may be observed there ( Limsuwan et al., 1986; Mittal & Banerjee 1975a; Peleteiro & Richards 1985). The basal cells rest on a single basal lamina or basal membrane which ultrastructurally has the typical trilaminar structure of the vertebrate basal membrane and stains strongly for glycoprotein ( Roberts et al., 1972 ).

The middle layer of the epidermis varies greatly depending on species. In addition to the rounded, filament containing, Malpighian cells, which are the main structural component, club cells, sacciform granular cells, apocrine mucous glands or goblet cells and taste and touch receptor organs are found, but vary in their distribution between species.

#### Club Cells

The club cells are a group of large clear staining cells found in the mid-layers of a number of teleost groups. Although they are apparently similar in their light microscope appearance, they seem to differ in function and ultrastructurally. They are similar within

groups, but distinctive from group to group ( Roberts & Bullock 1976).

Typical club cells are large, round and centrally binucleate, having two nuclei very close to each other. Where they occur their cytology is similar in both larval and adult epidermis. The pale pink cytoplasm of the club cell in haematoxylin and eosin stained sections is homogeneous in nature and invariably shows shrinkage due to fixation. Club cells are not found in the skin of snakehead (Mittal & Banerjee 1975a).

#### Sacciform Granular Cells

These cells are large unicellular cells with a clear granular cytoplasm. They are not found in scaleless fish, but where they do occur, in some scaled fish groups, they are found in the middle layer of the epidermis. The sacciform cells often extend from the stratum germinativum right up, to open onto the surface, by narrow pores. Usually, when fixation is carried out, the contents of the cells shrinks and leaves a clear area of space between the cell membrane and the concentrated organelles (Mittal & Banerjee 1975a; Mittal & Munshi 1971). Their content is granular in nature and does not give histochemical reactions for mucopolysaccharides. Sacciform granular cells are found in a wide variety of teleost epidermis especially in those higher teleosts with well developed scales, but their function is still unknown. They occur in the epidermis of *Channa striatus* as well as the other members of the genus.

### Mucous Cells

The mucous or goblet cells are found suprabasally in the epidermis and increase considerably in size as they pass through the mid-layer. They are derived from the basal layer of the epidermis (Harris & Hunt 1973; Van Oosten 1957). Immature mucous cells are rounded but they flatten laterally as they mature and the nucleus and organelles are displaced basally (Bullock & Roberts 1975). They are readily visible in haematoxylin and eosin stained sections as large, clear, ovoid, spherical or flask-shaped cells. The distribution of mucous cells within a small area of epidermis is not always uniform (Pickering 1974).

Histochemical and biochemical analyses of fish mucus have demonstrated that the components contain both protein and carbohydrate (Harris & Hunt 1973; Lehtonen *et al.*, 1966; Leppi 1968). The carbohydrate nature of the secretion is readily demonstrated by the Periodic Acid Schiff reaction (Harris & Hunt 1973; Henrikson & Matoltsy 1968 b; Kitzan & Sweeny 1968; Linsuwan *et al.*, 1986; Mittal & Munshi 1971; Roberts *et al.*, 1971). Sialic acid has been isolated from the mucus of teleost fish (Enomoto *et al.*, 1964; Harris & Hunt 1973; Pickering 1974), and Harris and his co-workers (1973) suggested that there may be some sulphated mucosubstances present, at least in the mucus of brown trout. The mucous cell concentration of individuals of the same species, sex and age may be extremely variable (Bullock & Roberts 1975; Henrikson & Matoltsy 1968 b; Pickering 1974; Pickering & Macey 1977).

### Eosinophilic Granule Cells or E.G.C.'s

The eosinophilic granule cells are round or ovoid cells with a marginally placed nucleus and a cytoplasm packed with highly eosinophilic refractile granules. They are not found in the epidermis of all species, and when they do occur their presence may be very variable. They have been described in some detail in the snakehead (Mittal & Banerjee 1975a; Mittal *et al.*, 1976), and also in the plaice and some other marine species (Roberts *et al.*, 1971; Roberts & Bullock 1976). The position of the eosinophilic cells in the epidermis varies from species to species. In some species they are basal, in others they may occur near the epidermal surface. They are of approximately the same diameter as the mucous cells. The function of E.G.C.'s in the teleost epidermis is equivocal. Roberts and Bullock (1976) have suggested a similarity to mast cells, ultrastructurally, but no biochemical confirmation of this is available.

### Sensory Organs

Sensory organs were first discovered and described in fish by Leydig (1851). They are present throughout the epidermis of teleost fish. According to Bullock and Roberts (1975) these sensory units are divided into three groups: Group A, free neuromasts and canal organs, contained within the lateral line canal; Group B, taste receptor organs (taste buds); and Group C, chemical receptors.

Neuromasts are complex, surface structures. The



upper part of the neuromast is composed of the cupula, a flexible jelly-like structure attached to the apical edge, and sensory hairs, the stereocilia and kinocilia which connect with the cupula. This connection is thought to serve the mechanical transmission of information on cupula shearing movements to the sensory cells (Flock 1965). The sensory receptor component of the neuromast consists of a cluster of pear shaped mechanoreceptor cells, the apical surface of which bears numerous bundles of sensory hairs. This sensory component is encased in fusiform supporting cells situated near the periphery of the neuromast, extending around the basal ends of the sensory cells. The laterodistal surface of the neuromast is capped by the thin layer of flattened mantle cells (Bullock & Roberts 1975).

By the use of scanning electron microscope techniques, Flock (1971) has demonstrated that both free neuromasts and lateral line canal organs have a similar ultrastructure.

A single taste bud is spherical or flask-shaped and is surrounded by the epithelial cells. It consists of two different cell types, namely, receptor or sensory cells and basal or support cells (Bardach & Atema 1971; Cordier 1964; Hirata 1966; Kapoor *et al.*, 1975; Murray 1973; Reutter 1978). The receptor cells are elongated cells which are arranged vertically and extend from the basal part to the apex of a bud. The two to five basal cells are arranged transversally to the longitudinal axis

of the taste bud and connected to the supporting cells and protoplasmic threads (Herrick 1904). Between the basal cells and the sensory cells, is located the nerve plexus (Reutter 1982).

The chemical receptors occur on the oral epithelium as well as upon the body surface ( Bullock & Roberts 1975), they are single units with a centrally placed nucleus, and a distal process terminating in a microvillus at the apical edge. They are found in between the epithelial lining of the olfactory organ of the teleost fish (Reutter 1982).

#### Basement Membrane

The basement membrane, which in the light microscope appears as a narrow but dense line between the epidermis and the dermis, is very complex. On the dermal side, the reticular fibres abut on the basal lamina proper, which is an amorphous electron dense layer 600 to 800  $\text{\AA}$  thick, poorly defined, and following the contour of the bases of the epithelial cells. It is separated from them by a light zone approximately 400  $\text{\AA}$  wide. The dense and very complex basement membrane, with its modified basal plasma membrane attachment, and the very closely opposed columnar cells must play a significant part in the strength of the skin and its important physiological role in osmotic homeostasis of the internal milieu in hypo- and hypertonic environments (Roberts *et al.*, 1970). Their thickness varies in different parts of the body (Phromsuthirak 1976).

Histochemically, the basement membrane stains

strongly by the PAS reaction and its derivatives, indicating a high proportion of glycoprotein (Bullock & Roberts 1975; Roberts *et al.*, 1971). Fleischmajer and Billingham (1968) and Phromsuthirak (1976) suggested that the basement membrane may be formed by the combined action of both the epithelium and the connective tissue from the dermis.

#### Dermis

The division of the dermis into a stratum spongiosum, comprised of scales and delicate fibrous tissue, and a stratum compactum, comprised of a dense matrix of collagen bundles, is clearly seen in most teleost fishes, although in the scaleless fish dermis, its differentiation is not so pronounced (Grizzle & Rogers 1976; Limsuwan *et al.*, 1986; Mittal & Munshi 1971).

#### Stratum Spongiosum

The stratum spongiosum is supplied with a very dense plexus of fine blood capillaries and lymphatics and nerve fibres. The cellular components of the spongiosum include the mast cells, mononuclear cells, pigment cells and scales (Bullock & Roberts 1975; Mittal & Banerjee 1975b; Roberts *et al.*, 1971). The epidermis is draped over the leading edge of the scales, which in most species overlap like roof tiles and it reflects their serrate arrangement (Henrikson & Matoltsy 1968 b).

#### Scales

By light microscopy the scales can be observed in the outer loose connective tissue of the dermis

(Bullock & Roberts 1975; Groman 1982). They are arranged in an overlapping pattern in diagonal rows. This pattern forms during the early stages of life and is retained thereafter. If scales are pulled out, they will be replaced, even if the scale pocket is severely damaged (Reif 1978).

The scale-forming cells, called osteoblasts (Neave 1936 a,b; Van Oosten 1957) or scleroblasts (Van Oosten 1957), are derived from mesoderm cells along the lateral line. The mesodermal cells move out along the collagen bundles, forming clusters at major points of intersection of the bundles and here they give rise to the scales (Fitton - Jackson 1968). Scale growth continues throughout life by addition of new material at the edges, causing rings analogous to the annual rings formed in the trunk of the growing tree (Neave 1936b; Van Oosten 1957).

There is variation in the composition of scales between species. They are composed of an inner fibrillar layer and outer calcified layer, both of which are entirely derived from the mesoderm and are analogous to bone in their calcification (Brown & Wellings 1969; Hyman 1962; Neave 1936a,b; Van Oosten 1957). The deeper layers of the scales consist only of collagen fibres embedded in the matrix material, but the collagen of the scale differs from that of dermal collagen in its staining properties. Cells which are apparently responsible for scale formation are located along the deep and superficial surfaces and the edges of the scale,

and are morphologically identical to fibroblasts. Unlike the other connective tissue structures of the dermis, the scale lacks blood vessels and pigment cells. Scale-forming cells are observed only on the surface of the scale, not within it (Brown & Wellings 1969).

#### Pigment Cells or Chromatophores

Chromatophores are located in the stratum spongiosum and are usually classified according to the nature of their pigment as melanophores, lipophores, leucophores and iridophores (Bullock & Roberts 1975; Fujii 1969; Hawkes 1974). The comparative physiology of the chromatophores of teleost and other poikilotherms is described in some detail (Bagnara & Hadley 1973).

Melanophores are the pigment cells containing black and brown pigments. Melanins are the predominant pigment cells found in many parts of the body and the morphology and ultrastructure of the cells containing them has been reviewed by Roberts (1975a). The pigmentary melanin containing cells of fish are the melanocytes and melanophores. Melanocytes are immature melanophore actively producing melanin but capable of becoming melanophores. Melanocytes are dendritic cells whereas melanophores are more regular, asteroid structures (Bullock & Roberts 1975).

Lipophores are those chromatophores containing pigments which are insoluble in water but soluble in organic solvents (Bullock & Roberts 1975). The pigments of lipophores are mainly carotenoids, which cannot be synthesized within the body and must, of necessity, come

from the food (Bullock & Roberts 1975). The fine structure of the lipophores has only been studied in a few fish, mostly freshwater species (Matsumoto 1965; cited by Bullock & Roberts 1975).

Leucophores and iridophores are globular or elliptical with large nuclei located in the upper central portion of the cell. Mitochondria, numerous enough to be easily seen with the light microscope, are clustered below the nucleus and characteristically contain dense granules (Hawkes 1974). Both leucophores and iridophores contain purines which are responsible for the white and silver colours. The purine, largely guanine is contained in the form of platelets in the cytoplasm (Bullock & Roberts 1975). The orientation of the arrays of platelets varies markedly with the site on the body (Harris & Hunt 1973).

#### Stratum Compactum

The stratum compactum is characterized by the presence of bundles of coarse collagenous fibres arranged compactly in several layers. A few collagen fibre bundles run vertically at intervals and these may support vascular supply vessels to the spongiosum (Bullock & Roberts 1975; Mittal & Banerjee 1975b; Mittal & Munshi 1974). This layer is also supplied to a limited extent with fine nerves and a few blood capillaries. Pigment cells are seen distributed sparsely on the inner aspect of this layer (Bullock & Roberts 1975; Burton 1978; Hawkes 1974; Holmberg 1968). Mittal & Munshi (1971) suggested that there was an inverse relationship between

the thickness of the stratum compactum and the development of the scales.

#### Hypodermis

The hypodermis or subcutis is a layer of varying thickness lying between the muscle bundles and the stratum compactum. It is mainly composed of fat cells, fine collagen fibre bundles and elastic fibre bundles (Bullock & Roberts 1975; Mittal & Munshi 1971; Roberts *et al.*, 1971). Main branches of nerves and blood vessels are found in this layer. It is thin and poorly developed in many teleost species but it can be a significant fat deposit zone, with its thickness varying from season to season (Jakubowski 1958; Mittal 1968; Mittal & Banerjee 1975 b; Mittal & Munshi 1970, 1971).

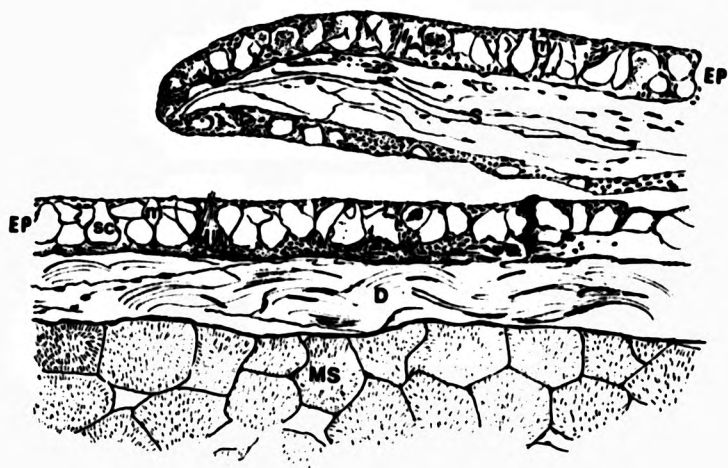
#### SNAKEHEAD SKIN

The skin of the striped snakehead fish, as with other teleosts, is composed of the three principal layers; the outermost layer or epidermis, the thick and very dense dermis and the thinner hypodermis (Fig. 2 ). The detail of striped snakehead skin has been described principally by Mittal & Banerjee (1975 a,b), who defined it as follows.

The epidermis is readily divided into three layers. The basal layer or stratum germinativum is composed principally of a single layer of cuboidal or almost flat cells abutting a thin basement membrane. In between the basal cells there are small irregular lymphatic spaces and readily observed numbers of

Fig. 2. The diagram of normal snakehead skin  
EP = epidermis  
D = dermis  
m = mucous gland  
s = scales  
T = taste organ  
MS = muscle bundle  
sc = sacciform granulated cell





lymphocytes are invariably found inside these spaces .

The middle layer is composed principally of large numbers of unicellular glands, the mucous cells and the sacciform granulated cells. There are two types of mucous cells; one is a small oval and round cell and the other is a large elongate cell (flask-shaped) with mucus, in the mature cell, forcing the cytoplasm and nucleus to the periphery of the cell. The secretion of the mucous cell is, as in all fish, PAS positive, basophilic, refringent, and contains strongly acidic sulphated mucopolysaccharides.

Mittal & Banerjee (1975 a) did not discuss the presence of sensory cells in the epidermal layer of striped snakehead in their study, but there are pear shaped sensory structures present over the entire body surface. The sensory cells of the striped snakehead resemble taste buds in structure and may receive chemical stimuli from water currents (Vasu 1962).

In haematoxylin and eosin stained sections the contents of the sacciform cells appears homogeneous and they open to the surface by a narrow pore. The eccentric nucleus is pushed towards the basal part of the cell due to the accumulation of secretory matter. In Masson's trichome stained sections the coarse secretory granules take on a pale red colour and they are also PAS negative. The content of sacciform granulated cells are acidophilic.

The superficial layer of the striped snakehead epidermis consists of a few tiers of polygonal or roughly triangular cells. Between these cells some small

mitochondria-rich cells, the chloride cells, are found. The epidermis of striped snakehead is nonkeratinized and its thickness varies with age and position on the body. It becomes thinner as it invests the posterior free margin of the scales and is very thin on the underside of the scale.

The dermis is composed of the normal two layers of the typical scaled teleost; the stratum spongiosum, the upper layer, containing the scales, pigmented cells, fat cells, a variety of vascular and neural components and connective tissue pocket is well developed. The lower layer; the stratum compactum, is composed of particularly coarse and dense collagen fibre bundles, compactly arranged in several layers. A large number of blood capillaries and lymph vessels are found close to each other below the basement membrane. These are more numerous than in the typical teleost. It is suggested that these may have a function in respiration when the fish is out of water (Mittal & Banerjee 1975b).

Melanin pigment containing cells are seen to be dense both in the normal position beneath the basement membrane and also in the stratum spongiosum proper. A layer of pigment cells, supplied with capillaries and nerves, is also found in the connective tissue pockets on the surface of the scales. Some irregularly round, yellowish-red or orange lipophores are distributed between the melanophores.

The scales of the striped snakehead are composed of two distinct layers; a thin, upper basophilic

osseous layer and a thick, lower eosinophilic fibrillary plate. The annuli on the free surface of the osseous layer appear serrated in cross section.

The hypodermis or subcutis is a very thin layer lying between the dermis and the muscle bundles. It is mainly composed of adipose cells, loose connective tissue, blood vessels and nerve bundles. No melanin pigment cells are observed in this layer.

#### WOUND HEALING IN FISH

Skin damage constitutes the major route of infection for many of the pathogenic bacteria, ciliate protozoans and fungi which affect fish (McVicar & White 1979; Pickering & Richards 1980; Roberts 1975a), and if the lesion is extensive or is increased in size by the effects of the pathogen, the fish may die rapidly due to extensive loss of body fluids and resulting osmotic effects (Hickey 1979; McVicar & White 1979). Thus it is imperative for the teleost to be able to rapidly heal such wounds, or at least to render them proof to loss of osmotically active molecules as soon as possible. Both larval and mature teleosts show rapid epidermal coverage of skin wounds (Anderson & Roberts 1975; Bullock *et al.*, 1978; Hickey 1982; Mittal & Munshi 1974; Phromsuthirak 1976). The capability for wound repair in a teleost is related to several variables, including the degree of damage, the temperature (Bisset 1946; Finn & Nielson 1971b), nutritional status and stress factors (Halver 1972).

The wounds are not, however, covered, as might be expected in higher animals, by proliferation and migration, over some days, of cells from the edges, to replace a scab which is already sealing the lesion. Instead there is an extremely rapid mass migration of epidermis from the wound periphery without a phase of rapid cell division before or during closure (Arey 1936; Chiakulas 1952; Mittal & Munshi 1974; Mittal *et al.*, 1978).

Although there are many, somewhat confused reports on the process of wound healing in fish skin, it was only when sequential pathogenesis studies, at different temperatures, were carried out, that a proper understanding of the particular features of wound healing in fish was gained.

Early study on the healing of fish skin wounds was done by Smith (1931), who noted the association of melanophores with experimental wounding in goldfish, *Carassius auratus* L.

Mittal and Munshi (1974) observed the regeneration and repair of superficial wounds in the skin of scaleless freshwater fish, *Rita rita* (Ham.). They found that the lymph spaces of the stratum germinativum, on the 4th day after the formation of the wound, become gorged with lymphocytes which may play an important role in the local defence mechanism. This result has been confirmed by Mittal, Rai and Banerjee (1978).

In 1979, they also reported that the mucous cells at the outermost layer of the wounded epidermis of catfish start secreting profuse amounts of mucopoly-

saccharides immediately after the infection of the wound. After 30 minutes, such cells show a sudden decline in their dimensions. They suggested that the increase in the secretory activity of the mucous cells under such condition may be in order to serve a protective function preventing bacteria and other infective agents from invading the body through the damaged surface. The excessive secretion of mucus also perhaps establishes a barrier to reduce exchange of salt and water into the body that might have occurred through the otherwise unprotected wounded areas, playing an important role in re-establishing the osmotic equilibrium between the internal and external environments of the body. These findings were similar to those of Al-Hassan (1983). They suggested that the abrupt secretion of a mucus-like gel in response to an injury in the marine catfish, *Arius thalassinus* Ruppell. may have a primary function in healing. The gel-like material was composed of protein (<85%), some lipid (7%), carbohydrate (<3%) and nucleic acid (<5%). A preparation made from the skin gel also increased the rate of wound healing in other laboratory animals (Al Hassan *et al.*, 1985).

Ashley and his team (1975) considered that epidermal repair, which was completed first in the healing of salmonid skin incisions was of special significance, since dermal healing in mammalian skin either precedes or occurs concomitantly with epidermal repair. Replacement of melanin, scales, deep muscle and fascia in trout appeared to occur concurrently with

repair of the dermis. Foreign body giant cells were occasionally present within such wounds.

Phromsuthirak (1976) carried out wound healing experiments in the stickleback. He showed that as in others species, the epidermis around the edge of the incision moved into it. The migrating epithelial cells were show to be phagocytic and really active within two and three hours of his small wound . The epidermal cells were elongated in every layer of the epidermis within 12 hours after wounding. He also identified the leucocyte types in the damaged area by electron microscopy and confirmed that neutrophil granulocytes, which reached a peak in 24 hours after wounding and declined during the second day; were phagocytic although not to the same extent as the macrophages. Between 1 to 3 days after the incision, the epidermis joined across the breach. The joined epidermal layer was not supported by either basement membrane or dermal substance. After the dermal substance had invaded the epidermal mass, closing the incision by day 8, there was reformation of the basement membrane between the new dermis and the epidermal cells above it. He concluded that in the three spined stickleback, the healed epidermis was normal by day 8.

Saxena & Kulshrestha (1982) reported the effect of DDT on the regeneration of cutaneous wounds in mystid catfish, *Mystus vittatus* (Bloch). They found that the regeneration of wounds, the epithelialization and fibroblastic activities under DDT stress was slower than in controls.

Jauncey and his co-workers (1985) described the process of skin wound healing in Nile tilapia, *Oreochromis niloticus* (Trewavas) in normal and vitamin C deficient conditions. They reported that by 5 hours the epidermal cover was complete and by 10 hr a large number of macrophages had accumulated within the wound and active myophagia was extent, irrespective of vitamin C status but that subsequent changes in the fibrous tissues only occurred in vitamin C sufficient fishes.

#### RELATIONSHIP BETWEEN TEMPERATURE AND WOUND HEALING

Fish are poikilothermic vertebrates and so are forced to assume the temperature of their environment, and indeed their metabolic rate decreases more rapidly than body temperature as the ambient temperature falls (Prosser 1962). The effects of temperature are important to all aspects of the physiology of the teleosts, controlling the rate of feeding, the ability to escape from predators, oxygen requirements, and many other factors. The strategic control by temperature of the balance in the continuous and closely meshed power struggle between the teleost and its hostile environmental pathogens is one of the most significant factors in its ectothermic existence (Roberts *et al.*, 1971). Teleosts are nevertheless among the most successfully adapted groups of animals, the largest group of vertebrates, with a capacity for climatic adaptation which has allowed them, as a group, to inhabit waters ranging in temperature from  $-2^{\circ}$  C around the polar



ice caps to temperatures in excess of 35° C in the equatorial regions (Roberts 1975a).

McQueen and his colleagues (1973) reported that the rates of metacercarian cyst and capsule development in plaice were considerably lessened by temperature reduction of 10°C, but there was apparently no qualitative difference in response in the time scale of these experiments, except for the absence of melanin at the lower temperature. The more serious muscle damage resulted at the higher temperature.

Anderson & Roberts (1975) compared the effects of temperature on wound healing in a tropical and a temperate teleost. They reported that the wounds were covered in less than 2 hours at warm temperatures and within 24 hours at cold temperatures. Necrotic muscle in the fish wounds had been removed after only 7-18 days at warm temperature and even at cooler temperature the time taken was no longer than that in the homeothermic mammal. Advanced regeneration was seen in the fish within four weeks at warm temperatures. They also suggested that wound healing in both the white mountain cloud minnow, *Tanichthys albonubes* L. (WMC) and the Atlantic salmon, *Salmo salar* L. is directly correlatable with environmental temperature. Stress appears to have less influence on the rate of wound healing than temperature in both species, at the high and low ends of their temperature ranges.

Timur M. (1975) reported that the particularly significant feature of the carrageenin lesion, an

artificially induced chronic inflammation, was the fibroblastic activity and this was especially delayed by the reduction of temperature to 5°C. In addition, there was a less intensive inflammatory cell response, but one which was much longer lasting. This coincided with the much longer period of myophagic activity before the removal of necrotic sarcoplasmic debris.

The effect on the cellular components of the inflammation caused by temperature reduction, in Timur's work, extended the findings of the other workers in relation to the effect of temperature on epithelioid and giant cell development. At the higher temperature (10°C), the myophagia was complete before significant epithelioid cell development took place, and also giant cell formation was faster than at the lower temperature (5°C).

Bullock and his group (1978) reported that the closure of small wounds in plaice was achieved within nine hours at 10°C and by 12 hours at 5°C. The thickness of migrated epidermal covering was much thicker at 15°C than 5°C.

Hickey (1982) found that the rate of epidermal migration over skin wounds in larval plaice was almost doubled by a 10°C rise in temperature.

## VITAMIN C AND WOUND HEALING

Studies on fish nutrition over the last two decades suggest that dietary deficiency of vitamin C results in poor growth, various skeletal deformities, distorted hyperplastic gill cartilage, haemorrhages, loss of scales and delayed wound healing (Andrews & Murai 1975; Ashley *et al.*, 1975; Halver 1972; Halver *et al.*, 1969, 1975; Hilton *et al.*, 1978; Kitamura 1969; Kitamura *et al.*, 1966; Lim & Lovell 1978). Most fish are unable to synthesize vitamin C, and therefore have to rely on a dietary, exogenous source (Chatterjee 1973; Wilson & Poe 1973). An inability to synthesize L-ascorbic acid is due to absence of the enzyme L-gulonolactone oxidase in hepatic and renal tissue (Burns 1957), which is responsible for conversion of L-gulonolactone to L-ascorbic acid in kidney and/ or liver tissue (Chatterjee *et al.*, 1961; Grollman & Lehninger 1957). The importance of ascorbic acid for the metabolism of connective tissue substances, especially collagen, has been established by numerous investigators (Halver *et al.*, 1975; Lim & Lovell 1978; Mauck *et al.*, 1978). They indicated that collagen formation, as in wound repair, increases the need for ascorbic acid.

Halver and his co-workers (1969) found that wound repair was delayed or inhibited, in coho salmon and rainbow trout fed on low vitamin C diets. Salmon and trout fed diets devoid of ascorbic acid failed completely to repair the wound within a 3 week period. The unhealed wounds, in the salmon, remained partially plugged with

poorly clotted blood and little or no granulation tissue was present. In an other experiment, Halver (1972) reported that the rate of wound repair in either the abdominal or in the dorsal-lateral area of the musculature was directly related to ascorbic acid intake.

Ashley and his colleagues (1975) mentioned that wound repair was generally poor in trout fed vitamin C at the 5 or 10 mg levels, while salmon fed vitamin C at these levels, repaired wounds somewhat better. Both species of salmonids repaired wounds nearly as well as control fish when fed 40 mg or more of ascorbic acid per 100 grams of diet.

In the experiments of Timur M. (1975) in the plaice, he showed that the maintenance of fish bearing carrageenin granulomas on an excess of L-ascorbic acid did not affect the general features of the granuloma, except with regard to fibroplasia. As well as increasing the degree of fibroplasia, it appeared to stimulate the fibroplasia five days earlier than in carrageenin granulomas where the fish were maintained on ordinary diets.

According to Lim & Lovell (1978) the rate of wound repair in channel catfish, *Ictalurus punctatus* (Rafinesque) appeared to be related to the level of dietary vitamin C up to 60 mg/kg. Fish fed vitamin C-free diets replaced the injured muscle by dense but immature collagen fibres. Fish fed the diet containing 30 mg/kg of vitamin C showed mature collagen fibers replacing the damaged muscle. Fish fed the diet

containing 80 mg/kg. of vitamin C had normal muscle regeneration.

The process of skin wound healing in Nile tilapia, both in normal and vitamin C deficient conditions, was described by Jauncey and his team (1985). They found that the epithelial element of the healing process developed irrespective of vitamin C level but fibroblast activity and collagenization was very much slower in the deficient group, and in these, the lesion was not mature even at the termination of the experiment at 16 days.

The ascorbic acid requirements of various fish species are much variable as shown in table I:

Table 1: Showing optimum vitamin C requirements of different fishes as determined by various workers

Fish species	Environmental Temperature ° C	Requirement Criteria	mg/kg diet	Ref.
Rainbow trout <i>Salmo gairdneri</i>	10-15	Growth, tissue repair	100	Halver <u>et al.</u> (1969; Halver (1972)
	15	Growth	70	Halver <u>et al.</u> (1975)
	15	Growth	170-730	Hilton <u>et al.</u> (1978)
	15	Growth	40	Hilton <u>et al.</u> (1978)
	15	Wound healing	500	Halver (1972)
Coho salmon <i>O. kisutch</i>	15	Growth	50	Halver <u>et al.</u> (1969)
	15	Wound healing		Halver <u>et al.</u> (1969)
Chinook salmon <i>O. tshawytscha</i>	10-15	Wound healing tissue repair	100-150	Halver (1972)
Channel catfish <i>Ictalurus punctatus</i>	20	Growth Wound healing	60	Lim & Lovell (1978)
	20	Growth	50	Andrews & Murai (1975)
	27	Pinal abnormal Growth tissue	25 50 200	Murai <u>et al.</u> (1978)
Mrigal (fry) <i>Cirrhina mrigala</i>	25-35	Growth Pathological signs	700	Mahajan & Agrawal (1980)

#### THE MIGRATION OF THE EPIDERMIS

Most of the scientists who work on the healing of fish skin agree that the epidermal cells on the margins of the skin defect rapidly migrate to cover the lesion. Bullock and his co-workers (1978), in their detailed study of the cell kinetics of plaice epidermis, using isotopic labelling and *in vitro* preparations as well as live fish, found that there was a very rapid migration of Malpighian cells into the defect, which was not accompanied by any evidence, over the time scale of the study, of a mitotic burst. Numbers of cells labelled with tritiated thymidine were similar in migrating and in peripheral epidermis and mucous cells appeared to be randomly distributed except in the periphery of advancing cells migrating into the defect, where they were absent. The epidermis of the teleost is well endowed with desmosomal junctions and tonofibrillar connections but these rapidly detach to allow such prompt movement.

Hickey (1982) said that when skin or epidermis of larvae was removed, epidermis from the wound periphery spread over its surface until cells from all sides converged and the wound was completely covered. Wound were covered by mass migration of cells from the wound periphery without a rapid phase of cell division before or during closure. Mitoses were rare in the epidermis migrating over the wound. The wound closure appeared to depend on a redistribution and migration of existing peripheral epidermal cells rather than on a rapid phase of cell division.

Jauncey and his colleagues (1985) showed that in the tropical tilapia immediately after incision, the surrounding epithelium became spongiotic and migration of Malpighian cells down into the wound commenced, covering the surface of the fibrinous tissue exudate. Within one hour this migration was well on its way to covering the entire surface of the defect. By 5 hours this epidermal cover was complete, and at the centre, where the inward migrating edges met, a marked cumulus of exuberant epithelium was present.

Bullock and Roberts (1980) showed that the presence of pathogenic bacteria on the surface of the ulcer completely inhibited any migration of peripheral epidermal cells and subsequent under running of the ulcer by the bacteria resulted in its expansion, as peripheral epidermis sloughed.

#### FIBROSIS IN FISH

Fibroblasts are derived from the local mesenchymal cells and loose areolar perivascular tissue (Dunphy 1963; Edward & Dunphy 1958; Grillo 1963; Hadfield 1963; ; McMinn 1967). New fibroblasts in healing wounds may arise by proliferation of local dermal connective tissue, from perivascular precursors, or they may possibly come from the endomysium of muscle bundles. Fibrogranulation tissue and replacement fibrosis is much more extensive in wounds produced by prolonged, chronic inflammatory stimuli than in incision wounds (Anderson & Roberts 1975) and, as might be expected, fibrosis



develops, initially, more rapidly at high temperatures than at low temperatures (Anderson & Roberts 1975; McQueen et al., 1973; Roberts 1975a; Timur M. 1975).

Mittal and his co-workers (1978) demonstrated that in their experimental lesions in some freshwater catfish, the space left following the disintegration of injured muscle bundles gradually gets occupied by numerous fibroblasts and fine blood capillaries resulting in the formation of granulation tissue. After 5 days, in their study, fibroblasts started undergoing the process of fibre formation, probably of precollagen, first at the wound margins and below the basement membrane and then gradually towards the centre and the deeper parts of the granulation tissue.

An active metabolite of vitamin C or L-ascorbic acid has been demonstrated as a necessary co-factor for hydroxylation of proline during collagen formation (Halver 1972). In Timur's studies (Timur M. 1975) he showed that fish undergoing inflammatory granulation following carrageenin damage, which received luxury of vitamin C in the diet, showed faster fibroplasia than controls. He also suggested that since fibroplasia is a production process involving major protein metabolic pathways, it is possible that this metabolic requirement, which is temperature controlled, is greater than that required for other aspects of inflammation.

### MUSCLE REGENERATION IN FISH

There is no general consensus of opinion on the problem of the origin of myofibrillar tissue and there is a considerable controversy as to whether the cells of highly differentiated structures can act on their own behalf in post traumatic repair or whether an infusion of new cells from a normally dormant reserve population is necessary. The satellite cells, which are described by various authors (Church 1969; King 1975; Mauro 1961; Prsybylski & Blumberg 1966; Shafiq *et al.*, 1967) in various vertebrates, located in between the muscle fibre proper and its basement membrane, are however generally thought to be activated to proliferate and later differentiate into muscle. Cells other than satellite cells have been considered to represent reserve populations. These have been primary cells of the endomysial or perivascular connective tissue and at times even nucleated blood cells (Carlson 1973).

Ramachandran & Thangavelu (1969) found that experimental *Ophicephalus* muscle regeneration started in 7-8 days and in 10-15 days complete muscle regeneration was shown. The muscle tissue differentiated from the deeper portion and newly formed muscle fibres were seen by nine days.

Halver (1972) confirmed that regenerating muscle fibres were better represented in wounded fish receiving at least 1g of vitamin C/kg of diet during the recovery period than in fish not so supplemented.

Mittal and his colleagues (1978) confirmed the

muscle regeneration in scaleless freshwater fish, and the catfish, *Heteropneustes fossilis* (Bloch). The muscle bundles appeared at the margins of the wound gap near the uninjured muscle bundles and then in the subsequent stages these were gradually observed regenerating also towards the centre. These muscle bundles enlarged and gradually attained large dimensions by the end of this period (35 days). They also suggested the novel and somewhat unlikely mechanism that the nuclei break off from damaged muscle fibres and after becoming completely invested with a cell membrane, serve as the cellular source of the regenerating muscles.

Anderson & Roberts (1975) and Timur M. (1975) also found evidence that regeneration of some muscle fibres within the inflammatory area of healing wounds was faster at the higher temperature than at the lower temperature. Myofibrillar regeneration occurred in the form of small, hyaline eosinophilic buds in the area where granulation tissue was found.

#### EXPERIMENTAL DESIGN

The skin of the snakehead, as already indicated, is particularly complex and is characterized especially by the very dense scales. The present study was established to define the rate and mechanism by which the snakehead can heal small superficial traumatic wounds which are not complicated by secondary infection.

In order to determine optimum techniques for wounding, sampling times, methods of preparation of sections and interpretation of results, a preliminary pilot study was carried out on a small number of fish in the first instance.

Young snakeheads were wounded in the upper dorsum, examined sequentially over a period of 4 weeks, and the detailed histopathological changes observed described and discussed.

## 1: PILOT STUDY

## MATERIALS AND METHODS

Fish

Young snakehead fish obtained from a private fish farm at Suphanburi Province, Thailand, approximately 17.3 cm (14.5-19.5 cm) in length, were stocked in glass aquaria at the rate of 25 fish per aquarium for 4-6 weeks before the experiment began. This was necessary to acclimatize the fish to the laboratory conditions. Fish were fed twice daily with a nutritionally complete floating pellet containing 35% protein .

Aquaria Holding

The fish were stocked in 150 l glass aquaria (100 x 45 x 45 cm) containing static underground water of pH 7.1-7.4, alkalinity 270-290 mg/l as CaCO<sub>3</sub>, hardness 130-136 mg/l as CaCO<sub>3</sub>. Average temperature was 28.0°C (26-30°C). Water was changed once daily. Aeration was supplied via a standard aquarium aerator pump, and air-stone during the experimental period, although as snakeheads are air breathing fish they obtained air from the surface also.

Wounding Procedure

For the pilot study, 40 snakehead fish were used as the fish samples. A longitudinal surgical wound (1.0-1.2 x 0.1 x 0.5 cm) was made into the left lateral myotomal muscle of each anaesthetized fish (Benzocaine 100 ppm), and the fish were returned to the aquaria until

sacrificed. The dorsal fin above the wounded area was clipped as a marker for subsequent sampling.

#### Sampling Procedure

Two wounded fish were sacrificed routinely at 30 minutes, 2, 6, 10, 12 and 24 hours then 2, 4, 6, 8, 16, 24, 32, 40, 48, 56, 64, 72, 80 days post wounding, for the histological observation of wound healing.

#### Fixation for Histology

Fish were observed regularly, in order to follow gross changes in the lesions. At sampling, fish were killed by deep anaesthetic and a steak cut out of the dorsal musculature about 1 cm from each side of the lesion was fixed in cold 10% buffered formalin for at least 24 hours. Skin from the same area of unwounded fish was fixed for comparison. The jar containing the fixative was agitated once or twice during the next few hours to enhance the fixation (Timur M. 1975). The fixed tissue was then trimmed into a small block (0.3 x 1.5 cm), and processed in an automatic tissue processor. The dehydration was carried out by passing the tissue through ascending grades of alcohols, two changes of absolute alcohol, two changes of chloroform, followed by two changes of paraplast (wax) ( 56°C melting point ). Blocks of the wax infiltrated tissue, were then cut at 5-6 micron.

#### Staining Procedures

A variety of staining procedures was used. Standard haematoxylin and eosin staining was used for the

routine examination of sections. Van Giesson, Periodic Acid Schiff (PAS) and Masson's trichrome techniques were done as required. They were mounted in "permount" for examination.

#### RESULTS

The results in the early stages of the pilot study were the same as those in the definitive study ( see later ). At the 8-14 day stage however, it was obvious that there was a serious anomaly in the sequential pathogenesis of the developing lesion which indicated a major problem with regard to the nutritional status of the fish under experiment.

While the controls appeared normal, the healing response, in particular the fibrosis associated with granulation and scar formation, ceased to develop and the muscle fibre development also failed to occur. The lesion had large numbers of swollen active fibroblasts and there was little or no collagen in the wounded area. The regeneration of the somatic muscle was incomplete and cellular infiltration still observed in the repaired wound.

#### DISCUSSION

This pilot-study highlighted a number of problems with the methodology used. The scales of snakehead are very hard but easy to slough off when the longitudinal incision was made. Thus a transverse wound was recommended for the definitive study to cause less

damage to the scales of the experimental fish. Such a longitudinal section through the snakehead's skin wound kept the scales in their position much more satisfactorily than did a cross section preparation.

The clipped dorsal fin as a marker for the site of the lesion on wounded fish a method which works well in the case of salmonids did not work properly in the snakehead because, the clipped fin healed very quickly and became normal which made it difficult to locate the correct area of the wound.

It appeared obvious from the results from the pilot study, that the time scale of the healing process was very rapid in the snakehead especially at the early stages of the repair process, so the sampling schedule for future work was re-arranged so that it would cover more precisely the steps of the healing process.

The most important feature of the pilot-study, however was the finding that the fibrosis of the defect area, 10 days after the incision, showed great irregularity and failure to develop. This was similar to the lesions of vitamin C deficiency produced experimentally by Ashley et al., 1975; Halver 1972; Halver et al., 1969; Jauncey et al., 1985; and Lim & Lovell 1978. Change of the diet for the experimental fish in subsequent experiments was obviously essential, and live tilapia fry from the outdoor culture ponds were provided for experimental fish from this stage onward.



## ii: DEFINITIVE STUDY

Following on the findings of the pilot study and particularly the information as to the need for dietary improvement to obviate vitamin C deficiency problems, and the need to modify the technique of wound induction, the definitive study was carried out as follows:

### MATERIALS AND METHODS

#### Fish

Snakehead fish, approximately 15.5 cm. in length, were held in the same manner as described in the pilot study, except that fish were fed with tilapia fry from outside ponds once per day instead of the floating pellet, to prevent the occurrence of the vitamin C deficiency syndrome, as had happened in the pilot study.

#### Wounding Procedure

A small transverse wound (0.5 x 0.1 x 0.3 cm.) was made into the posterior lateral myotomal muscle of each fish (Fig. 3). This was made at the point where the lateral line drops abruptly, while the fish were anaesthetized. This was to ensure sampling at the correct location even when all external evidence of the wound was gone. The transverse wound was utilized because it caused less damage on the scales of the experimental fish than the longitudinal one utilized in the pilot study. A total of 90 wounded fish was returned to the aquaria for further observation.

Observations on the clinical development of the lesion were made and correlated with the picture observed histologically.

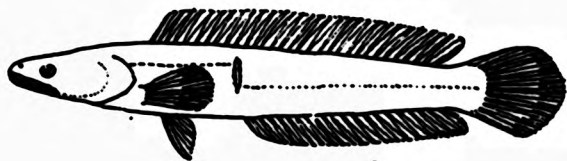
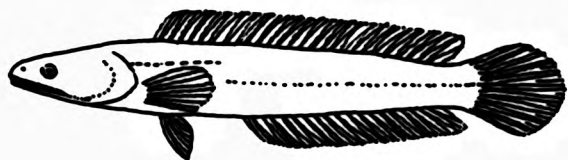
#### Sampling Procedure

Following assessment of the results of the pilot experiment, the sampling schedule was changed so that more samples were collected during the early stages when there was the most active response. At least three fish samples were killed routinely every 15 minutes after fish were wounded, for the first hour, and then every hour to the 10<sup>th</sup> hour. Thereafter, they were sampled at 12 and 24 hours, then daily till the 6<sup>th</sup> day, then every alternate day for a further 8 days and thereafter every 7<sup>th</sup> day for 28 days.

#### Fixation and Staining Procedures

The process of fixation and staining were carried out in the same way as described in the pilot study.

Fig. 3. Diagram of normal snakehead (a) and diagram showed wounding position on experimental fish (b).



## RESULTS

### Gross Pathology

When the wound was made in the skin, the muscle retracted from both sides, causing a "V" shaped gap. Although, every effort was made to ensure uniformity, the size of the gap depended on the tension of the skin in individual fish. It was however, considered that this was a normal response to wounding and that since under the circumstances the lesions were consistent, and any lesions far removed from the normal terms of gap size were discarded, it was a typical lesion. The scales covering the site were shed off when the incision was made. The amount of haemorrhage associated with the incision was variable, but it invariably ceased within a minute. The lesion was still obvious to the naked eye 2-3 days after wounding, but by the third day it had resolved to the stage of being simply a white streak in the centre of a darker area of skin. It was difficult to locate the injured area after day 10 and between days 21 and 28 new scales were observed at the healing position. The clipped dorsal fin used as a marker was regenerated within 10 to 16 days. The area of the repaired skin was, however, relatively easy to locate by use of the dropped lateral line indicator. However, repaired skin tended to slough off, while the fish was being handled, unless great care was taken.

### Histopathology

#### 15 minutes

In the lesion after 15 minutes, the principal feature was a large focus of haemorrhage which filled the defect from the depths of the muscle to the surface. A significant point was that the major part of the exudate was comprised of red blood cells, but at the outer edges and the edges of the dermal part, white cells predominated and these appeared principally to be thrombocytes (Fig. 4).

The epidermis at a distance from the lesion was noticeably thinned and the numbers of cells of a glandular nature was reduced as the defect was approached, so the epidermis seemed composed almost entirely of Malpighian cells with considerable evidence of cellular oedema. Small amounts of melanin pigment were also taken up within the cells. The oedematous rim of cells, which was thicker than the more peripheral layer, very dramatically gave way to an area of disorganisation of the epidermis and then a single celled tongue of epidermis moving into the defect.

The dermal change was most obvious, peripherally, as an area of change in the melanocytes, where they became rounded and irregular, with some incontinence of melanosomes. This was accompanied by hyperaemia of local capillary vessels and oedematous change of the stratum spongiosum. At the site of the lesion cleft, degenerating scale bed epithelium was often seen. The cut edge of the compactum of the dermis was

very sharply defined. Attached to the darkly staining necrotic edge of the lesion were strands of degenerating nuclear DNA.

The hypodermis was distinguished principally by the hyperaemia of its vessels, which at the edges were still bleeding into the haemorrhagic focus in the centre of the defect.

Muscle changes, restricted to the edges of the lesion, were purely degenerative. Sarcoplasmic changes comprising flocculent degeneration or even complete disruption and loss of sarcolemmar outline were accompanied by karyolysis of the nuclei. Although intact nuclei were occasionally found in a central location, it was not considered that central nuclear migration was a feature at this stage. There was marked haemorrhage into this degenerating muscle and at the base of the haemorrhagic wedge as well as at the surface (see above). There was a marked accumulation of thrombocytes and associated fibrinous exudate. It was very obvious that muscle changes were limited in lesions of this size, to a single myotome, and the inter myotomal fascia provided an obvious limit to such muscle changes.

It was a feature of those wounds where scales were not displaced or removed at the time of wounding, that the lesion was smaller, and the movement of scales, in concert with dermal contracture, allowed the edges of the wound to move closer and migratory healing of the epidermis was more easily achieved.

### 30 minutes

After 30 minutes the pathological picture was rather similar to that at 15 minutes post wounding, except that the fibrinous exudate was more formed, with a strong predilection for the edges of the lesion, where the congery of fibrin and thrombocytes appeared to act as a surface cover preventing further tissue fluid loss into the wound (Fig. 5).

The epidermal migration was continued and often the inward migrating tip of epidermis was observed to use the fibrin as a substrate for its migration. The muscle damage was similar to that found at 15 minutes, it had not degenerated further, but occasional very engorged, hyperaemic, blood vessels were seen in the area of muscle at the base of the wound.

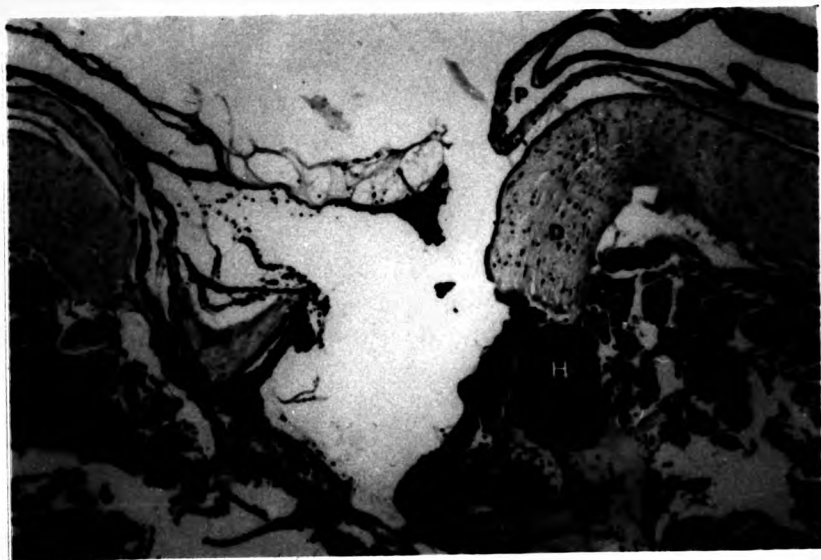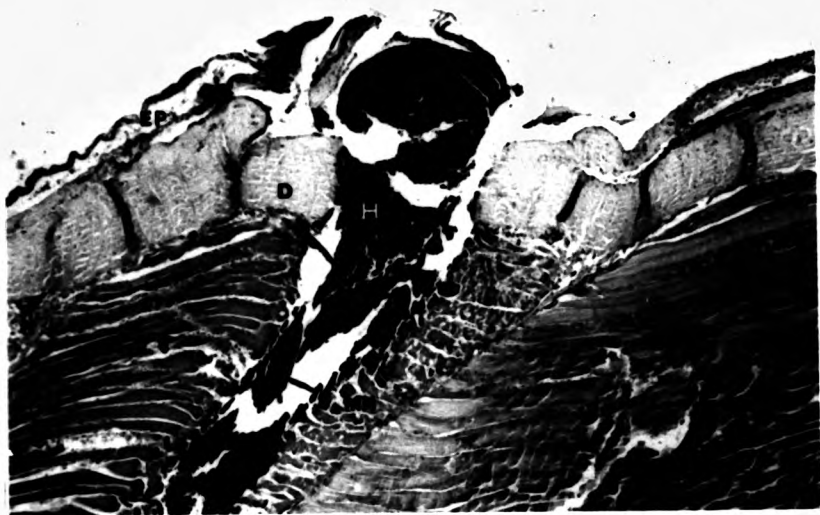
### 45 minutes

The picture, at 45 minutes, in the lesions sampled, was that of organisation and consolidation. The fibrin was now layering the edges of the ruptured myofibrils, and the epidermis actively migrating over its surface. The other particular feature was that the area adjacent to the damaged muscle was much more cellular than before and although no myophagia was to be seen, the cellularity was such as to suggest that it was imminent. Adjacent blood vessels were very large and diapedesis could be observed.



**Fig. 4** The picture of wounded skin at 15 minutes after the incision, showed marked haemorrhage (H) and muscle necrosis (MN). (H & E) X 200  
E = epidermis, D = dermis

**Fig. 5** The fibrinous exudate (arrow) was formed at the wounded site by 30 minutes after incision. (H & E) X 200  
E = epidermis, D = dermis, H = haemorrhage



### 1 hour

At one hour the situation was very similar to that at 45 minutes. The cellularity of the damaged muscle area was increased, the epidermis was migrating further down the wound ( Fig. 6), and fibrin was more obvious as a limiting membrane to the lesion. There was initiation of myophagia and also obvious new capillary growth into the lesion.

### 2 hours

At two hours epithelialization was complete although the layer of cells at the centre was very thin and the adjacent rim of epithelium thickened and hydropic (Fig. 7). Myophagia was still not marked (Fig. 8).

### 3 hours

At three hours the covering pelage of epithelium had thickened up and at the centre consisted of large pink staining Malpighian cells with a very few associated mucous cells (Fig. 9). Another feature was the occurrence of significant numbers of unusual epidermal cells, in the thickened rim around the newly covered area. They had a basally located darkly staining nucleus and an irregular hyaline cytoplasm which occasionally appeared to be granular. They were not normally found in normal areas of epidermis. There were occasionally very obvious foci of pinocytosed melanosome clusters in the Malpighian cells.

The upper dermis was oedematous with very evident hyperaemia and increased cellularity (Fig. 10).

Fig. 6. Epidermal cells were migrating (arrow) down into the depth of the wound by 1 hour. (H & E) X 200  
D = dermis, H = haemorrhage

Fig. 7. By 2 hours after the incision, the epithelialization was completed. (H & E) X 200  
EP = epidermis, D = dermis

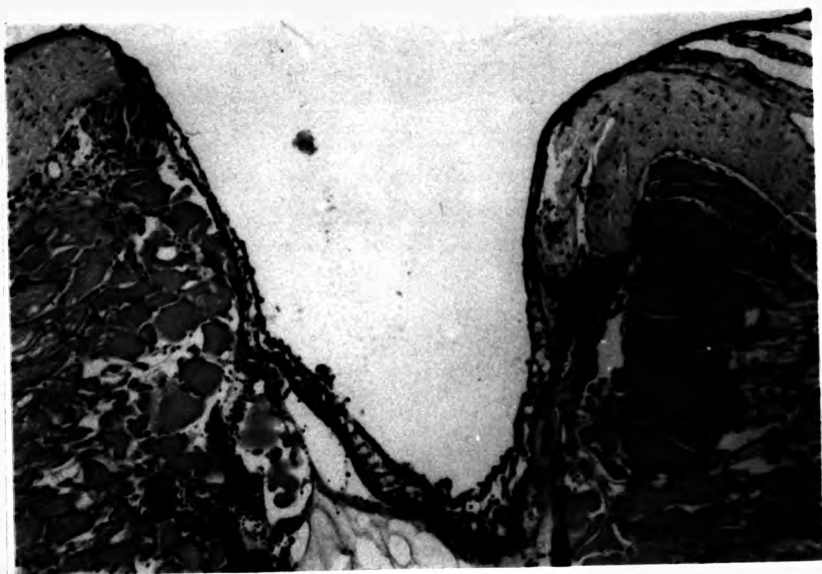
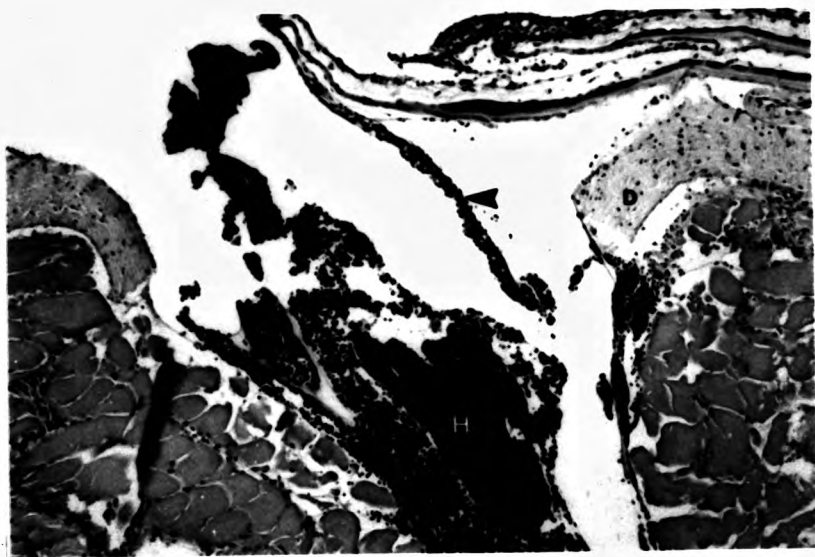
Fig. 8. The picture of muscle fibre degeneration (MN) with some haemorrhage at 2 hours. ( H & E) X 800

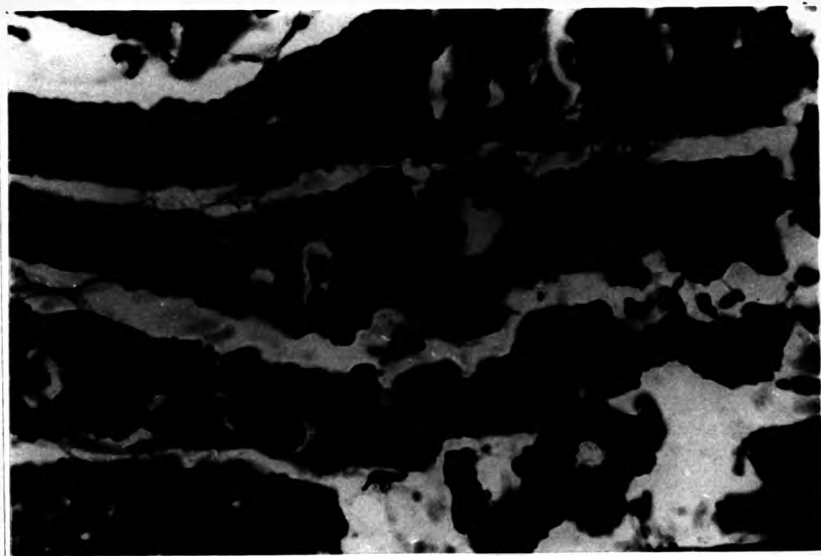
Fig. 9. By 3 hours after wounding, the thickened re-joined epidermis (EP) covered the area of the defect. ( H & E) X 375 D = dermis



**Fig. 10** The inflammatory dermis at 3 hours after wounding showed hyperaemia and melanin containing cells (arrow). (H & E) X 800

**Fig. 11** The degenerated muscle bundles at 3 hours after the incision showed myophagia. (H & E) X 800





The muscle was being strongly infiltrated with macrophages, active myophagia taking place throughout the areas of sarcoplasmic degeneration (Fig. 11), while there was significant ingrowth of buds of capillaries into the area of activity.

#### 4 hours

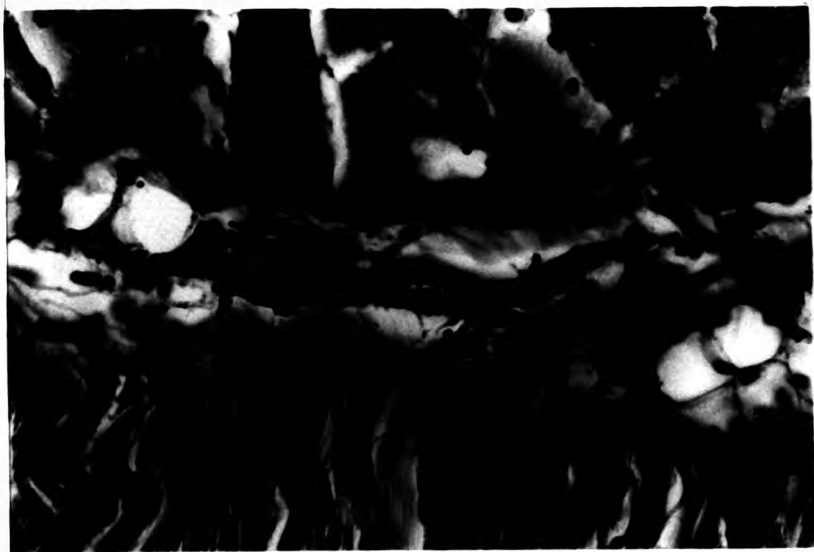Epithelial cover was further modified with an increase in the mucous cell component of the epithelium over the wound and further preponderance of the eosinophilic cells which accompanied them. Capillary activity was also very much increased, the new capillaries appearing to develop and extend along the edges of myofibrils. Myophagia was active but there was still a very large area of redundant sarcoplasmic debris. The red cells forming the clot were still intact but looking less like viable cells as their nuclei were losing their characteristic discoid shape and the staining reaction of the cytoplasm was more orange.

#### 5 hours

At five hours the role of the fibrin thrombocyte layer as a cover for the cut surface of the wound was very obvious as it condensed and became a dark basophilic surface over the edges of the muscle at each side (Fig. 12). There was also greater cellularity and organization of the fibrin on the underside of the epidermis in what would ultimately become the replacement stratum spongiosum. Myophagia was very active with heavy cellular infiltrates of macrophages from large adjacent

**Fig. 12. Thrombocytes in the exudate at 5 hours.  
(H & E) X 800**

**Fig. 13. This picture demonstrates the presence of  
melanin pigments in the intermyotomal fascia adjoining  
the affected myotome, 7 hours after the incision.  
(H & E) X 800**



blood vessels. Another distinctive feature of this stage was the first appearance of significant numbers of swollen pale staining fibroblasts, adjacent to blood vessels, and myofibrils.

#### 6 hours

Macrophage activity in the muscle was very active at this stage and obviously associated with extensive vascularisation both in muscle and stratum spongiosum. There was also obvious development of very active pale staining triangular fibroblasts on the edges of the areas of fibrin, and between areas of myophagia, as well as in the stratum spongiosum.

#### 7 hours

At 7 hours the blood cells within the centre of the lesion had become anoxic and much more orange in colour, with distinct separation of serum, fibrin and cellular elements. Macrophages were active in the serous component, and myophagia was also very obvious in the muscle, where lines of macrophages were found along the length of effete myofibrils. New capillaries were actively being led into the lesion area and occasionally these had ruptured (during sampling) to produce the focal intra myotomal haemorrhage, very fresh, and with red blood cells of very different staining affinity to that of the red cells in the centre of the lesion.

Evidence was seen of new fibroblast activity:- swollen cells with pale staining nuclei, in the inter-myotomal fascia adjoining the affected myotome, and it

was a feature, as in earlier specimens, that as well as being hyperaemic, the larger vessels of the septum were also very obviously associated with melanocytes (Fig. 13). This was not apparent in the other, normal, fascial areas, but whether the melanocytes were simply, expressing their inherent pigment more obviously, or it was newly accumulated pigment, was not apparent

#### 8 hours

At eight hours, the epithelium was still thicker over the lesion, although mucous cells were now more prominent in the replacement cover and it was still hydropic. Occasional macrophages laden with melanin were seen migrating through the epidermis, and also within the stratum spongiosum (Fig.14). The melanin within perivascular tissue of the fascia, and spongiosis of the epidermis were also again marked. The haemorrhage was now actively organized with degeneration of red blood cells, and active myophagia. In addition small numbers of neutrophils (PMN), were seen in the area of clot immediately subjacent to the epidermis.

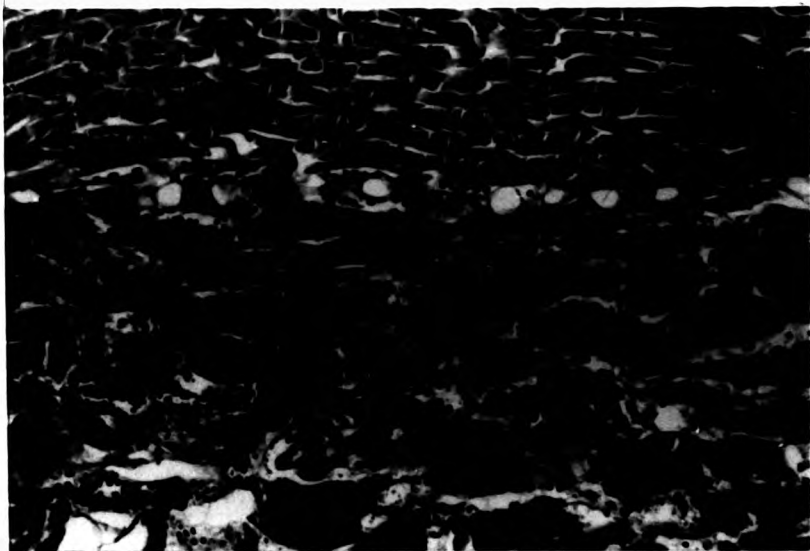
Myophagia was obvious in all areas of the sarcoplasm, where obvious damage had occurred, but was particularly active near engorged capillaries, which also contained large numbers of white cells, as well as red cells(Fig. 15).

#### 9 hours

The picture at 9 hours resembled that at eight. There was the very obvious development of a melanin

Fig. 14. By 8 hours after the incision macrophages (MC) containing phagocytosed melanin were migrating through the stratum spongiosum. (H & E) X 800

Fig. 15. By 8 hours after the incision focal nodular polymyositis was present. (H & E) X 375





layer immediately below the basement membrane of the new epidermis (which was still obviously hydropic) (Fig. 16). In addition there was clear evidence of argyrophil or collagen fibre development in the spongiosum immediately below the new membrane, with strong, active, fibroblast presence.

#### 10 hours

At ten hours there was little difference from the picture at nine hours except that myophagia was nearing completion, so that the area of muscle damage appeared smaller, and myofibrils which had been only lightly damaged had started to redevelop their peripheral nucleation and a more consistent, if still somewhat darker, staining reaction. Small deeper staining new muscle buds were also seen in small areas where myophagic debridement was completed.

#### 12 hours

At twelve hours the principal difference from ten hours was the greater frequency of small early myofibrillar regeneration foci.

#### 24 hours (1 day)

At twenty-four hours the healing was well under way, with still active myophagia of muscle and clot debris, but obvious buds of myofibrils and fibroplasia also contributing to a picture of greater organization. The epidermis was now fully supplied with mucous cells, though the eosinophilic component of the epidermis was

Fig. 16. By 9 hours after the incision an obvious melanin layer (arrow) was apparent below the basement membrane of the new epidermis. (H & E) X 800

Fig. 17. The newly joined epidermis at 24 hours after wounded showed intra and inter cellular oedema and the cutted dermis was not joined yet. (H & E) X 100  
EP = epidermis, D = dermis



reduced, and the inter and intra cellular oedema (spongiosis) was still as marked (Fig. 17, 18).

#### 2 days

The picture was now stabilized, with concomitant myophagia (largely complete), fibroplasia and muscle regeneration. However, there was still no evidence of dermal regeneration, and the main area of activity was at the base of the lesion.

#### 3 days

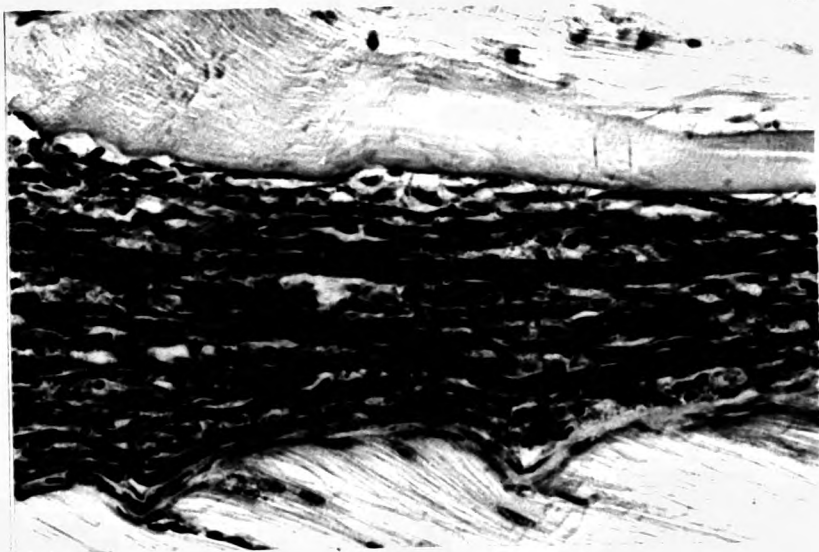
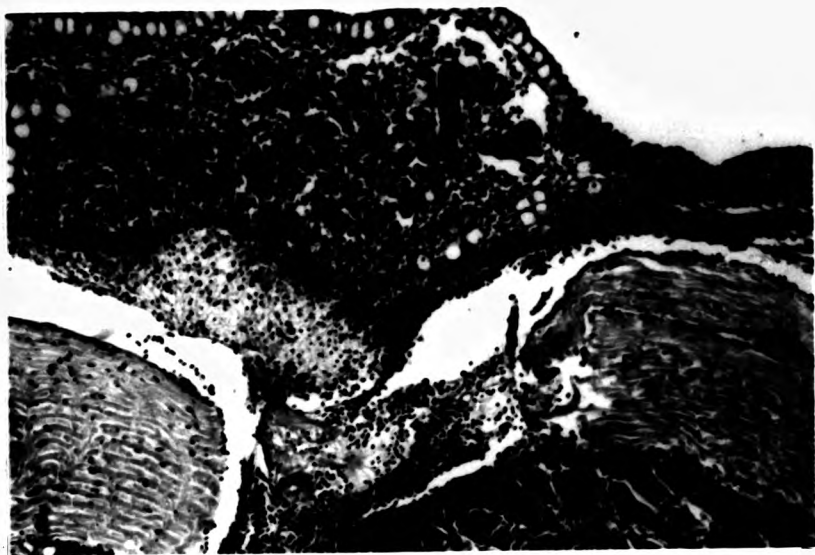
It was at this stage that for the first time fibroplasia was the most dominant feature of the lesion. This was obvious in areas where muscle debris had been phagocytosed, and also in the outgrowth, principally from the hypodermis, of fibroblasts and fibres (immature collagen) in line with the cut ends of the stratum compactum of the dermis. The fibroblasts of this tissue, were also becoming enlarged and active. In the fibrous replacement area of the muscle, considerable numbers of small muscle fibres and small basophilic muscle buds were also evident (Fig. 19). These were most obvious adjacent to an area of normal muscle, rather than in the middle of the debrided area.

#### 4 days

At this stage fibrosis dominated the picture, with extremely active collagen formation and the only significant macrophage activity being associated with large lipofuscin or ceroid containing cells scattered either among the areas of muscle-fibrous replacement

Fig. 18. The enlargement of Fig. 17 showed inter and intra cellular oedema of the epidermal cells which covered the sectioned dermis (D) and some exudate. (H & E) X 200

Fig. 19. By day 3 after ulceration the wounded area showed new muscle regeneration (arrow) within the fibrosing replacement tissue. (H & E) X 800



activity or as discrete foci or aggregates of such cells, which suggested the possible formation of ectopic melanomacrophage centres (Fig. 20). At this stage the dermis was now linked, between its cut edges, by a length of extremely active fibrous tissue, along lines in parallel to those of the collagen bundles of the stratum spongiosum (Fig. 21). This extended down to form a clear area of fibrous replacement, often involving the whole of the damaged areas of muscle. There was here an obvious mix of fibrous tissue, small areas of damaged muscle regrowing, and new muscle buds. The more active areas of fibrous replacement were also extremely vascular (Fig. 22).

#### 5 days

At five days the rejoining of the two sides of the dermis was complete, although barely demarcated from the fibromuscular granulation tissue below (Fig. 23). Above it, however, was, for the first time, obvious reformation of the scale buds within the stratum spongiosum, essential for regeneration of replacement scales to take place (Fig. 24). The epidermis was also more closely similar to that of the normal fish, but still thicker over the main lesion area.

#### 6 days

The connective tissue lesion had, by this time, started to demarcate into dermis and myo-fibrous tissue, with new muscle fibres no longer sinuous but straight, and only slightly basophilic staining. The junction

Fig. 20. Macrophages with lipofuscin in the cytoplasm (arrow) found within the area of fibrosis by day 4. (H & E) X 800





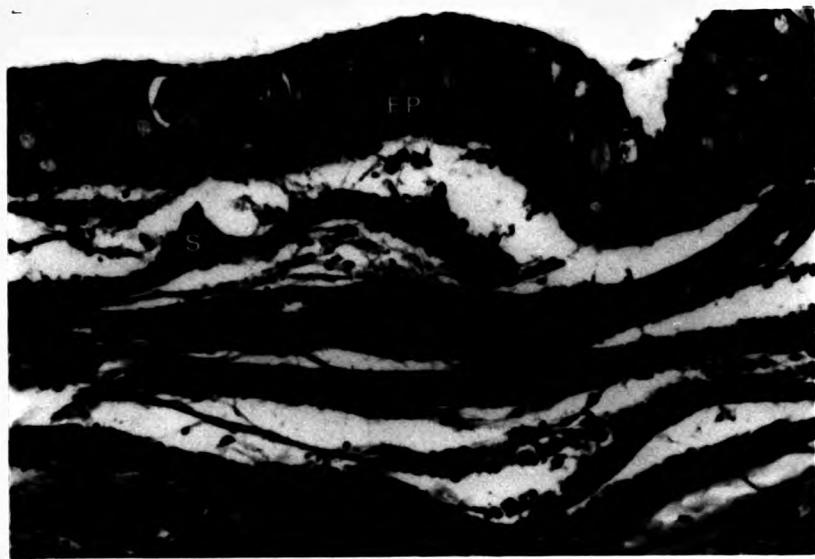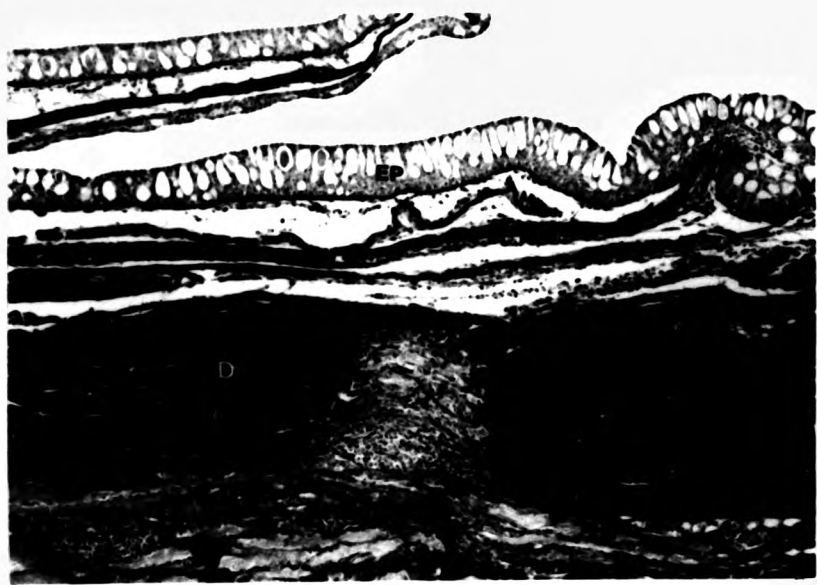
**Fig. 21.** The healing lesion at day 4 demonstrating the active fibrous connective tissue (arrow) joined the ends of sectioned dermis (D). (H & E) X 80 E = epidermis  
S = scale

**Fig. 22.** Active fibrosis (arrow) and vascularization (V) were found in the healing lesion by day 4. (H & E) X 800



Fig. 23. By day 5 after wounding the dermis (D) was almost completely re-joined by fibrous connective tissue. (Van Gieson) X 200 E = epidermis, S = scale,

Fig. 24. The scale bud (S) reformed in the stratum spongiosum around day 5 after the incision. (H & E) X 400 EP = epidermis



collagen tissue was already less actively cellular and vascular than at day five, and new scale beds less darkly staining and amorphous. The phospholipid absorbing macrophages, laden with lipofuscin and ceroid, were extremely obvious, and lined up along the length of new muscle fibres in a number of sites. The overlying epidermis was virtually normal.

#### 8 days

On day eight the growth of myofibrillar elements into the granulation tissue was obvious, and the stratum compactum junction more fibrosed and dense, but the most obvious area of activity was now the stratum spongiosum, which had a very active fibrous tissue activity, serviced by a very distinctive and extensive capillary development. One obvious feature was that the scale bed cells which were apparent as an organised layer from day five, were now actively elaborating scale material, which was being laid down above the dermal defect and extending across the fibrous junction between the two parts of the stratum compactum.

#### 10 days

The rapid progress of the muscular and dermal regeneration led, by day ten, to both muscle and dermal integrity, across the area of the defect, being complete. The new scale growth was also near completion. The epidermis was normal and the red granular cells had disappeared from the outer layer.

Melanin and ceroid containing cells were still

present, but generally aggregated into focal accumulations which were adjacent to blood vessels.

#### 12 days

The fish examined at this time, all showed characteristics of myofibrillar extension across the defect, scale renewal and fibrillar connection of the dermal ends.

#### 14 days

Newly regenerated muscle comprised more than half of the defect, with a considerable reduction of the connective tissue and particularly cellular component. New scales were well formed and the stratum spongiosum, while still more oedematous and cellular than the normal, was also developing properly melanocyte structures (Fig. 25).

#### 21-28 days

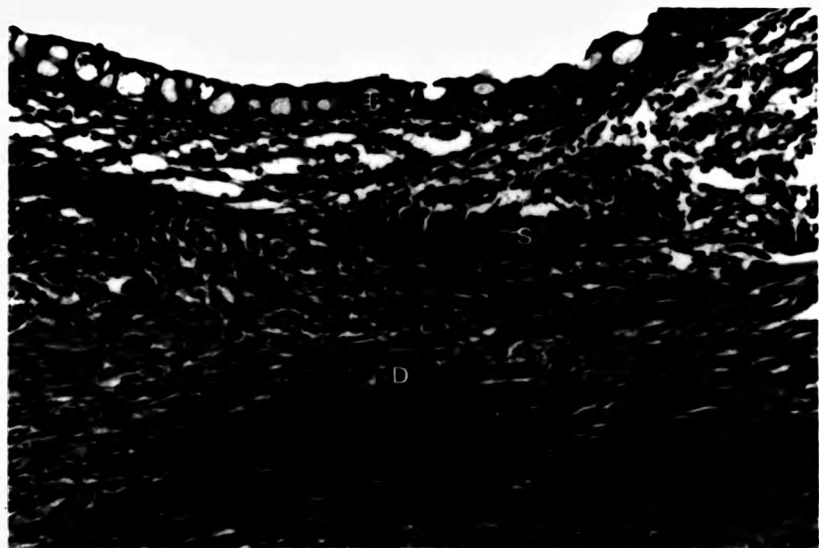
The epidermis and dermis were fully developed. and scales rearranged in their original position. The new muscle bundles filled almost all of defect but some fibrosis was still observed (Fig. 26)

A summary of changes seen is given in table 2.

Fig. 25. By day 14 after the incision the dermis (D) was completely joined and new scales (S) were formed. (H & E) X 400 EP = epidermis

Fig. 26. By day 21 after wounding new muscle bundles extended throughout the defect. (H & E) X400





**Table 2. Histology of skin repair and the cellular inflammatory response to skin wounds in snakehead.**

<b>Time after wounding</b>	<b>State of repair of the wound</b>	<b>Cellular inflammatory response in wound healing</b>
15-45 min.	A thin epithelial cell layer migrated over the fibrinous exudate	Thrombocyte and erythrocytes in the exudate, hyperaemia, haemorrhage and diapedesis
1-2 hr.	Thin epithelialization was complete	Initiation of myophagia and macrophages
3-4 hr.	Covering epithelium thicker and increase in the mucous cells	Foci of melanosome clusters, hyperaemia, increased cellularity active myophagia, ingrowth of capillaries
5-6 hr.	Thickening of the epithelium	Fibrin thrombocyte layer covers the cut surface, active myophagia, fibroblast and active vascularization first appeared
7-8 hr.	Thicker epithelium with prominent mucous cells	Obvious myophagia, melanocytes near large vessels, and PMN
9-12 hr.	Thicker epithelium cover the healing wound	Melanin layer below basement membrane, collagen fibre development, active fibroblasts, myophagia nearly complete, new muscle buds forming
1-3 d.	Epidermis fully supplied with mucous cells	Active fibroplasia and muscle regeneration, fibroplasia dominant, myophagia complete, dermal regeneration starting
4 d.	Thick epidermis	Fibrosis dominant, active collagen formation, lipofuscin present
5 d.	Normal epidermis (slightly thick)	Dermis completely re-joined, scale bud reformation

Table 2. (continue)

Time after wounding	State of repair of the wound	Cellular inflammatory response in wound healing
6 d.	Normal epidermis	Less cellular response more lipofuscin
8-12 d.	" "	Melanin and ceroid cells present
14 d.	" "	Muscle regeneration almost complete
21-28 d.	" "	Normal-like control fish

## DISCUSSION

Observations of the gross lesion, show that the areas surrounding the wound become very dark within an hour after the infliction of the wound. The changes in colour may be due to the passive dispersal of pigments (Mittal & Munshi 1974), under neural control (Sage 1970), or else to destruction of melanophore control (Laird *et al.*, 1975). These observations were similar to what had been reported in skin wounds of catfish (Mittal *et al.*, 1978; Mittal & Munshi 1974), and salmon (Roberts *et al.*, 1971). Other workers in this field made no reference of such colour changes after the incision in fish skin (Anderson & Roberts 1975; Conant 1970; Kudokotsev & Silkina 1967; Mawdesley-Thomas & Bucke 1973; Ramachandran & Thangavelu 1969; Roberts *et al.*, 1970).

Following injury, the epidermal cells start migrating and this results in the bridging of the wound gap. One of the most interesting features of the wound healing process as described here, is the rapid process of epithelialization.

The epithelialization of the wounded snakehead was completed within 2 hours, which was very rapid in comparison with the other fish species which have been studied (Table 3). Mittal & Munshi (1974) and Hickey (1982) correlated the rate of epithelialization with the thickness of the epidermis and suggested that, if the epidermis is thick the epithelialization of the wound is quicker than that of the thin epidermis. However, these findings do not support this view. There was

Table 3. The complete epithelialization time requirement in different fish species.

Name of the fish	Time required (hr.)	References
<i>Misgurnus fossilis</i>	12	Van Oosten 1957
<i>Cyprinus carpio</i>	24	Becker 1942
<i>Cobistis taenia</i>	24	Kudokotsev & Silkina 1967
<i>Protopterus annectens</i> <i>P. aethiopicus</i>	24	Conant 1970
<i>Pleuronectus platessa</i>	9	Bullock <u>et al.</u> , 1978
<i>Salmo salar</i>	3	Anderson & Roberts 1975
<i>Rita rita</i>	4-6	Mittal & Munshi 1974
<i>Heteropneustes fossilis</i>	4	Mittal <u>et al.</u> , 1978
<i>Mystus vittatus</i>	5	Saxena & Kulshres- tha 1982
<i>Oreochromis niloticus</i>	5	Jauncey <u>et al.</u> , 1985
<i>Channa striatus</i>	2	Present study

Table 4. Thickness of the epidermis and the time required for complete epithelialization of wound in different fishes.

Name of the fish	Length (cm)	Average thickness of the epidermis (micron)	Time required for complete epithelialization (hr)
<i>Rita rita</i>	15.5	490	4-6
<i>Misgurnus fossilis</i>	18-27	339	12
<i>Cyprinus carpio</i>	13.0	100	24
<i>Heteropneustes fossilis</i>	18.0	98	4
<i>Pleuronectes platessa</i>	1-1.2 2.2-2.6	3-7 7-14	6-10 11-12
<i>Clupea harengus</i>	1.9-2.1	3-7	4-6
<i>Salmo salar</i>	2.4-2.7	7-12	4-6
<i>Channa striatus</i>	14-17	32-40	2

N.B. The influence of temperature was not specifically considered in the above work.

complete epithelialization of the wound within 2 hours in snakehead and 4 hours in catfish (Table 4), despite both of these species having a thin epidermis as compared to that of many of other fishes.

The present investigation on the epithelialization of wounds in snakehead shows that migration of epidermal cells takes place in a mass towards the wound gap and over the fibrinous exudate. At the time of migration the epidermis became very thin with elongation of the Malpighian cells. These findings support the results of the previous workers who studied wound healing in fish (Anderson & Roberts 1975; Bullock *et al.*, 1978; Hickey 1982; Mittal & Munshi 1974; Mittal *et al.*, 1978; Phromsuthirak 1976).

It has been agreed by many workers that the process of epithelialization takes place much more rapidly in fish than in mammals and other vertebrates (Bullock *et al.*, 1978; Mittal & Munshi 1974; Mittal *et al.*, 1978;). This quicker rate of epithelialization in fish is possible, in part at least, because of the fact that they remain in water and secrete mucus, and so the wound invariably remains moist. This is supported by the observations that the epithelialization of mammal skin in moist conditions is comparatively much faster than in the terrestrial condition (Krawczyk 1971; Rovee *et al.*, 1972). Winter (1964) suggested that on a dry wound the movement of epidermis is impeded by the fibrinous clot which lays in its path, but on moist wounds the epidermis moves through the exudate above the fibrous tissue. Keeping

this in view, in fish, where the wound always remains moist, the quicker rate of epithelialization may be readily explained.

According to the previous work on wound healing in fish ( Table 3 ), the rate of epithelialization in snakehead skin seems to be faster than in the others. This may indicate that the ability to heal wounds among fish species may vary depending on their own physiological defence mechanism. The ambient temperature would certainly be one of the factors that are involved with the rate of epithelial migration in fish (Anderson & Roberts 1975; Bullock *et al.*, 1978; Roberts *et al.*, 1971). Stress appears to have less influence on the rate of wound healing than temperature (Anderson & Roberts 1975).

The rapid epidermal covering of wounds must have major survival advantages in the aqueous environment. Quick epidermal coverage is an obvious factor in helping reduce fluid, protein and ion loss by outflow and osmosis from wounds and also in limiting the entry of potential pathogens. The early appearance of mucous cells within the healing epidermis may be of significance in that antibodies have been found in mucus (Bradshaw *et al.*, 1971; Fletcher & Grant 1969; Fletcher & White 1973; Harris 1972; Hjelmeland *et al.*, 1983; Ourth 1980). The abrupt secretion of a mucus-like gel after wounding may also increase and promote the rate of wound healing ( Al-Hassan 1983; Al-Hassan *et al.*, 1985). They also showed that the rate of healing in man can be improved when such material of piscine origin is applied



to wounds in man. The quicker rate of epithelialization in fish may also be correlated with the slower formation of granulation tissue compared with mammals (Mittal & Munshi 1974).

Macrophages were first seen between 1-5 hours after wounding, within the myopathic area in the first 2 hours and at 4-5 hours were found in the damaged dermis. By the third hour the number of macrophages was distinctly increased in number and the myophagia began to take place throughout the area of muscle degeneration. This was much faster than had been reported by the previous workers. Large numbers of macrophages were accumulated within the wound of Nile tilapia by 10 hours after the incision (Jauncey *et al.*, 1985). Phromsuthirak (1976) found the maximum number of macrophages in day 3 after wounding of the three spined stickleback, while Anderson & Roberts (1975) and Saxena & Kulshrestha (1982) reported the macrophages were first found within 24 hours after the incision in salmon and mystid catfish respectively. Five days was the latest recorded in finding macrophages in the wounded area, which was reported by Hickey (1982) in plaice larvae. The macrophages in the present study completely disappeared from the area of defect around day 6-12 which was about one week faster than the result from the studies of Anderson & Roberts (1975) (16-18 days).

Anderson & Roberts (1975) reported myophagia in salmon to be present at 24 hours but Timur M. (1975) found myophagia within 3-5 days after injecting

carrageenin into plaice muscle. On the contrary myophagia was nearly complete in 10 hours after injury in the present study.

The enlargement of lymphatic space which filled with lymphocytes in the epidermis of snakehead observed in this study, was similar to the report of Mittal & Munshi (1974) and Mittal *et al.*, (1978) who worked with catfish. The gradual enlargement of the lymphatic spaces with the simultaneous increase in the number of lymphocytes after the injury for considerable periods, may be an immunological reaction of the local defence mechanism. (Mittal & Munshi 1974 ; Mittal *et al.*, 1978).

Small numbers of polymorphonuclear leucocyte cells were found, in the present study, in the area of clot near the epidermis, by 8-12 hours after wounding. Phromsuthirak (1976) and Ramachandran & Thangavelu (1969) recorded the PMN in the dermis near the edge of the wound and among the migrating epithelial cells at 1-3 hours and Phromsuthirak also mentioned that the number of PMN increased to a peak within 24 hours after wounding. PMN have never been reported to be significant in the process of wound healing by other workers (Hickey 1982; Mittal & Munshi 1974; Mittal *et al.*, 1978 ; Saxena & Kulshrestha 1982). Few PMN were present at 48 hours in Anderson & Roberts's work on wound healing in salmon. The occurrence of PMN in the striped snakehead was slow in comparison with the report of Phromsuthirak (1976) and Ramachandran & Thangavelu (1969), but they were nevertheless a lot faster in appearing if compared with the

work of Anderson and Roberts (1975).

The PMN were not obviously phagocytic in the wound. This is similar to the report of Phromsuthirak (1976), but a number of previous reports of fish neutrophils being phagocytic have come from Davies & Haynes (1975); Finn & Nielson (1971 b); Watson *et al.*, (1963); and Weinreb & Weinreb (1969). The early arrival of large number of neutrophils in wounds of mammals provides an effective local barrier against bacterial invasion (Simpson & Ross 1972; Viziam *et al.*, 1964). This explanation may be used in this experiment in that small numbers of PMN were observed only at the early stage after wounding. They did not remain, but then the wounds did not get infected. The difference in time scale of PMN appearance in wound area may be due to either a species difference in defence mechanism or the ambient temperature.

Fibroblasts first appeared within 3 days in the defect area of the various species of tropical fish e.g., freshwater catfish (Mittal & Munshi 1974; Mittal *et al.*, 1978; Saxena & Kulshrestha 1982;), snakehead (Ramachandra & Thangavelu 1969), three spined stickleback (Phromsuthirak 1976), and Nile tilapia (Jauncey *et al.*, 1985) had been recorded. Anderson & Roberts (1975) found the active fibroblast in their experimented salmon in 2 days after injury. Fibroblasts did not show in wounds in plaice larvae (Hickey 1982) until day eleven after the incision but this may be a function of the size and immaturity of larvae.

The fibroblasts were present but only in a very inactive form at 4-5 hours in the snakehead lesion of this study which is nevertheless a very rapid rate of fibroblast forming in comparison with the other fish species. Granulation tissue was clearly evident within 1 day and developed to a peak at 3-5 days. This granulation tissue had been replaced by the new muscle fibre bundles within 4-14 days.

The myofibrillar regeneration was present in the form of sarcoplasmic budding among the fibrosis area within 8-12 hours after wounding. This is the fastest rate of budding ever recorded in fish. From the previous studies the muscle fibres regeneration time varied from 4-8 days after wounding ( Anderson & Roberts 1975; Juancey et al., 1985; Mittal & Munshi 1974; Mittal et al., 1978; Ramachandran & Thanglavelu 1969).

Finn & Nielson (1971a), Roberts et al., (1975) and Mawdesley-Thomas & Bucke (1973) failed to record sarcoplasmic budding or muscle fibre regeneration from their experiment on the healing process in salmon and goldfish, respectively. These may well have been because they did not keep the fish alive sufficiently long after initiation of the wound (Timur M. 1975).

The rate of muscle regeneration was very much correlated with the temperature. Anderson & Roberts (1975) found that sarcoplasmic regeneration was present within 4-7 days at 23° C and 8-38 days at 5° C.

Regeneration of muscle tissue may be related to the species of the fish, as Sakanari and Moser (1986)

reported that the regeneration of the muscle tissue of striped bass, *Morone saxatilis* (Walbaum) did not occur although the wound completely healed externally (22 months). This seems most unlikely.

Necrotic muscle in snakehead wounds was all removed, and debridement completed 6-7 days after incision.

The reformation of the scale buds within the stratum spongiosum of snakehead first appeared at day five and the scales were well formed within 14 days. Anderson & Roberts (1975) reported in their studies in salmon wound repair that scale regeneration first become evident at the wound edge at 10 days, and within the wound by the twenty second day.

Melanin pigments were present in the epidermal cell within 4-5 hours and in the necrotic muscle fibre area by 6-7 hours. The lipofuscin accumulation developed in conjunction with the melanin containing cells by day three. In salmon the melanin pigments were observed in the wound area within four to six days, which was similar to the reported of Anderson & Roberts (1975) and Mittal and his co-workers (1978) also reported the same evidence in catfish. In plaice larvae, there were nodules of melanin in the wounds after 20-30 days of the injury (Hickey 1982).

The principal sites of melanin-containing cells in normal fish are; the stratum spongiosum of the dermis; the hypodermis; the haematopoietic tissue of the spleen, kidney, and liver; and small foci along blood and lymph

vessels (Roberts 1975a). In wounded skin, whether caused by predators or in the process of tagging, the melanosomes released from the damaged pigment cells are engulfed by macrophages. These may migrate through the epidermis of the healing lesion, dehiscing on the surface (Roberts 1975a) or accumulate in melanomacrophages within the tissues. Melanin is often associated with lipid residues from the breakdown of cell membranes (Edelstein 1971). The metacercariae of certain digenean parasites, which encyst in the skin and muscle of teleost fish, stimulate production of similarly melanized black spots (McQueen *et al.*, 1973; Stunkard 1929).

Vascularization started very early in the first two hours in the degenerating muscle area and in the third hour in the dermis, after wounding. The prominent blood capillaries had invaded the defect area by day three in litid catfish (Mittal *et al.*, 1978) and mystid catfish (Saxena & Kulshrestha 1982). Capillary invasion of the salmonid wound was observed after 31 hours, but this had disappeared 18 days later (Anderson & Roberts 1975). At about 20 hours, the edge of the subcutis of catfish received a rich supply of blood capillaries (Mittal & Munshi 1974).

In comparison with similar experiments on wound healing processes in different fish species both temperate and tropical, the rate of epithelialization and the cellular inflammatory response in snakehead is remarkably fast (Table 3). These results may in part

help to provide an explanation, as to why the snakehead is the only species surviving for any length of time during the current ulcerative fish disease outbreak in the Southeast Asia Region, while the other infected species died extremely quickly. Observations on the healing lesion of the snakehead with this condition suggest that it is very quick when the fish are placed in clean water after the infection (personal observation; Llobrera & Gacutan 1987).

The very rapid appearance of large numbers of blood capillaries in the granulation tissue must be part of the process whereby healing is so rapid and the active migration of leucocytes which may act as an efficient protective barrier preventing the absorption of toxins and the penetration of bacteria into the underlying tissues. Such rich vascularization in the defect area may also be correlated with supplying the various nutrients efficiently for the actively proliferating cells in the wound region.

**CHAPTER 3: CHRONIC INFLAMMATION IN THE STRIPED SNAKEHEAD**



## INTRODUCTION

The physiological mechanism in animals for protection against infection and the prevention of alteration in internal homeostasis can be either a non-specific, natural defence, which is an inborn mechanism rendering the host resistant to infection or an acquired, specific process which is induced directly in response to a particular foreign agent. Non-specific defence mechanisms comprise a multitude of factors which prevent infection occurring, limit its spread or else remove the cause of host tissue damage, but they do not have a memory component and the response is similar irrespective of the stimulus. The non-specific system of defences is exemplified particularly by the fixed phagocyte and inflammatory responses. The inflammatory response in particular may differ significantly between fish and higher vertebrates (Ellis 1981), although present evidence suggests that the underlying basis is similar.

A pathological phenomenon known and studied from ancient times, inflammation has long been defined as the reaction of the tissues to an irritant. The definition proposed by Ebert (in Zweifach et al., 1965), is "Inflammation is a process which begins following sublethal injury to tissue and ends with complete healing".

## REVIEW OF THE LITERATURE

### INFLAMMATION

The inflammatory response is the basic protection mechanism to tissue damage of whatever cause; e.g. traumatic wounds, irradiation wounds, bacterial or viral mediated injury, parasites, and chemical or toxic damage. It is a relatively non-specific response which may be initiated by a variety of physical, mechanical or immunological means. These responses have much in common, no matter what the original stimulus (Winter 1964).

The main requirements for the development of an inflammatory response are that the basic structural integrity of the tissue concerned is maintained despite the injury or insult and that a functional blood supply is maintained (Roberts 1975b). Acute inflammation the first to occur in response to most stimuli, is characterized by a sudden onset and a short duration inflammatory process. Often it may be complete within a few hours and it progresses rather promptly within a matter of some days or, at most a few weeks to recovery or else to the stage of chronic inflammation or death. The inflammatory process, particularly when acute, is primarily a circulatory phenomenon involving changes in the amount and quality of blood reaching the affected area, but there is no proliferation (Smith & Piper 1972).

It is initiated by the action of vaso-active amines released by the initiating stimulus on the microcirculation of the area. These cause increased

blood flow into the area and at the same time the capillaries of the area dilate and the capillary fenestrae increase in diameter, allowing serum protein molecules such as fibrinogen and white blood cells to pass through to the tissues. The degree of cellular migration depends to a considerable extent on the nature of the stimulus (Roberts 1975b).

In any simple wound, most of the immediately consequent tissue responses are related to the formation of an inflammatory exudate. During the early phase of the inflammatory process, the predominant cell in all exudates is the neutrophil. As the inflammation progresses, however, the neutrophil process is replaced by the mononuclear cells. If the inflammatory process is prolonged, lymphocytes may eventually become quite numerous. Acute inflammatory processes may terminate in healing or death, or they may continue as either subacute or chronic inflammations (Cappel & Anderson 1971).

If an acute inflammatory lesion does not resolve quickly, then chronic inflammation, characterized by vascular proliferation of neighbouring support tissue, fibrosis, and by influx of mononuclear cells such as lymphocytes and plasma cells, develops.

Chronic inflammation, with development of a proliferative lesion which progresses to fibrosis, is called a granuloma and is a small, hard, white to yellow lesion which may have a cheesy consistency or be harder or even calcified (Roberts 1975b). Granulomatous inflammation is characterized by the infiltration of the

lesion by phagocytic cells. These may align themselves together to form arrays of epithelioid cells or actually fuse their cell walls to form giant cells.

One of the best studied experimental models of the chronic inflammatory response in fish has been the Freund's complete adjuvant injection.

#### THE INFLAMMATORY RESPONSE IN FISH

The inflammatory response was first demonstrated in fish by Metchnikoff (1891) who studied fish as well as other lower vertebrates to underscore his studies on higher animals, and showed that in its fundamentals the process was similar to that known in higher animals (Metchnikoff 1891; Finn & Nielson 1971 a,b). However, the inflammatory response in fish does differ from the response in mammals in some important points e.g., the response is generally not as well contained in fish, pus formation does not generally occur, frequently there is extensive liquefaction of surrounding host tissue and the rate of response is temperature dependent (Ellis 1981).

Experimental studies on the chronic inflammatory response in teleost fish have been done in plaice (Ferguson 1975; McQueen *et al.*, 1973; Timur G. 1975; Timur G. *et al.*, 1977; Timur M. *et al.*, 1977), trout (Finn & Nielson 1971 a,b; Post 1963; Sohnle & Chusid 1983), salmon (Roberts *et al.*, 1973 a,b; Prazdnikov & Mikhailova 1968), and many other fish species (Suzuki 1986).

## EXPERIMENTAL INFLAMMATION IN FISH

A range of different types of traumatizing material has been used to induce the inflammatory response in fish. Sterile inflammation in fish has been induced by the intraperitoneal injection of turpentine (Reznikoff & Reznikoff 1934; Weinreb 1959).

Post (1963) reported that an intramuscular injection of Freund's complete adjuvant and killed *Aeromonas hydrophila* caused an extensive inflammatory reaction in trout. He could not demonstrate phagocytosis of *A. hydrophila* either in the blood stream or in the peritoneum but was able to demonstrate it in splenic impressions from fish dead of an overwhelming peritoneally induced injection. He did not describe the actual inflammatory lesion, however.

Yamada (1964) noted that the wound caused by removing the scales of goldfish often filled with a hyaline plasma after a few days of injury. In healing, regenerative cells flowed into the wound from the marginal connective tissue to form a loose layer or cutis.

Prazdnikov & Mikhailova (1968) in a follow up to the work of their illustrious predecessor Elie Metchnikoff, have described the reactions of pre-larval humpback salmon, *Oncorhynchus gorbusha* (Walbaum) to the introduction of threads soaked in carmine and various bacteria. Phagocytosis by cells of the periosteum, epithelium and the endomysium occurred. Although blood cells including polymorphonuclear leucocytes appeared occasionally in the wound, they were observed to take

little part in phagocytosis. Their work illustrated in their view that the phylogenetically oldest defensive reactions were those related to the reticulo-endothelial system in contrast to the later acquired myeloid cells.

Wolke & Trainer (1971) described foreign body and Langhans type giant cells in granulomatous enteritis in the white sucker, *Catostomus commersoni* L. associated with the presence of diatoms (Chrysophyta) in the intestinal submucosa.

Finn & Nielson (1971 a,b) investigated the basic responses of rainbow trout, *Salmo gairdneri* Richardson to inflammatory agents; unemulsified, complete Freund's adjuvant; heat killed *Staphylococcus aureus* and electric heat. They found that the macrophages were capable of engulfing many more bacterial bodies than were the polymorphonuclear leucocytes (PMN). The PMN was usually present after 12 or 24 hours and the macrophage response after 1 day. The lymphocytes and thrombocytes were present as a background type of cell rather than playing an active role. The necrotic tissue was replaced by fibrous granulation tissue between the 8th and 16th day.

They indicated that the perimysium plays three important roles in the inflammatory process of fish muscle. It acts as a retaining barrier in limiting the spread of a noxious agent, it carries in it large vessels responsible for many infiltrating leucocytes and it appears to be a source of fibrocytes and fibroblasts. They concluded that the inflammatory phenomena in fish

were closely comparable with those of mammals but that the cellular responses were considerably delayed and were probably quantitatively less than in mammals. They did not however emphasize the importance of temperature to the rate of response.

The traumatic lesion induced by the insertion of the plastic fish marking tag was used by Roberts and his colleagues (1973 a,b) to study the inflammatory response within the tissue of the Atlantic salmon over a very long time. (Salmon may carry such tags for 2 or 3 years, Roberts personal communication). The cellular response within the exudate and around vessels at the early stage lesion consisted mainly of macrophages with a few polymorphonuclear leucocytes. A firmly established network of fibro-granulation tissue was extant later. The muscle lesion reached maturity at 25 days when it consisted of follicular granulomata with multinucleated giant cells of foreign body type. Probably because of the recurrent nature of the trauma, associated with tagtrace movement, the healing of the muscle fibres was never particularly noticeable and replacement fibrosis was the dominant long-term response in the muscle necrosis area. The most frequent cell seen in the longer term in the loose fibrous tissue was the eosinophilic granule cell (E.G.C.). The other cells which were greatly in the evidence in the lesion in fish tagged over one year were melanin containing cells.

Corbel (1975) reviewed the information on the cellular response in fish to the effects of viruses,

where it seems that the response appears to vary considerably with the infectious agent and in many instances no evidence of an inflammatory response could be detected. The cellular response to mycotic infection also appears quite varied, ranging from tubercle formation to complete absence of response. Parasitic infection by protozoa and metazoa appears to evoke a more definite response, with walling off by fibrous tissues as a characteristic feature. Enclosure of the parasite by granulation tissue may succeed an inflammatory response involving neutrophils and macrophages.

Timur G. (1975) studied the development of giant cells and granuloma in response to inoculation of complete Freund's adjuvant, beryllium oxide, *Mycobacteria* and talc in plaice and she found that the cellular inflammatory reaction consisted of a few neutrophil leucocytes, occasional lymphocytes and the major cellular component of the exudate, the macrophages. Two types of giant cell, Langhans and foreign body, were observed in the chronic granulomata in plaice. The presence or absence of *Mycobacterium butyricum* from the adjuvant did not affect production of both types of giant cells but there were significantly fewer lymphocytes and plasma cells seen at all stages in incomplete adjuvant as compared with complete adjuvant. The epithelioid cells were arranged in a whorl like pattern, as discrete focal accumulations among the inflammatory cells. She also found that the muscle regeneration started at the periphery of the granuloma.



Timur M. (1975) studied the granuloma in the plaice induced by carrageenin, which is a seaweed extract commonly used in studies on chronic inflammation. He observed the plasma cell and its precursors within the developed granulomata. He also reviewed the literature on the inflammatory response both in mammals and fish.

Wrathmell & Parish (1980) have demonstrated the absence of antibody and complement activation (C3) receptors on fish phagocytic cells and have found no evidence for the opsonic effect of antibody and complement in fish inflammatory responses.

Ellis (1981) has reviewed the inflammatory response in fish and suggested that the inflammatory events in fish may be much less sophisticated than in mammal. If the inflammatory response fails to destroy the pathogen, the reaction subsides and a connective tissue encapsulation response ensues which may become calcified. One reason for this view that the inflammatory exudate may not be so important for the fish is that their ability to regenerate tissue is much greater than the mammal.

MacArthur and his co-workers (1984) reported that the injection of oyster glycogen or live *Vibrio alginolyticus* produced an acute inflammatory reaction in the plaice. It was concluded that the accumulation of neutrophils and mononuclear phagocytes was due to cellular infiltration rather than multiplication of cells in situ since monocytes were identified in the peritoneal cavity at the peak of the reaction. They confirmed that

*Vibrio* provoked a much more intense and prolonged cellular inflammatory reaction than the oyster glycogen. They also indicated that the acute inflammatory response in plaice is a slower process than that found in mammals, although the magnitude of the response appears similar. They concluded that since stress was found to play an important role in depressing the accumulation of inflammatory cells, deleterious effects on resistance to infection might be expected to occur where stress inducing environments exist, such as in fish farming.

#### CELLS INVOLVED IN THE TELEOST INFLAMMATORY RESPONSE

Any histological study of the inflammatory response in fishes has to consider the problems of identification of the different cells which are found in such lesions. Often there is some degree of difficulty in relating function and tinctorial properties of cells in individual fish species to those of clinical mammalian pathology.

##### Macrophages

The macrophage is a mononucleated cell, derived from circulating monocytes, which adheres to glass and plastic, is characteristically highly phagocytic or pinocytic (Laskin & Lechevalier 1972; Volkman & Gowans 1965 ). Macrophages are widespread in tissues of teleosts including gills and peritoneum, but are mainly found as reticulo-endothelial cells in the kidney, spleen and in some fish, the atrium of the heart (Ellis 1977, 1982).

The size of macrophages is very variable depending on species and state of digestion of any ingested material. The diameter is 6-20 micron in plaice (Ellis 1976; Timur G. *et al.*, 1977; Russell 1974), and 15-21 micron in tilapia and carp (Suzuki 1986). The surface is irregular and in section they may be seen to show finger-like pseudopodia though usually they have a smooth outline. The large nucleus is eccentrically located, near or at the periphery of the cell and may on occasion be difficult to see (Lewis & Lewis 1926). Staining of the cytoplasm varies in colour and density depending on the physiological state of the cell. Large macrophages may be irregular in shape with foamy cytoplasm when replete with material they have phagocytosed (Russell 1974).

The role of the macrophage in inflammation was first described by Metchnikoff (1891) and has been reviewed by many scientists after that. Lewis & Lewis (1926) explained that the macrophages are distinguished by numerous granules, vacuoles and ingested material, in the cytoplasm, which have the property of staining with neutral red and certain other vital dyes. They may contain fat globules irregularly distributed in the cytoplasm. Cohn & Benson (1965), Volkman & Gowans (1965) and Sutton & Weiss (1966) showed that most macrophages in the teleost they studied were derived from monocytes. It seems likely that the majority of epithelioid cells in lesion such as tuberculosis are derived from macrophages that have never ingested bacilli bacteria since

macrophages can be prevented from developing into epithelioid cells if they phagocytose. It appears, therefore, that macrophages turn into epithelioid cells when they become immobilized at the site of inflammation without being called upon to undertake phagocytosis (Papadimitriou & Spector 1971).

Macrophages act both as protectors of the body and as scavengers. They digest most sorts of foreign material and debris and where possible convert them into a soluble form so that they can be utilized by the body, eliminated as waste products, or at least be used to prime the immune system to stimulate an immune response (Ellis 1976, 1977, 1981; Finn & Nielson 1971 a,b; Phromsuthirak 1976). Surface antibody is present on the cell membranes of about 10 % of the macrophages in fish spleen and kidney (Chiller et al., 1969; Ellis 1974).

Braun-Nesje and her co-workers (1981) isolated and cultured fish macrophages in vitro and found that about 90-99% of these cells had the ability to phagocytose a variety of particles, yeast and bacteria.

Ellis ( 1980,1981) reported that macrophages are phagocytic to virtually any particle foreign to the body and also to damaged host cells. He showed that during an inflammatory response macrophages become activated ie they grow in size, undergo metabolic changes and develop increased phagocytic and killing properties. Their stimulation and responsiveness is non-specific but they affect and are affected by products and cells of the specific immune system. They are also influenced by

substances from specifically stimulated lymphocytes, called lymphokines, and their migration rates in vitro are reduced in the leucocyte migration inhibition factor (LMIF) tests. He also suggested that fish macrophages may play a much more primitive and restricted role than their mammalian counterparts.

#### Melanin-Containing Cells

Melanin-containing cells and free melanosomes have frequently been associated with lymphoid tissues and inflammatory lesions (Ellis & De Sousa 1974; Ellis & Wootten 1978; Ellis et al., 1981; Roberts 1975a ). The function of these melanin-containing cells is as yet unknown (Ellis 1981).

Melanin-containing cells have been reported in fish in connection with certain pathological states. Mawdesley-Thomas & Young (1967) described the occurrence of migratory melanin-containing cells in injured tissue of the goldfish. McQueen and his co-workers (1973) reported the involvement of melanin containing cells in the encystment response to metacercaria in the plaice. Thorpe & Roberts (1972) described the displacement of melanin-containing macrophages from the kidney and spleen into the circulation during severe septicaemia in brown trout.

The exact origin and development of the non-dermal melanin-containing cells so frequently found in inflammatory lesions in fish is poorly understood. The melanin and lipofuscin appears to be derived either from phagocytosis of melanin granules or their precursor

organelles from melanin-containing cells or from de novo synthesis, the lipofuscin from phospholipid broken down from cellular organelles (Roberts 1975a). It has been suggested that fish melanomacrophage centres represent primitive analogues of the germinal centers of higher animals (Agius & Agbede 1984).

#### Neutrophils or Polymorphonuclear Leucocytes (PMN)

Fish polymorphonuclear leucocytes have very similar morphology and histochemical staining properties to mammalian neutrophils, although they often have fewer lobes to the multi-lobed nucleus (Cannon et al., 1980; Ellis 1976; Ferguson 1976) but they are generally only present for a short time and are of limited significance (Klontz & Anderson 1968) and may frequently be seen in the earliest stages of inflammatory lesions (Roberts 1978).

Typically the mature PMN is a large rounded cell containing basophilic cytoplasm, which possesses granules that do not stain markedly with either basic or acid dyes at neutral pH (Ellis 1977). The mean cell diameter varies with species, 8-11 micron being reported for snakehead (Mahajan & Dheer 1980), while Russell (1974) described the plaice polymorpho-nuclear leucocyte as being 5-6 micron. The nucleus is eccentric occupies about one third or less of the cell and is variable in shape (Ellis 1976, 1977; Finn & Nielson 1971 a; Mahajan & Dheer 1980).

The function of the teleost PMN is still in question. It does not appear to be phagocytic to carbon particles injected intraperitoneally, and it does not

possess any surface bound immunoglobulin (Ellis *et al.*, 1976). Klontz (1972) reported that while PMN in the rainbow trout migrated to an inflammatory site caused by bacteria they did not participate in phagocytic activity. However, Finn & Nielson (1971 a) reported phagocytosis by PMN's during experimentally induced bacterial inflammation in rainbow trout. Previous reports of fish PMN's being phagocytic have come from Davies & Haynes (1975), Weinreb & Weinreb (1969), and Watson *et al.*, (1963). In the three-spined stickleback, PMN's also were phagocytic to carbon introduced into the blood, although they were not obviously phagocytic within wounds (Phromsuthirak 1976).

Anderson & Roberts (1975) found from their work on the effects of temperature on wound healing in teleosts that polymorphonuclear leucocyte cells (PMN) appeared in small numbers, around blood vessels at 55 hours and persisted until six days, when they disappeared. They explained that the different time scales in appearance of PMN in teleost may be the result of either a species difference or the present of bacterial factors providing a powerful attraction of PMN. However, if present, such an attraction appeared only to function at high temperatures.

#### Lymphocytes

In the teleost, there appears to be considerable variation in lymphocyte diameter, the average diameter of small lymphocytes in plaice, in smear preparations is 4-4.5 micron (Ellis 1976; Russell

1974), while in the goldfish it is alleged to be up to 8.2 micron (Weinreb 1963) . Large lymphocytes may measure up to 12 micron in diameter, in plaice (Ellis 1977). The nucleus occupies virtually the whole of the cell leaving only a narrow rim of basophilic cytoplasm in which there are a few mitochondria and isolated ribosomes (Ferguson 1976 ).

#### Plasma Cells

The present of plasma cells has not been widely recognized among teleost fish, although they have cells been recorded by a few workers e.g. Ellis (1976) and Timur M. (1975).

The plasma cell, when it has been described, has an oval or circular shape with eccentric nucleus which occupies one half to one third of the cytoplasm. The nucleus is blue and the cytoplasm bright pink to purple coloured in Unna-Pappenheim's staining method, which is the most suitable stain for such cells. They are about 3.4-4.5 micron in diameter in the plaice, the species where therefore they have been most frequently described (Timur M. 1975; Russell 1974). Sections stained by the Unna-Pappenheim method show the cytoplasm of the pyroninophilic cells to be dark pink to purple. The nuclei of some plasma cells show a cart wheel chromatin configuration (Russell 1974).

#### Giant Cells

The giant cell found in the characteristic pathological lesion of tuberculosis was first accurately



described by Langhans in 1868 (Warren 1917). They are regularly present in the later phase of the inflammatory reaction. The formation of giant cells is definitely associated with the more chronic lesions where a balance between infection and resistance has been established (Medlar 1926). There are many theories as to their formation but the generally accepted one is that they arise from fusion of macrophages. Dumont & Sheldon (1965) suggested that giant cells appear to be formed by macrophages which have an electron-dense cytoplasm.

The similarities of the chronic inflammatory response in fish to that of higher vertebrates has led to the assumption that multinucleate giant cells in fish are derived by fusion of macrophage or epithelioid cell types (McVicar & McLay 1985; Richards *et al.*, 1978; Secombes 1985).

The size of the giant cell in fish is very variable 18-60 micron (Timur G. 1975) in diameter. Such cells are generally irregular in outline and more or less circular, oval or spherical. Their multiple nuclei are either distributed at the periphery, usually in a horse shoe configuration, for the Langhans type, or distributed throughout the cytoplasm for the foreign body type. The number of nuclei varies from less than 4 to 30 (Timur G. 1975).

Wolke & Trainer (1971) and Timur G. (1975) found both types of multinucleated giant cells to occur in fish, both the Langhans and foreign body type. Both types contained apparently empty vacuoles within their

cytoplasm. Their nuclei were stained very densely basophilic while their cytoplasm was pink coloured in H & E sections.

Timur G. (1975) confirmed that although piscine tuberculous lesions did not induce foreign body giant cells, but induced the production of the Langhans type cell, both types were produced in lesions induced by both complete and incomplete Freund's adjuvants, it seems likely that the foreign body cells occurring in the complete adjuvant experiment were in response to the mineral oil rather than the mycobacteria. She also observed that giant cells were not apparent in similar studies carried out at low temperatures. Secombes (1985) studying the *in vitro* formation of teleost multinucleate giant cells found that giant cells were indeed capable of phagocytosis, but appeared to have a lower phagocytic performance than surrounding macrophages.

Massive giant cell formation is also found in certain viral diseases of fish but touton giant cells are not found.

#### Eosinophilic Granule Cells (E.G.C.'s)

Eosinophilic granulocytes have been reported from a range of fish tissues, including normal epidermis ( Logan & Odense 1974; Roberts *et al.*, 1971 ), normal gut epithelium (Chaicharn & Bullock 1967; Ellis 1985 ), and normal kidney (Jordan & Speidel 1924). The eosinophilic granulocyte or E.G.C. does not appear to be equivalent to the mammalian eosinophil as it shows different staining

reactions and is ultrastructurally distinct ( Lester & Daniels 1976; Roberts *et al.*, 1971). Barber & Westermann (1978) concluded that these cells were evolutionary precursors to the classical basophilic/mast cell. The eosinophilic granular cell is a relatively large ovoid cell with numbers of strongly eosinophilic refractile granules. Its strongly basophilic eccentric circular nucleus is flattened and situated close to the cell membrane. Little is known of the functions of the E.G.C. Phagocytosis by eosinophils was reported by Macknall & Michels (1932), Jakowska & Nigrelli (1953) and Watson *et al.*, (1963), but Phromsuthirak (1976) failed to observe the phagocytosis of eosinophil granulocytes, a view shared by most other workers.

In higher animals, true eosinophils are often associated with parasitic infection, Lester & Daniels (1976) found large number of eosinophilic granulocytes in the inflammatory response area of white sucker, to the parasites *Actinobdella inequiannulata* and *Lernaea cyprinacea* but it seems likely that these were in fact EGC's. Noga (1986) also found eosinophilic granular cells close to the *Lernaea* parasites in the scale pocket area of largemouth bass, *Micropterus salmoides* (Lacepede).

Ellis and his co-workers (1981) reported that injection of *Aeromonas salmonicida* exotoxin into rainbow trout produced widespread vasodilatation and the eosinophilic granular cells present in the intestinal wall appeared to degranulate. Ellis himself (1981, 1985) suggested that degranulation of the E.G.C. may represent

histamine liberation and supported Barber & Westerman (1978) who reported that the E.G.C. may be a mast cell analogue.

#### Epithelioid Cells

Epithelioid cells, usually supposed to be characteristic of the tuberculosis lesion are in fact a characteristic feature of many types of granulomatous inflammation. Although epithelioid cells vary somewhat in size, they are usually around 6-10 micron in diameter (Timur M. 1975). They appear as polygonal cells with an elongated pale nucleus and cloudy eosinophilic cytoplasm whose outline tends to merge with that of its neighbours (Timur M. 1975).

It appears that macrophages turn into epithelioid cells, when they become immobilised at a site of inflammation, without being called upon to undertake phagocytosis or pinocytosis.

#### Fibroblasts

Fibroblasts are spindle shaped, and their nuclei have a wide variation of size and density. Large fibroblasts in fishes are distinguished from macrophages not only by size and shape but also by their finely speckled nuclei (Russell 1974; Chapman 1961; Timur M. 1975). They arise from fibrocytes in the perimysium or from haematogenous cells derived from the vessels in the perimysium (Finn & Nielson 1971 a,b).

#### THE TUBERCULOUS LESION IN FISH

Tuberculosis is a chronic granulomatous condition widespread in certain fish populations. The cause, in natural infections is one of the aquatic mycobacterial pathogens such as *Mycobacterium marinum* (Aronson 1926; Giavenni & Finazzi 1980). However the lesion provoked by virtually all mycobacteria is similar and so preparations containing mycobacteria can be used as a consistent stimulus for demonstrating particular features of chronic inflammation such as caseation and granulomatosis.

The first instance of a naturally occurring case of tuberculosis in a marine fish was described by Alexander (1913) in cod, *Gadus morhua* L. The name "fish mycobacteriosis" in place of "fish tuberculosis" was proposed by Parisot and Wood (1960). In the last two decades, much has been studied concerning the economic, public-health significance and pathogenesis of piscine tuberculosis. Judging from the literature available virtually all fish species may be affected; Nigrelli and Vogel (1963) list 151 species of fish from which the condition has been recorded.

The piscine tubercle is similar to that in man; both the "soft" and "hard" tubercle may occur (Majeed *et al.*, 1981; Nigrelli & Vogel 1963; Wolke 1975). The tubercle associated with piscine mycobacteriosis differs from the human tubercle in that Langhan's giant cells are seldom present or rare. A second difference is the absence of calcified tubercles and a third difference is

the plethora of acid-fast organism generally present in the piscine tubercle ( Nigrelli & Vogel 1963; Sutherland 1922; Wolke & Stroud 1978). Amlacher (1970) mentioned that giant cells have not been observed with spontaneous originating granulomas, although in the experimental condition they occasionally appear. This finding was confirmed by Timur G. and her co-workers (1977) who reported that experimentally infected marine and aquarium fish with *M. marinum* showed caseation, Langhan's giant cells and cell mediated immunity.

Microscopic examination reveals a classic focal granuloma composed of epithelioid and phagocyte cells occupying a central position surrounded by a wall of fibroblastic cells (Bullock *et al.*, 1971).

Jakowska (1953) infected female guppies, *Lebistes reticulatus* (Peters) with mycobacteria isolated from neon tetras, *Hyphessobrycon innesi* (Myers) and he found that most bacteria were extracellular during the first two hours; the eosinophils were greatly increased within 24 hours while a few macrophages appeared. The vacuoles in the macrophages were large and filled with numerous mycobacteria. Blood and haemopoietic organs of experimental fish sacrificed at 96 hours, one week and one month were negative for macrophages and acid fast bacteria.

The histological lesion of goldfish examined by Majeed and his colleagues (1981) appeared as hard or soft tubercles. The hard tubercles consisted only of histiocytes and epithelioid cells surrounded by a thin fibrous

tissue capsule, without any central area of necrosis. The soft tubercles consisted of a central area of caseative necrosis surrounded by histiocytes, epithelioid cells and a thin fibrous tissue capsule.

Limsuwan and his colleagues (1983) observed tuberculosis in snakehead cultured in Thailand. They found the granulomatous lesions in the visceral organs of infected fish and massive of acid-fast bacillus, *Mycobacterium sp.* were located at the centre of the necrotic areas.

## EXPERIMENTAL DESIGN

The chronic inflammatory response in fish as has been indicated above, has been induced by injecting a variety of foreign materials into the fish ( Ellis et al., 1976; Ferguson 1975 Finn 1970; Finn & Nielson 1971 a,b; Hoole & Arne 1983; MacArthur et al., 1984; Sohnle & Chusid 1983; Suzuki 1986; Timur G. et al., 1977). From the literature it seems that one of the most consistent and replicable responses is that to the oil-water-acid fast bacterium adjuvant known as Freund's complete adjuvant. This was therefore used to induce the condition of chronic granulomatous inflammation in snakeheads, to define their chronic inflammatory response.

## MATERIALS AND METHODS

### Experimental Fish

Farmed striped snakehead averaging 22.9 cm (18.0-29.0 cm) in length were obtained from Suphanburi Province, Thailand and kept in glass aquaria in the laboratory for 3 to 4 weeks before the experiment began, for the acclimation. They were fed on live food once per day.

### Aquaria and Water

The group of 25 fish was held in aquaria, 100 x 45 x 45 cm containing static well water with 50-70 per cent changed weekly. Aeration was supplied by air stone for 24 hours during the experimental period. The average water temperature was 26.9° C (26-28° C).



### Injection

Freund's complete adjuvant (DIFCO) was prepared for use by emulsifying it with an equal volume of sterile distilled water in an sterile vial. The anaesthetized fish were inoculated with 0.1 ml of adjuvant intramuscularly on the flank, immediately above the point where the lateral line drops. Control fish were injected with the same amount of sterile normal saline (0.85 %).

### Sampling Procedure for Histology

Three inoculated fish were killed routinely as follows: 30 min, 1, 6, 12, hours after the injection, then every alternate day for 7 day and every 7 day for 12 weeks.

The blocks of muscle to be examined were removed from the fish samples under profound anaesthesia, and the steaks cut-out were fixed in cold-10 % buffered formalin for a further 24 hours before trimming the fixed tissue into smaller pieces (0.2 x 0.5 x 0.7 cm). Tissue were dehydrated in iso-propyl alcohol, embedded in paraplast wax and thick sections were cut at 5-6 micron. Stains employed included haematoxylin & eosin (H & E) routinely, and for special purposes stains such as Masson's trichrome, Ziehl-Neelsen, Van Gieson and Unna Pappenheim's (Methyl green pyronin) were used. The specimens were mounted in "permount" for further examination.

## RESULTS

There was no gross lesion observed clinically in the injected fish. The histopathological changes were described as follows:

### Histopathological changes

#### 30 min after injection

Apart from bland myopathy associated with the trauma of injection, and the presence of a lacuna of foreign material within the muscle, the only significant feature at this time was the presence of areas of mild haemorrhage at the edge of the lesion bordering the lacunae and hyperaemia of adjuvant vessels (Fig. 27).

#### 1 hour

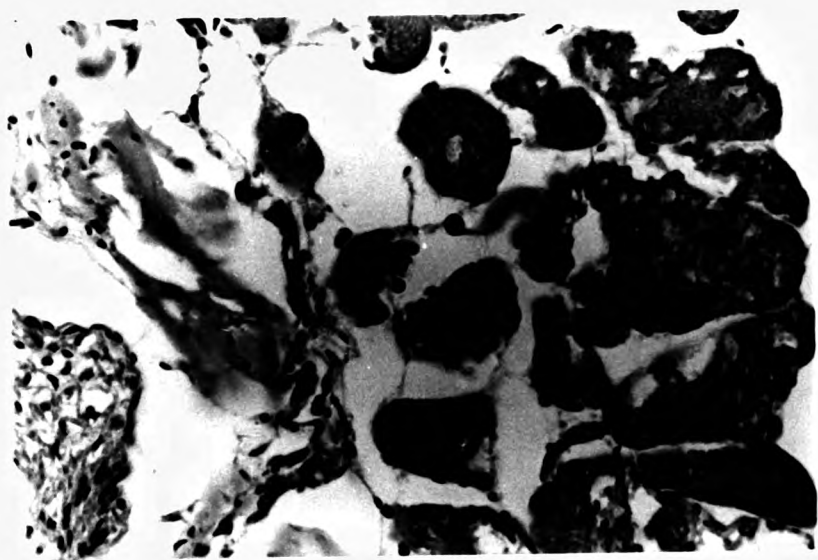
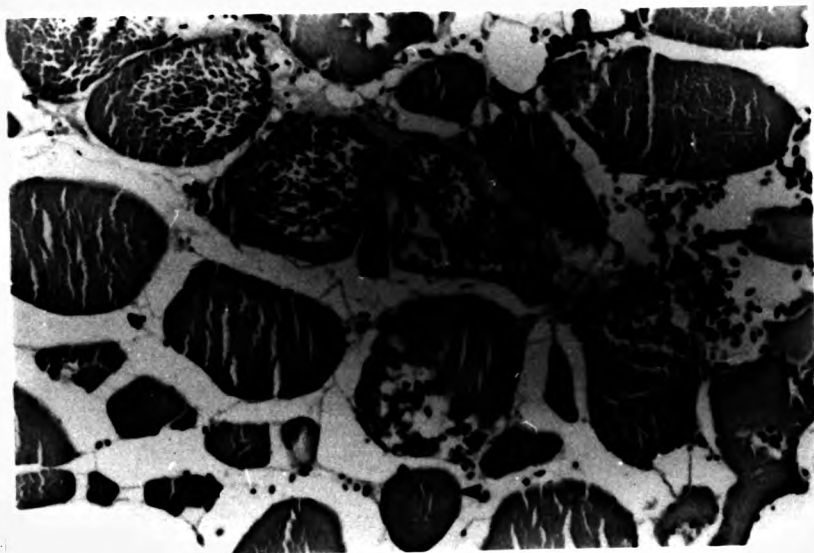
At one hour after injection, the amount of bland myopathy was slightly greater but there was still very little in the way of a host response (Fig. 28, 29).

#### 2 hours

At two hours the host response was obvious. The adjuvant material had extended between muscle bundles, and myopathy was more marked, but a key feature was the presence of significant numbers of white blood cells which included a proportion of neutrophils (PMN), although again macrophages predominated (Fig 30). In Ziehl Neelson stained sections the bacteria were still within the adjuvant and had not been sequestered by phagocytes.

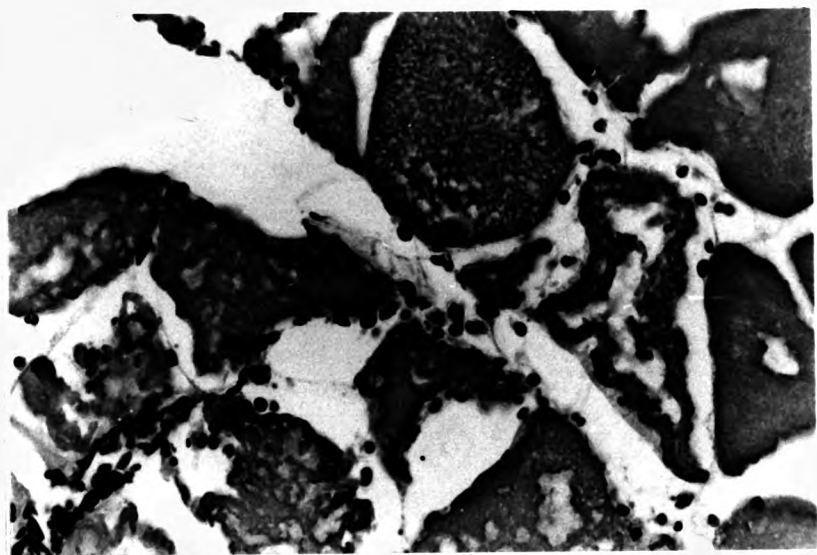
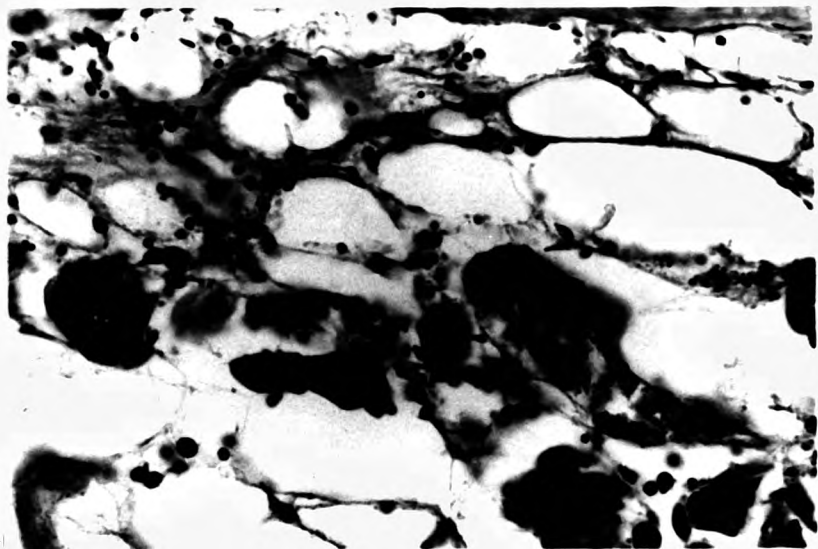
Fig. 27. The injection site with Freund's Complete Adjuvant showed massively swollen muscle cell resulting from attempts of sarcolysis (MN). Note also thickening of cell boundarying as a result of myopathy (arrow) and mild haemorrhage at 30 minutes after injection. (H & E) X 400

Fig. 28. The inflammatory area at 1 hour after the FCA injection showed swollen muscle cell with a mild inflammatory cellular response. (H & E) X 800



**Fig. 29.** By 1 hour after the FCA injection considerable numbers of inflammatory cells had migrated to the defect area. (H & E) X 800

**Fig. 30.** This photograph demonstrates marked myopathy and macrophages (MC) at 2 hours after the inoculation. (H & E) X 800



#### 6 hours

By six hours there was little change in the level of myofibrillar damage, but myophagia was active, and in parts of the edge of the lacuna of oil there was a congery of effete red blood cells, fibrin, white blood cells and thrombocytes.

#### 12 hours

At twelve hours there was still very strong migration into the area of lesion by macrophages. They were particularly numerous and active around blood vessels, and it was in the hypodermal area, with its richer vascular supply, that the macrophage activity was greater (Fig. 31). The large central lacuna had broken up and produced a more diffuse dissemination of the fluid throughout the inter-fibrillar space. This was then starting to be enclosed within arrays of macrophages, which were begining to line up into an epithelioid configuration. At this time there was also the beginning of fibroblast activity.

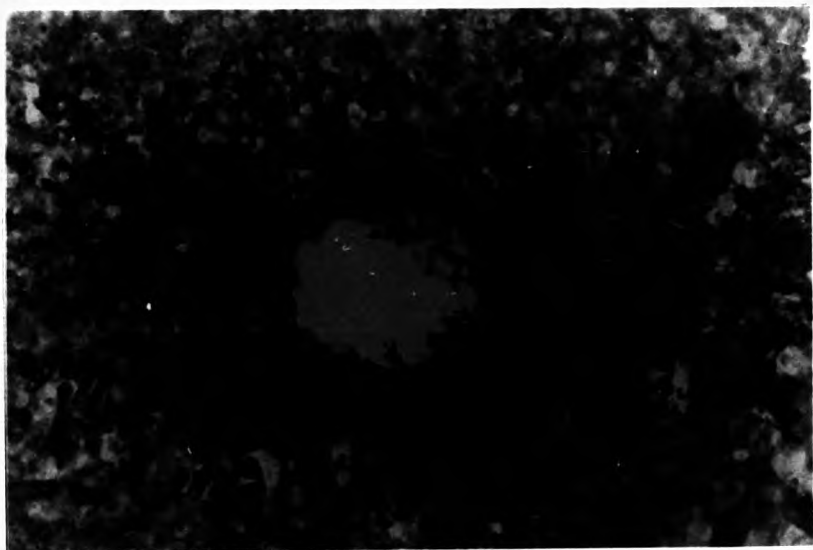
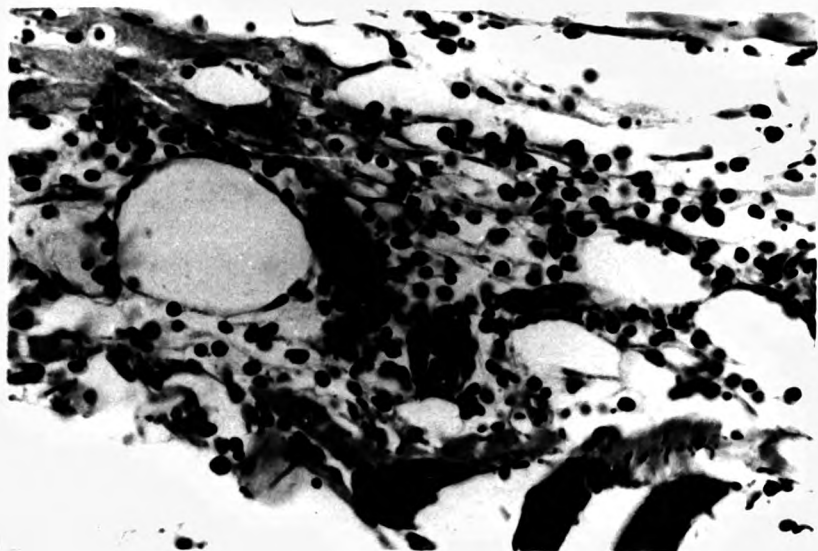
#### 24 hours

At 24 hours the principal change was that of increase in the establishment of the encapsulation process of the vacuoles with epithelioid cells forming round globules, and developing flat almost squamous epithelium on the inner face. Bacteria were still extracellular (Fig. 32). More macrophages and melanocytes were apparent around the blood vessel (Fig. 33).

Fig. 31. A distinct increase in numbers of macrophages especially around blood vessels was apparent at 12 hours after the FCA injection. (H & E) X 800

Fig. 32. Bacterial colonies at edges of the lacuna. (ZN) X 800





#### Day 2

On the second day there was development of a honeycomb of epithelioid cell sequestrations of the adjuvant, particularly adjacent to the intermyotomal fascia, or major vessels on the edge of the lesion. These appeared to be considerably in advance of the areas nearer the centre of the lesion in terms of resolution. Melanin granules were found spreading in the inflammatory area, associated with haemorrhage. Bacteria were still predominantly extracellular, however (Fig. 34).

#### Day 4

The sequestration of adjuvant was very strong by day 4, with all but the centre of the lesion turned into a network of small globules with epithelioid tissue in between (Fig. 35). The myophagia was complete in such areas, and surviving myofibrils were isolated in an island of fibrogranulation tissue. Bacteria were clustered at the edges of lacunae, but still extracellularly. The new capillaries were formed in the fibrosis area along with some regenerated myofibre buds (Fig. 36, 37).

#### Day 6

By day 6 granulation was generalized and specific granulomas were found in areas where the oil had been sequestered intracellularly (Fig. 38). In the centre of these were occasional foreign body and horse shoe shaped tuberculosis giant cells (Fig. 39). The regenerated myofibres and new capillaries were marked and

Fig. 33. By 24 hours after the FCA injection considerable numbers of macrophages and melanocytes were found around the blood vessels. (H & E) X 800

Fig. 34. The mycobacterial colonies were clustered at the edges of the lacunae at 2 days after the FCA inoculation. (ZN) X 800

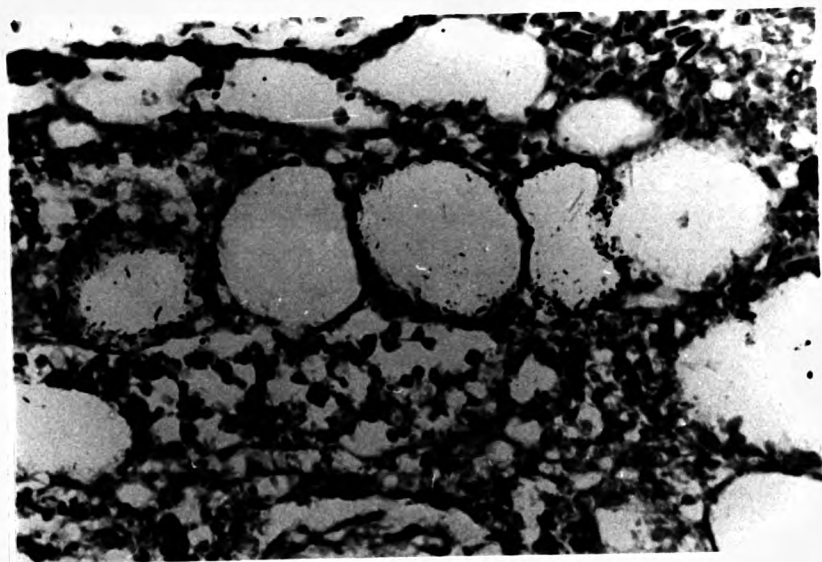
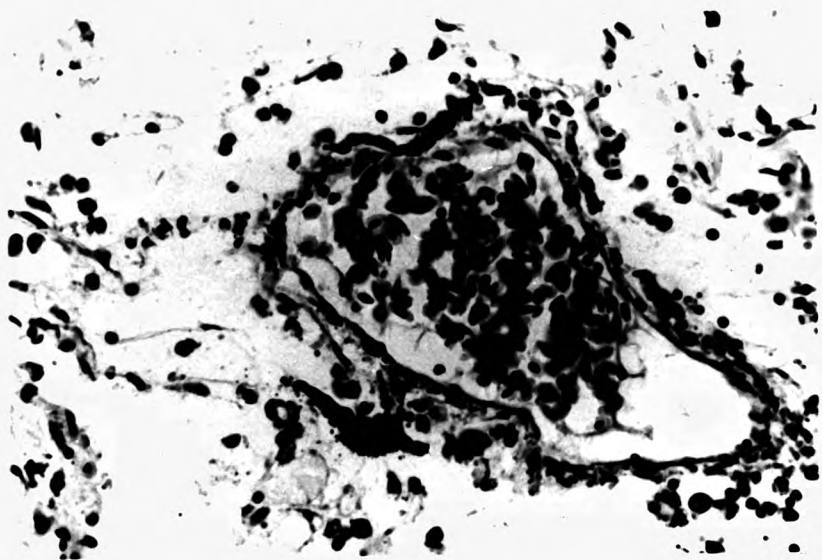

Fig. 35. Sequestration of adjuvant within a honeycomb of epithelioid cells. (H & E) X 200

Fig. 36. By day 4 after the FCA injection there was extensive spread of fibroblasts (arrow) throughout the area between the adjuvant lacunae. (H & E) X 200

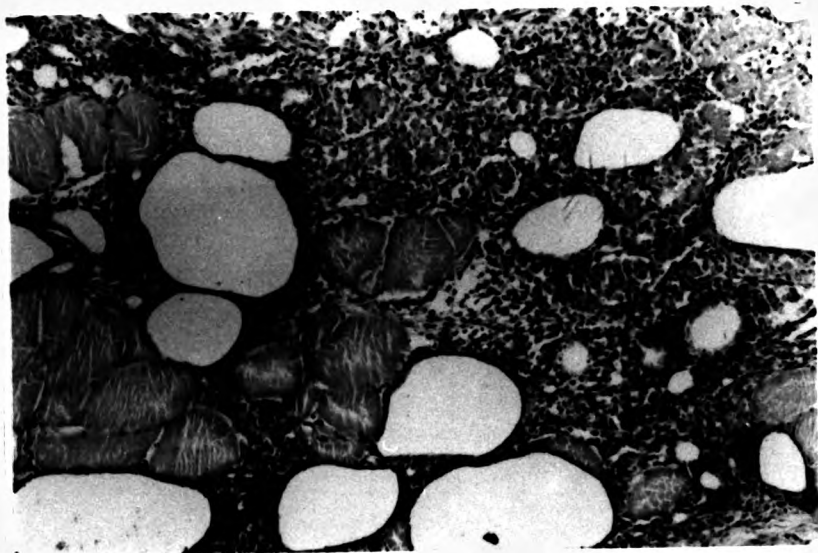
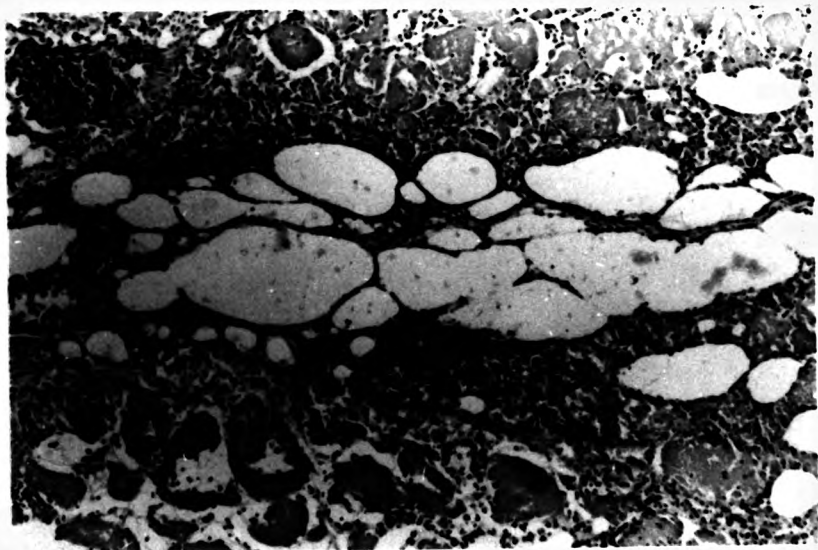


Fig. 37. New capillaries (arrow) were formed in the fibrosis area 4 days after the FCA injection. (H & E) X 800

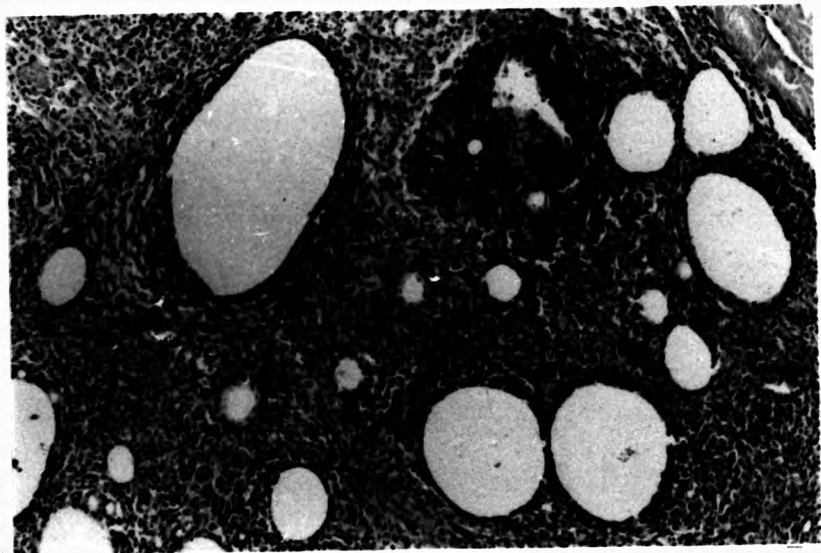
Fig. 38. Freund's complete adjuvant granuloma after 6 days. The significant feature is the giant cell (G) surrounded by the epithelioid cells. (H & E) X 800

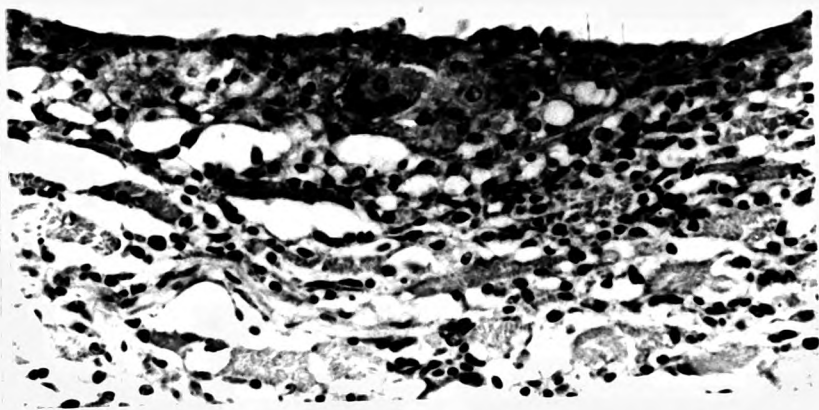



Fig. 39. Granulation and giant cells (arrow) was generalized within the sequestered oil lacunae at day 6 after the FCA injection. (H & E) X 200

Fig. 40. By 6 days after the FCA inoculation regenerated muscle fibres ( arrow) and new capillaries were prominent features of the fibrosis area. (H & E) X 800



extending throughout the injected area (Fig. 40, 41). Lipofuscin granules were observed in the cytoplasm of macrophages which grouped together.

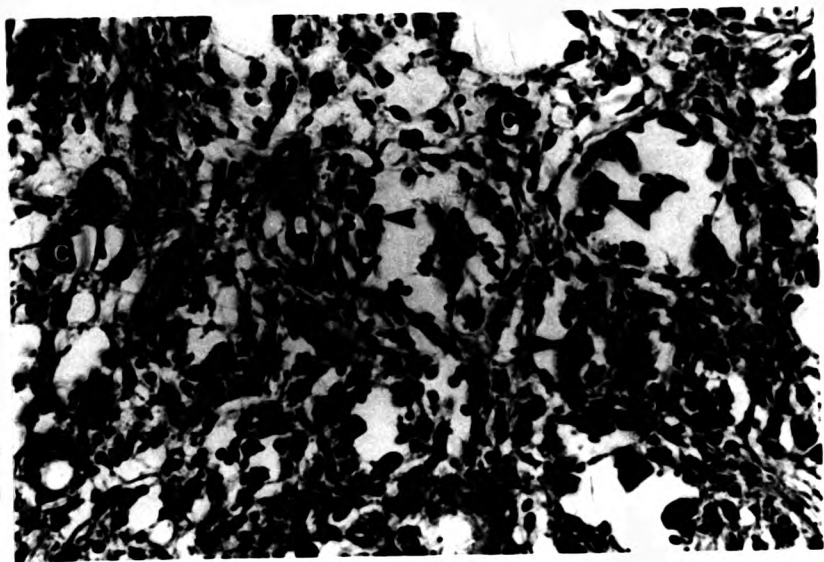
#### Day 7

By this time there was good granulation throughout the lesion area and in most of the smaller granulomas, Ziehl Neelsen positive bacteria were located within macrophages in the centre of such granulomas and often associated with necrosis (Fig. 42). The edges of the lacunae, which generally remained a smooth edged were, where bacteria were present, roughened by the swelling of the macrophages which had engulfed them.

#### 2 weeks

At day 14 the oil of the adjuvant was gathered into lacunae, around which layers of epithelioid cells gradually encroached into the lumen. There was still engorgement of blood vessels, and fibrosis, especially around the edge of the lesion. Further from the lacunae the density of the epithelioid cells gave way to a more sparse complex of fibroblasts and macrophages with some lymphocytes and EGC's in the area where muscle tissue had been largely removed by myophagia. As the remaining muscle tissue was approached it was obvious that the macrophages of the granulation process also extended up between the intact muscle fibres and were causing myophagia of the occasional severely affected fibre. It was at this stage that active, large melanin pigment

Fig. 41. Muscle fibre buds (arrow) and capillaries (C) found in the defect area around day 6 of the FCA experiment. (H & E) X 800



containing cells were first seen within the substance of the inflammatory tissue (Fig. 43).

The lymphocyte activity seemed particularly associated with small foci within the edges of the lacunae, where it was assumed that clusters of TB bacteria had accumulated.

#### 3 weeks

At this stage the lesion was only marginally different from the 14 day lesion, the fibrosis was mature and layered. However conspicuous features were the presence of small foci of caseation in association with lymphocyte activity, and also melanin cell and EGC activity, often in the same location. The melanin bearing cells were generally arranged along the same line as the fibrous tissue. The role of the large numbers of EGC's observed in certain sites was speculative but they were apparently located in looser connective tissue near to areas of caseation.

#### 4 weeks

At this stage the characteristic feature was the very high level of lymphocyte activity, with caseation of obliterated oil lacunae. The largest lacunae, still remaining, had on their edges evidence of continuous sloughing of effete macrophages into the lumen. This material was starting to form a pink granular deposit, with nucleic acid debris, within the oil (Fig. 44, 45, 46 ).

Fig. 42. Melanin pigment (MP) around the granulomata and dead macrophages with lipofuscin in the centres (arrow) observed by day 7 after the FCA injection. (H & E) X 800

Fig. 43. Typical granulomata (TG) at the centre of the lesion with prominent melanin pigment at day 14 after the FCA injection. (H & E) X 200

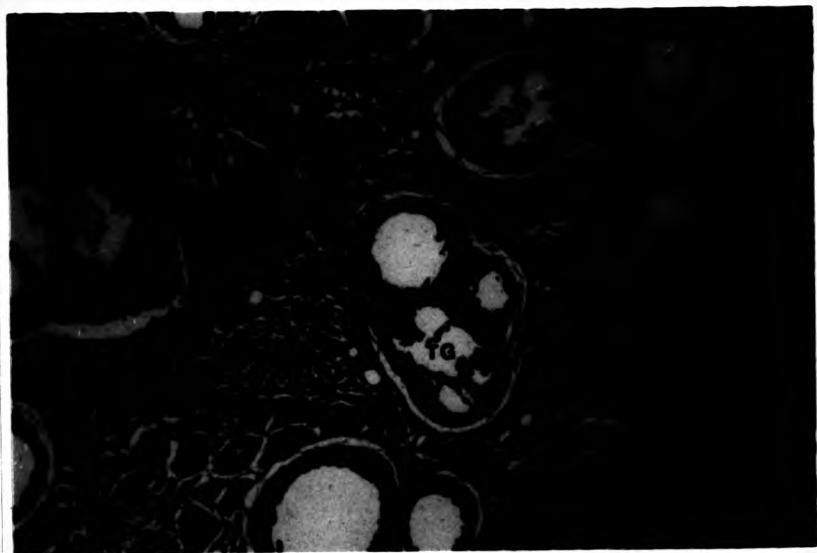
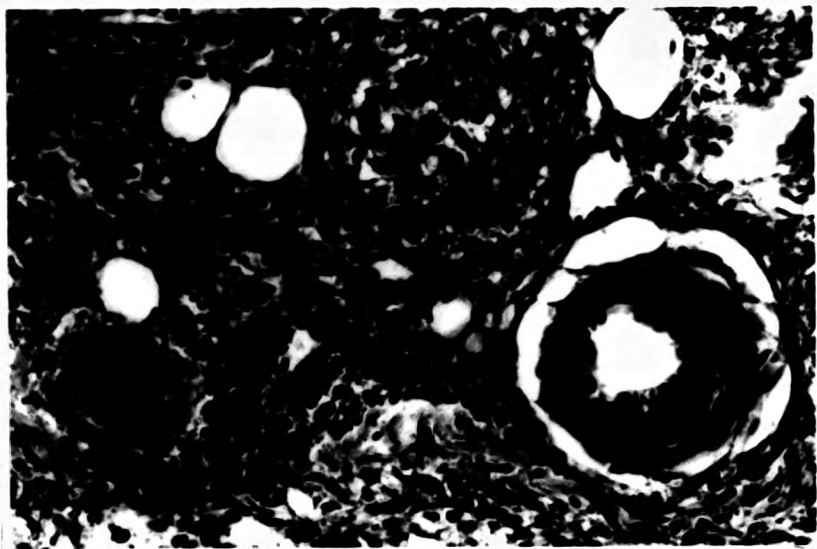
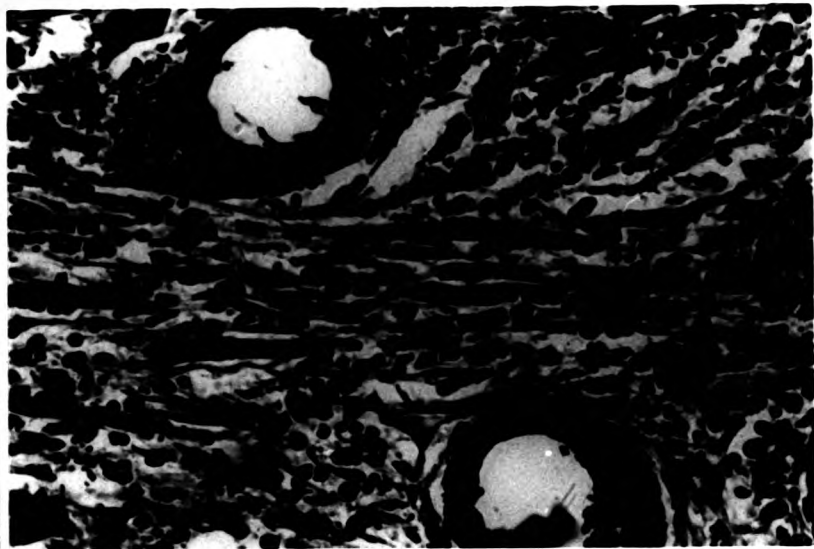


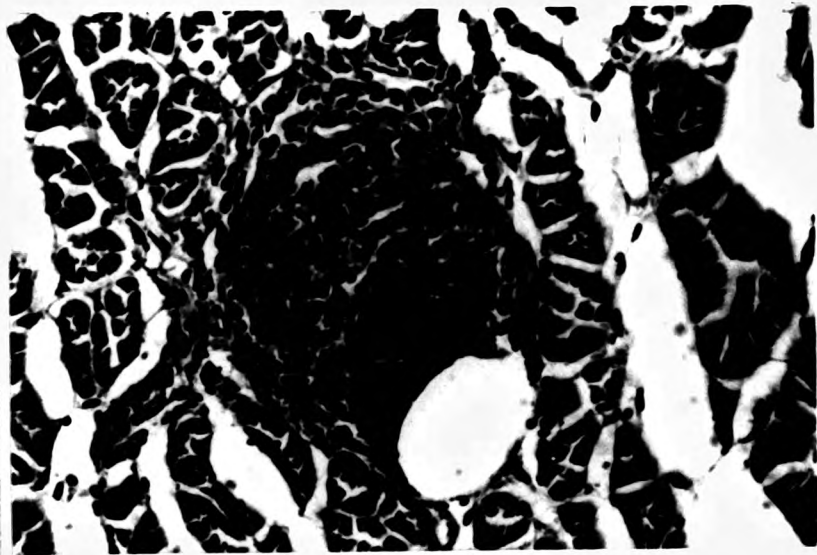
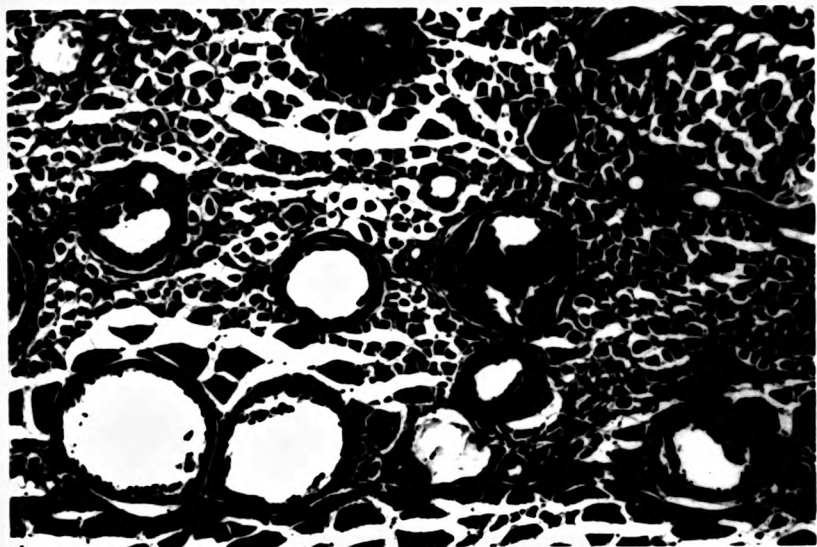


Fig. 44. By day 28 after the FCA inoculation fibroblasts, macrophages and lymphocytes were marked in the central lesion. (H & E) X 800



**Fig. 45. Distinctive melanization around the FCA granulomata at day 28 after injection. (H & E) X 200**

**Fig. 46. Small foci of caseation with lymphocytes, eosinophilic granular cells (EGC) and macrophages, found at day 28 after the FCA injection. (H & E) X 800**



#### 5 weeks

At day 35 the slow progress to resolution continued. Melanization had developed to actually coat certain of the larger, still oil bearing, lacunae, smaller ones showed caseation, very active lymphocyte and EGC activity and subsequent fibrosis (Fig. 47). There seemed to be a negative correlation between presence of EGC's and melanization, as if the melanization was a later stage response where the response in which the EGC was involved was unsuccessful.

#### 6 weeks

Bridging of the large spaces with necrotizing tissue was very obvious, all remaining lacunae being reduced, and covered by dense epithelioid tissue, many surrounded by a layer of melanin cells. The eosinophilic granular cells (EGC), macrophages and some vacuoles were observed in the caseous necrotic area (Fig. 48).

#### 7 weeks

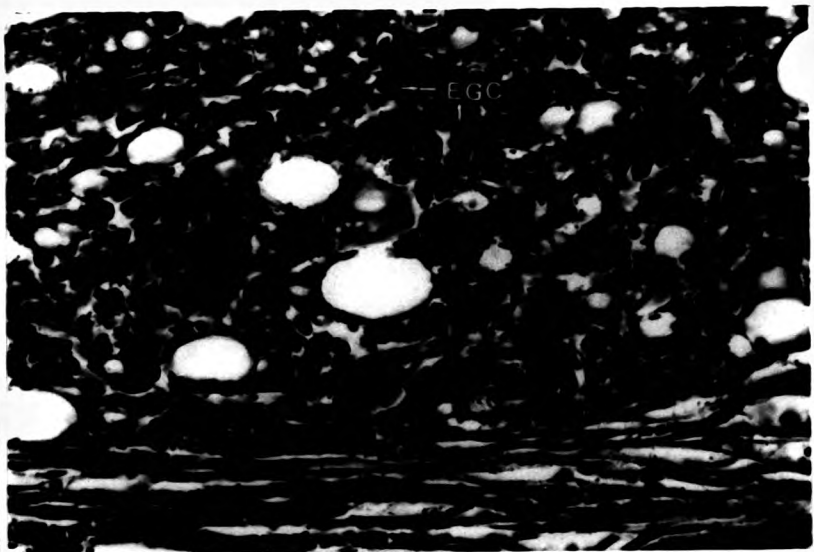
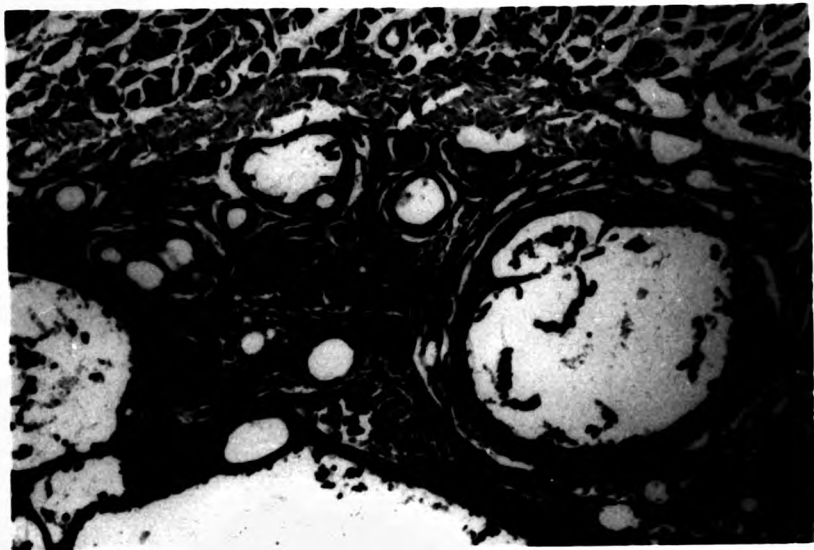
At day forty nine the lesion was very highly melanized, with dense epithelioid capsules, and little or no inflammatory activity. Lymphocytes and EGC's were less evident, but macrophages loaded with melanin, or other brown pigment, were common in the neighbourhood of larger vacuoles (Fig. 49).

#### 8 weeks

Over the 8-9<sup>th</sup> week there was little change in the condition of the lesion, merely consolidation of the

Fig. 47. Melanization around the various sized granulomata at day 35 after the FCA injection. (H & E) X 200

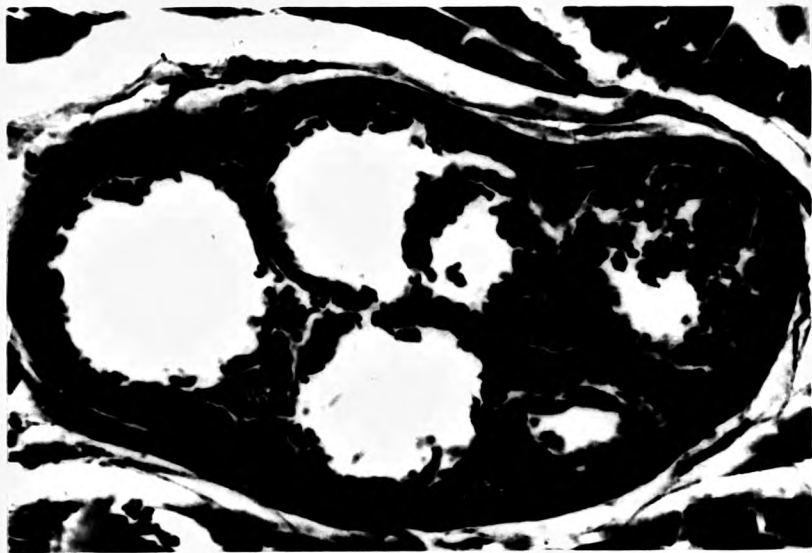
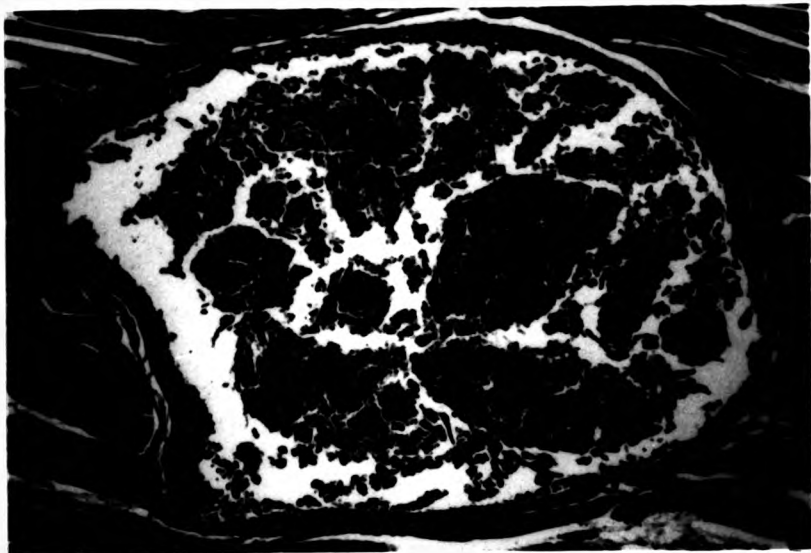
Fig. 48. By day 42 after the FCA inoculation eosinophilic granular cells (EGC), macrophages and some vacuoles were observed in the caseous necrotic area. (H & E) X 800



**Fig. 49. Large lacuna with dense epithelioid capsule surrounded by melanin pigments at day 49 after the FCA injection. (H & E) X 200**

**Fig. 50. By 56 days after the FCA injection macrophage bridges were still developing dividing the lacuna into smaller and smaller size. (H & E) X 800**





process of encapsulation and melanisation, with both melanocyte coverage of the capsule, and focal location of what were probably ectopic melanomacrophage centres (Fig. 50).

#### 9 weeks

At this stage the dominant development was the further melanization of the healing lesion, visible even with the naked eye (Fig. 51). Stellate and round, densely pigmented cells occurred, and some round pigment cells had even migrated into the depths of dense epithelioid tissue around the last remaining oil vacuoles.

#### 10 weeks

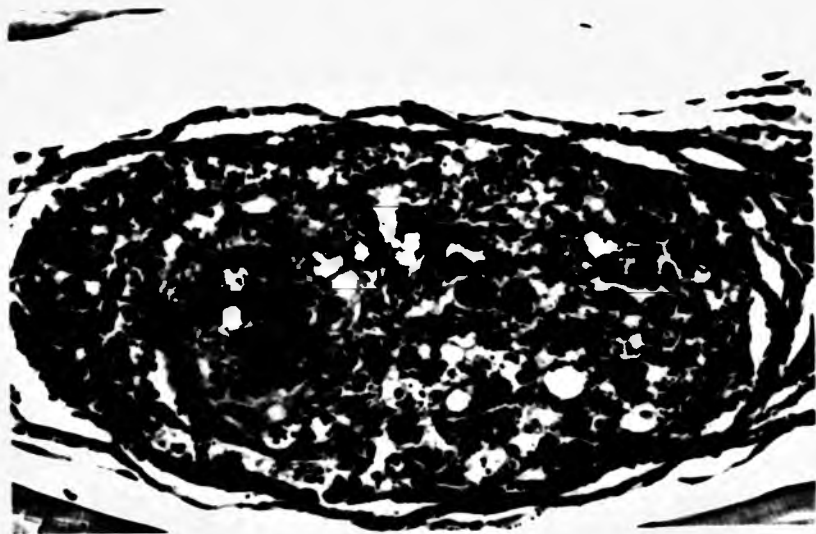
The lesion was still stable and similar to the previous ones but there was a higher level of sloughed material within the remaining vacuoles, and melanin containing cells, earlier seen migrating to and through the epithelioid capsule, were now seen actually within it, or disrupted at the edge of the oil lacunae.

#### 11-12 weeks

This was the final sampling period for the study, and even by this stage, complete resolution of the lesion had not occurred. However the final stages were in sight, with all lacunae largely filled with necrotic sacrificed epithelioid debris, extensive layers of melanin around them, and at one pole of each lacuna, a strip of macrophage/melanin pigment tissue from which the elaboration of pigment cells appeared to develop (Fig. 52).

**Fig. 51. Dense melanin pigments occurred around the granuloma at 63 days after the FCA injection. (H & E) X 400**

**Fig. 52. Lacuna filled with necrotic sacrificed epithelioid debris and surrounded by dense melanin pigments. (H & E) X 800**



This was similar in many ways to a melanomacrophage centre, but, paradoxically, in the snakehead the melanomacrophage centre of haemopoietic tissue are almost entirely yellow brown pigment laden, with very little black, granular pigment such as occurs in lower fishes.

#### DISCUSSION

The features of the inflammatory response in snakehead infected with Freund's complete adjuvant were remarkably similar to those of the chronic granuloma of teleost fish as described in the plaice (Roberts 1976; Timur G. 1975; Timur G. *et al.*, 1977) and in the rainbow trout ( Finn & Nielson 1971 a,b; Roberts *et al.*, 1973 a,b). The most similar studies to the present work were probably those reported by Finn & Nielson (1971 a,b) and Timur G. (1975). The cells found in the different stages of the response were similar to those which occurred in plaice and rainbow trout, comprising macrophages, polymorphonuclear leucocytes, epithelioid cells, lymphocytes, fibroblasts and giant cells.

In the present study, the response of the snakehead was marked, with macrophages and few PMN at the very early stages (2 hours) after the inoculation. The macrophages were particularly numerous and active around blood vessels by 12 hours and then starting to line up into an epithelioid configuration. The encapsulation process of the vacuoles with epithelioid cells was increased by 24 hours. The macrophage infiltration began to decrease by day 21. These findings suggested a such

faster response than had been reported in rainbow trout by Finn & Nielson (1971 a,b ) and in plaice by Timur G. (1975). They reported that in their species the PMN and macrophages developed by day 1 in rainbow trout and day 3 in plaice.

Vascularisation is an important factor in allowing nutrients to reach the newly developing granulation tissue in all types of inflammatory lesions. It began in these lesions in the snakehead around day 4, which was about the same time as the development of fibroplasia. The reduction of fibroplasia started around the 28<sup>th</sup>-35<sup>th</sup> day. In contrast the fibroblasts moved into the lesion of rainbow trout by day 8-16 and by day 21-28 in plaice that were injected with Freund's complete adjuvant (Finn & Nielson 1971 a,b; Timur G. 1975).

These three characteristic features of chronic inflammation, namely macrophage infiltration, fibrosis and vascularization, were thus all considerably faster in occurrence than was the case with the cold water species studied by Finn & Nielson (1971 a, b) , Timur G.(1975) and Timur M.(1975). This was almost certainly due to the higher temperature at which the snakehead exists. All three functions are dependent on the rate of protein synthesis, which is a temperature dependent metabolic activity, and as Anderson & Roberts (1975) have shown for acute inflammation, rate of wound healing in an individual species is temperature dependent.

The results of the present study supported the work done by Finn & Neilson (1971 a,b) on the importance

of the myoseptum between the myotomes in the inflammatory process of fish muscle as a retaining barrier in limiting the spread of a noxious agent. It also appears to be a significant source of fibroblasts.

The buds of regenerating myofibres were first seen on the 4<sup>th</sup> day and had strongly developed as regenerated myofibres by day 6. The new muscle bundles had virtually replaced the fibrosis area almost completely by the 28<sup>th</sup> day but the epithelioid granulomata still surrounded the debris which was still scattered around the defected site. The muscle regeneration started at the edge of the granuloma which was similar to the report of Timur G. (1975) who found that the muscle of experimentally treated plaice regenerated around day 35-42, which was very slow in comparison to what was observed in the present study.

As with the other components of the granuloma, development of both types of giant cells was observed by day 6 which was 10 days faster than what had been recorded in rainbow trout and plaice (Finn & Nielson 1971 a,b; Timur G. 1975). They were found adjacent to the actual oil lacuna. According to Timur G. (1975) the giant cell formation was directly related to temperature because she could not demonstrate any giant cells in the low temperature experiment. There was, however, some support for a possible retardation rather than prevention by temperature, since Timur M. (1975), in his study of the carrageenin granuloma of plaice, found that very occasionally Langhans type giant cells could be seen

after 85 days at 5° C.

By using the different types of stimulant such as talc (magnesium silicate), beryllium oxide, *Mycobacteria* (Timur G. 1975) and carrageenin (Timur M. 1975) these two workers, could produce various sizes of multinucleated giant cells in plaice. The presence of diatoms (Chrysophyta) in granulomatous enteritis in a white sucker stimulated both foreign body and Langhans type of giant cells in a clinical case described by Wolke & Trainer (1971).

Piscine tuberculous lesion do not normally produce foreign body type giant cells but both types were produced in both complete and incomplete adjuvant studies so Timur G. came to the conclusion that the foreign body type occurring in her adjuvant experiments were in response to the mineral oil rather than the *Mycobacteria* (Timur G. 1975).

Acid-alcohol fast bacteria were never seen in the cytoplasm of the giant cells in this study and other workers have not mentioned this either, although they were often found within either macrophages or at the edge of the oil vacuoles. Secombes (1985) however, reported that giant cells were capable of phagocytosis but, at a lower phagocytic performance level than macrophages. This was not obvious in the case of the snakehead where such phagocytosis was never seen.

The focal aggregations of lymphocytes, which were very conspicuous after the 14<sup>th</sup> day, was likely related to their responsibility for the development of



cell mediated immunity. Richards and his colleagues (1978) explained that the caseous necrotic centres seen in many granulomatous lesions are a feature of the delayed hypersensitivity response such as that seen in tuberculous granulomata, and when seen in association with lymphocyte accumulations, were usually indicative of a cell-mediated immune response.

The melanin pigment containing cells, very different from the pigment bearing macrophages, were first observed within the inflammatory tissue around day 14. The melanin bearing cells were generally arranged along the same line as the fibrous tissue. The melanisation development was dominant through to the end of the experiment (77 days).

The macrophages loaded with melanin and lipofuscin were commonly found by day 49. Lipofuscin, a polymerised break down product of lipids (Miquel *et al.*, 1977), was often seen in macrophages of the spleen and kidney of diseased fish. It may be the by product from the oxidation of tissue lipids during an inflammatory response as a consequence of peroxidase released by neutrophils, but end stages of phospholipid membrane metabolism following myofibril breakdown would also contribute (Roberts 1975a).

Numbers of eosinophilic granular cells were observed in the area where muscle tissues had been removed especially located in looser connective tissue near to areas of caseation. They were decreased in numbers around the 49<sup>th</sup> day after the inoculation.

Eosinophilic granular cells had been reported in the tissue of normal fish (Chaicharn & Bullock 1967; Logan & Odense 1974; Roberts *et al.*, 1971) and in parasitised teleosts (Lester & Daniels 1976; Reinschuessel *et al.*, 1987; Roberts 1978). EGC's were also found in the brain of tropical tilapia, *Tilapia rendalii* (Boul.) exposed to endosulfan insecticide (Matthiessen & Roberts 1982).

The exact role of the EGCs in fish has not yet been determined. Ellis (1981, 1985) suggested that EGCs were histaminogenic and may be similar to mammalian mast cells (Barber & Westerman 1978). They have, however, been hypothesised to be a part of the teleost's defence mechanism (Eseasor & Stokoe 1980).

Plasma cells, the cells usually associated with circulating antibody production, and seen by previous workers, on occasion, in chronic lesions, were not observed even by use of the Unna Pappenheim staining method.

The cellular inflammatory response of the striped snakehead to Freund's complete adjuvant was therefore similar to that of the plaice and rainbow trout in its general pattern and in the development of chronic granulomata but the rate of time scale of the cellular response in the snakehead was much faster than the previous two species in which detailed studies have been carried out.

**CHAPTER 4: EFFECT OF AEROMONAS HYDROPHILA INFECTION  
ON THE WOUND HEALING AND CELLULAR RESPONSE  
OF THE STRIPED SNAKEHEAD**

## INTRODUCTION

*Aeromonas hydrophila* is a gram-negative bacterium which is widely distributed in freshwater systems, especially where there are high organic loads. It has been reported from a wide range of fish species in temperate and tropical water systems. It is generally considered as a facultative pathogen, invading the tissues of a fish severely stressed or physically traumatised by another agent (Plumb *et al.*, 1976; Snieszko & Axelrod 1971).

During the outbreak of snakehead ulcerative disease throughout the central and southern parts of Thailand, millions of fish in cultivated areas and in natural water systems died with septicemia associated with either lacerated wounds or red sores. One of the organisms consistently isolated from infected fish was *Aeromonas hydrophila* (Roberts *et al.*, 1986; Tonguthai 1985). Similar findings, again associated with fatal *A. hydrophila* septicemia were also obtained in studies of snakehead ulcerative disease as it spread to Burma (Boonyaratpalin personal communication), Laos (Tonguthai personal communication), Sri Lanka (Frerichs 1988), and Bangladesh (Tonguthai personal communication).

*A. hydrophila* does not normally cause epizootics in wild fish. In view of the great mortality levels associated with its presence in fish with the snakehead ulcerative disease, it was considered valuable to investigate the pathogenesis of the inflammatory lesion induced by this pathogen in normal snakeheads.

This would allow an assessment of the ability of this pathogen to induce septicaemia in its own right, to study the host response to it, and compare it in healthy snakehead with that found in snakehead ulcerative disease.

## REVIEW OF THE LITERATURE

## BIOLOGY OF AEROMONAS HYDROPHILA

It is well known that *A. hydrophila* is ubiquitous in natural water in all parts of the world. *A. hydrophila* is a gram-negative bacteria classified as a member of the family Vibrionaceae whose normal habitat is in soil and water ( Bullock et al., 1971; Popoff & Veron 1976; Post 1983). It has been described under many synonyms (Snieszko & Axelrod 1971).

<i>Bacillus hydrophilus</i>	<i>Pseudomonas ichthyosmia</i>
<i>B. hydrophilus fuscus</i>	<i>P. fermentans</i>
<i>B. ichthyosmius</i>	<i>P. hydrophila</i>
<i>B. punctatus</i>	<i>P. granulata</i>
<i>B. ranicida</i>	<i>P. hirudinis</i>
<i>Proteus ichthyosmius</i>	<i>P. punctata</i>
<i>P. hydrophilus</i>	<i>Vibrio jamaicensis</i>
<i>P. melanovogenes</i>	<i>Aeromonas liquefaciens</i>
<i>Escherichia ichthyosmia</i>	<i>A. punctata</i>
<i>Bacterium hydrophilum</i>	<i>Flavobacterium fermentans</i>

*A. hydrophila* strains have the following characteristics; gram-negative, straight rods measuring approximately 0.5 x 1.0-4.0 micron, polar flagella usually monotrichous; facultative anaerobes, fermenting carbohydrates with formation of acid and/or gas; production of 2,3 butanediol; cytochrome oxidase positive; reducing nitrates; insensitive to the vibriostatic compound ( 2,4 diamino 6,7- di-isopropyl pteridine 0/129 ); G-C content of DNA, 57 to 63 %. There

is some variation in colonial morphology though colonies are generally circular, smooth and raised. They may be isolated on any general purpose medium such as tryptic soy agar or brain heart infusion agar. The choice of Rimler-Shotts agar ( Shotts & Rimler 1973 ) was used as a selective media for *A. hydrophila*, because on this medium it provided yellow colonies, but this was replaced by MacConkey agar with trehalose substituted for lactose in the formulation, because R-S agar was found to be too selective ( Kaper et al., 1981 ).

Characteristics common to all of the identification schemes proposed for *A. hydrophila* include: manitol fermentation (+); inositol fermentation (-); ornithine decarboxylase (-); growth in absent of added NaCl; H<sub>2</sub>S production from TSI (-).

Strains of *A. hydrophila* produce various extracellular toxins or enzymes that may be virulence factors and possibly virulence determinants ( Buckley et al., 1981). These include gelatinase, caseinase, elastase, lipase, lecithinase (Nord et al., 1975), haemolysin, cytotoxins and enterotoxins ( Boulanger et al., 1977; Cumberbatch et al., 1979; Riddle et al., 1981).

Thune and his co-workers (1982 a, b ) and Lallier and his colleagues (1984) suggested that the haemolysins are probably not the principal toxins responsible for the pathogenicity since there is no correlation between the haemolytic activities and the virulence of the strains of *A. hydrophila* and also the purified haemolysin is not toxic for fish.

Many strains of *A. hydrophila* strongly agglutinate human blood cells. Haemagglutination can readily be inhibited by specific sugars. A role of pili in haemagglutination has been observed, and strains of *A. hydrophila* possess a variety of attachment mechanisms (Atkinson & Trust 1980).

The existence of resistance factor plasmids in *A. hydrophila* is also documented (Aoki *et al.*, 1971, 1972, 1973; Shotts *et al.*, 1976).

*A. hydrophila* is widely distributed in the aquatic environment where it grows on organic matter. It is found in marine systems which interface with freshwater and it can be found at all salinities, except the most extreme (>100‰) (Hazen *et al.*, 1978). The minimum temperature that *A. hydrophila* can grow is 0-5°C, the thermal optimum for culture is 25-30°C and the maximum is very close to 45°C (Post 1983; Rouf & Rigney 1971). Water pH does not seem to play a significant role in their distribution (Hazen *et al.*, 1978), they still can grow in media with a pH of 5.5-9.0 (Buchanan & Gibbons 1974).

It is known that *A. hydrophila* is a member of the normal flora in the gut of fish (Neilson 1978; Trust & Sparrow 1974), and under certain conditions the organism can cause diseases in aquatic animals (Bullock 1961; Plumb *et al.*, 1976; Shotts *et al.*, 1972), as well as in humans (Davis *et al.*, 1978; Joseph *et al.*, 1979).

Bacterial haemorrhagic septicaemias due to strains of *A. hydrophila* may be transmitted through the



water, via diseased and healthy carrier fish and other affected vertebrates, and in association with external and internal parasites (Newman 1983). Any type of stress such as crowding, excessive handling, high water temperatures, low dissolved oxygen levels, poor nutrition, etc. can cause healthy carrier fish to break out with the disease ( Haley et al., 1967; Rock & Nelson 1965; Shotts et al., 1972; Sniieszko 1974).

As has been previously noted, strains of *A. hydrophila* have been isolated from a variety of environmental sources, especially in water with high organic levels (Roberts 1978; Sniieszko & Axelrod 1971 ), and in sewage (Geldreich 1973; Sniieszko 1974). Since this organism can be regularly isolated from apparently healthy fish (Boulanger et al., 1977; Neilson 1978; Trust & Sparrow 1974), or diseased fish (Bullock 1961; Plumb et al., 1976; Shotts et al., 1972), there has been a question concerning the degree of virulence of strains from various sources. Strains of *A. hydrophila* isolated from water were significantly less virulent than the isolates from diseased fish and freshwater prawns (De Figueiredo & Plumb 1977). Lallier and Daigneault (1984) suggested that some virulent strains of *A. hydrophila* have particular toxins for fish, whereas weakly virulent strains did not.

## PATHOGENESIS OF AEROMONAS HYDROPHILA INFECTION

Diseases associated with *A. hydrophila* have been variously named; bacterial haemorrhagic septicemia in common carp, *Cyprinus carpio*, L. (Snieszko *et al.*, 1938), red sore disease in pike, *Esox lucius*, L. (Reed & Toner 1941), red spot in mullet, *Mugil cephalus*, L. (Burke & Rogers 1981). The symptoms of the disease are similar in appearance to those found in other bacterial haemorrhagic septicemias. Symptoms and histopathology have been described by many workers ( Schaperclaus 1930, 1953; Spiczakow 1933; Amlacher 1961; Gaines 1972; Wolke 1975; Bach *et al.*, 1978; Huizinga *et al.*, 1979), and can be differentiated into four general categories: acute with few gross symptoms, acute form with dropsy, chronic ulcerous form and latent form with no signs.

There is some doubt as to whether physical trauma is necessary to induce *Aeromonas* lesions, or whether conditions resembling the natural septicemia condition can be induced by simple immersion (Huizinga *et al.*, 1979; Ventura 1985). Elliott & Shotts (1980) and Ventura & Grizzle (1987) reported that neither goldfish nor channel catfish could be infected by immersion even when scales were removed. These differences in result can be explained by species defence mechanism differences, virulence of the bacterial strains or the accuracy of the techniques used. That over crowding and high temperature can lead to the disease condition is, however, generally accepted (Snieszko 1974; Ventura & Grizzle 1987).

Thorpe and Roberts (1972) are among the few workers who have investigated an aeromonad epidemic in wild fish. They reported that in brown trout the skin lesions showed two separate but associated pathogenic processes, fungal from the exterior and bacterial from the interior. Where the fungus was well established the epithelium was absent, and fungal hyphae could be seen in the fragmenting tissues of the extremely collagenous and relatively avascular dermis. At this stage there was a pronounced cellular response with both neutrophil and monocyte cells entering the dermal tissue. Where the fungal infection was less well established the epithelium was hyperplastic, irregular and covered with a mat of fungal hyphae, bacteria and blood cells.

The melanophores of the dermis were fragmented, and the basement membrane altered from the relatively flat structure of the normal fish to a highly convoluted structure resembling the dermal ridge formation of mammal skin. In the hypodermis, the bacterial element of the skin pathology was extant. The vessels of the hypodermis were all engorged and a large proportion of the cells involved were monocytes. The fibres of the myotomes below the lesions were fragmented and oedematous and myophagic clusters of macrophages were observed around them.

Experimental work on *A. hydrophila* infection has been conducted in many fish species. In channel catfish infected with this bacteria, oedema of the epithelial cells of the gill lamellae, and increase in the number of lymphoid cells with necrosis of epithelial

lining of tubules in the trunk kidney are reported (Gaines 1972). Definite sequestering of the pathogenic bacteria by the ellipsoids of the catfish spleen has also been observed. Dividing bacteria (intrasplenic bacterial proliferation) were commonly seen by electron microscopy. Destruction of the endothelial and reticular cells of the ellipsoids was a conspicuous consequence of this bacterial proliferation. Necrosis was confined primarily to the sheaths at some extent at the site of the injection (Bach *et al.*, 1978). Spleen was destroyed in a wide area, causing leucopenia (Wolke 1975).

According to Bach and his co-workers (1978) there was marked infiltration of free macrophages, in regions of localized bacterial infection in the spleen. These macrophages phagocytose the bacteria and cell debris. In the electron microscope, in only a few instances does it appear that the macrophages were enzymatically destroying the bacteria in the phagosomes. Usually, it seems that the bacteria remained intact and alive after phagocytosis, and eventually cause the degeneration, death and lysis of the macrophage, ultimately being released into the extracellular debris.

Huizinga *et al.*, (1979) found that the external lesions of red-sore disease of largemouth bass range from those affecting a few scales, to those associated with extensive chronic ulcerations. There was focal haemorrhage, oedema and dermal necrosis which exposed underlying muscles and led to infiltration of mononuclear and granulocytic inflammatory cells. Internally, the

liver and kidney showed focal necrosis, in the most severe cases, complete destruction of the structural integrity of both organs. Pathological changes were not serious in either the spleen or heart, even in cases with massive damage in the liver and kidney. Melanin-macrophage centres were abundant in the liver, kidney and spleen, but not in the skin.

Ventura (1985) reported that a 96-hr median lethal dose of *A. hydrophila* injected intramuscularly into channel catfish developed into a systemic infection characterized by diffuse necrosis in the internal organs and presence of melanin-containing free macrophages in the peripheral circulatory system. The presence of increased amounts of lipofuscin and haemosiderin aggregates in the liver and spleen characterized skin-only infections.

Experimental studies on *A. hydrophila* have been carried out with tropical fish species by many workers. Charnchit (1985) infected sand goby, *Oxyeleotris marmoratus* Bleeker with *A. hydrophila* intramuscularly and reported that all infected fish showed scale protrusion which developed into large external ulcerative lesions on the flank at the injected area. Petechial haemorrhage at the base of the fins and on the body and ascites were observed. Zenker's necrosis, inflammation and haemorrhage were present in the necrosis area. All fish recovered within approximately 30 days after the injection without any treatment.

Histopathological changes in the internal organs of the infected fish showed swollen hepatocytes, and necrosis of the spleen and exocrine pancreas. Oedema, hyperplasia and hypertrophy were observed in secondary gill lamellae.

Limsuwan & Chinabut (1986) reported that fish infected with a sublethal dose of *A. hydrophila* were lethargic, and developed ascites. Petechial haemorrhage developed around the intraperitoneally injected area, and an inflammatory response with muscle necrosis was seen there. There was, however, no evidence of histopathological changes in the internal organs of such diseased fish.

Lerssuthichawal (1987), studying the effect of temperature on the susceptibility of walking catfish, *Clarias batrachus*, L. injected intramuscularly with *Aeromonas* suspensions demonstrated that a large external ulcerative lesion developed. The lesion was, however, completely healed in 10-11 days at 22-23° C, 7-8 days at 27-28° C and 5-6 days at 33-34 ° C. The migrating epidermis was seen to cover the lesion followed by fibrous connective tissue replacement of the necrotic tissue. The gills and internal organs appeared normal.

Llobrera and Gacutan (1987) reported that *A. hydrophila* was consistently associated with necrotic ulcers and lesions in striped snakehead, walking catfish, goldfish and goby, *Glossogobius giurus* (Buchanan Hamilton) in Laguna de Bay, Philippines. They also mentioned that when they transferred the diseased fish to

cleaner, less polluted water, infected fish recovered and the lesions and ulcers healed, although the affected areas developed darker pigmentation.

#### TEMPERATURE AND BACTERIAL HAEMORRHAGIC SEPTICAEMIAS

Disease is not a single result of contact between host and pathogen; it is a complex interaction between host, pathogen and environment (Snieszko 1974). Temperature is one of the key environmental parameters involved with bacterial infectious diseases (Meyer 1970). Higher levels of both water borne *A. hydrophila* and infections occur during warmer months (Davis & Hayasaka 1983; Kaper et al., 1981; Miller & Chapman 1976). Groberg and his co-workers (1978) demonstrated that higher temperatures accelerated the progress of infection by *A. hydrophila* in steelhead trout, coho salmon, chinook salmon, *Oncorhynchus tshawytscha* Walbaum, while lower temperature retarded it. Huizinga and his colleagues (1979) found that largemouth bass collected from thermally altered areas have more severe lesions than bass collected in ambient temperature locations.

## EXPERIMENTAL DESIGN

In the epizootic ulcerative disease of snakehead in the Southeast Asian Region during the last 6-7 years, one of the organisms always found involved with the diseased fish at least in the later stages is the bacterium, *Aeromonas hydrophila* (Roberts *et al.*, 1986; Tonguthai 1985 ; Llobrera & Gacutan 1987).

In order to define the pathogenesis of the *A. hydrophila* lesion in healthy snakeheads, snakehead fingerlings were injected intramuscularly with *A. hydrophila* suspension, examined sequentially over a period of 4 weeks, and the detailed histopathological changes observed.

## MATERIALS AND METHODS

### Fish

Snakehead fingerlings from a private farm at Suphanburi Province, Thailand were used as the experimental fish. The average length of the fish was 14.55 cm (12.5-16.7 cm), and twenty five of them were acclimatized in the laboratory in each glass aquaria at least 3-4 weeks before the start of the experiment. They were fed with young-live fish once per day.

### Aquaria Holding

The static water system described earlier was again used in this study. Each glass aquarium contained 150 L (100 x 45 x 45 cm) of underground water of pH 7.2-7.5, alkalinity 268-285 mg/l as CaCO<sub>3</sub>, hardness 130-136 mg/l as CaCO<sub>3</sub> . Average water temperature was 28.5° C



(28.0-29.0° C). Water was changed once daily. Air was supplied to each container by compressor throughout the experiment.

#### Experimental Infection

A virulent strain of *A. hydrophila* isolated from the kidney of diseased snakehead during the epizootic ulcerative disease in Thailand in 1983, and maintained on brain heart infusion (BHI) agar at 4° C, was used as the inoculum. Bacterial cultures were identified by the method of Bergey's manual (Buchanan & Gibbons 1974).

The strain of *A. hydrophila* used was passed through snakeheads three times to enhance virulence. The final isolate following enhancement was then cultured on BHI slant and incubated for 18-24 hr at the temperature of 30° C, and washed free of media with isotonic saline. This bacterial suspension was then prepared for use as an inoculum by adjusting with saline until the optical density (O.D.) was 0.15 at 540 nm. on a Bausch and Lomb Spectronic 20 spectrophotometer and the number of viable bacteria ( $1.57 \times 10^8$  cells/ml) was determined using the drop method (Collins & Lyne 1976).

One-tenth ml of the suspension was inoculated intramuscularly anterior to the dorsal fin above the lateral line into each snakehead. The fish were anaesthetized with 100 ppm Benzocaine. Control fish were injected with the same amount of isotonic saline. All infected fish were returned back to the aquaria for further observation.

Fish were observed daily for the appearance of clinical signs of infection through to the end of the experiment. Dead or moribund fish were removed from the containers daily.

#### Sampling Procedures

Three fish were sacrificed by 1, 2, 3, 4, 6, 8, 10, 12, 18, 24, 30, 36, and 48 hr, following by 3, 4, 5, 6, 7, 14, 21, and 28 days. Block of tissue encompassing the area under investigation were dissected out, fixed in cold 10% buffered formalin for at least 24 hr, and then processed routinely for histology. One control fish was fixed at the same time as the experimental fish for comparison.

#### Histological Procedures

The fixed tissue was trimmed into smaller blocks (0.2 x 1.5 x 0.3 cm) and processed through ascending grades of alcohols, two changes of absolute alcohol, two changes of chloroform, followed by two changes of paraffin wax (56° C melting point). The infiltrated tissue blocks were cut at 5-6 micron.

#### Staining Procedures

Haematoxylin and eosin (H&E) stained paraffin wax sections were routinely prepared. Selected sections were also stained by the methods of Gram's stain specifically for bacteria. They were mounted in permount for examination.

## RESULTS

### Gross Pathology

The infected fish stayed at the bottom of the aquarium during the first day after the injection. Their behaviour was thereafter similar to the normal fish for the rest of the experiment.

Ten minutes after the injection, the skin around the inoculated area had darkened in colour but this disappeared within one hour. By two hours there was slight swelling around the site of the injection. By 4 hours slight haemorrhage had occurred at the point of the inoculation and the scales became mildly protruded by 5 hours. Twenty four hours after the injection, the swelling was quite extensive and fluctuant. The scales showed severe protrusion and haemorrhage was located around this area.

By day 2, some fish had lost their scales at the site of injection and initial ulceration occurred. By day 3, the oval or irregular white or pale ulcerative lesion was clearly seen. The necrotic muscle at the centre of the lesion then sloughed off, and caused an open concave lesion with a haemorrhagic edge by day 4-5. The diameter of the lesion at this stage was approximately 0.5-0.7 cm. By day 6, the size of the ulcerative lesion of the infected fish was enlarged and had expanded to a diameter of around 1.0-2.0 cm.

The edge of the infectious lesion was distinct due to its dark pigmented border and the size of the lesion decreased to be 0.5-1.0 cm by day 7-10. By day

14-21 most of the experimental fish showed the black coloured area of the skin at the site of injection. The dark depressed scar was seen on the flank at the inoculated site by the end of day 28 which was the last day of this experiment. None of these changes were observed in the control fish.

#### Pathological Observations

At 1 hour the lesion was principally characterized by degeneration of sarcoplasm of myofibrils across the lesion, with loss of membrane integrity and nuclear pyknosis or karyolysis (Fig. 53). Small foci of haemorrhage were seen as well as engorged, hyperaemic blood vessels. Thrombocytes with trails of fibrin occurred around the haemorrhages or around capillaries, and the darkly staining bacterial bacilli were seen spread along these fibres or aggregated into small colonies around them.

#### 2-hours

At this stage early evidence for the leucocyte infiltration was already seen. Cells, probably, polymorphonuclear leucocytes were seen in lines adjacent to fibrin strands, possibly attracted by bacteria on them. The sarcoplasmic degeneration was more fragmented and bacteria were seen along the edge of and within the destroyed area. The bacteria had also accumulated in areas of fibrinoid infiltrate between damaged muscles, and there was a strong infiltrate of PMN's around such clusters, resulting in the equivalent of a microabscess-

most uncommon in fishes (Fig. 54, 55).

#### 3-hours

The picture over this period became more cellular, with even further increase in PMN numbers, and also numbers of bacteria, which were both within myosarcoplasma and also in the inter myofibrillar space. The blood vessels were engorged with strong evidence for margination of leucocytes and in some areas, obvious diapedesis (Fig. 56, 57).

#### 4-hours

At this stage the abscess formation was extensive, with degeneration of cells within the congery of cells, bacteria and sarcoplasm. Some large densely staining bacterial colonies were seen, and also, for the first time, small numbers of macrophages were seen in and adjacent to the damaged muscle (Fig. 58).

#### 6-hours

At six hours the lesion had started to extend from the primary focus, with white cells and bacteria seen between apparently normal fibres of adjacent areas, and particularly external areas of muscle. The dermal blood vessels were hyperaemic (Fig. 59) and the beginnings of epidermal degeneration were seen.

#### 8-hours

By the eighth hour the lesion was very active with large colonies and assemblies of bacteria and

Fig. 53. Sarcoplasmic degeneration at the injection site with focal haemorrhage at 1 hour after the bacterial injection. (H & E) X 800

Fig. 54. By 2 hours after the bacterial injection some lymphocytic infiltration with a few polymorphonuclear leucocytes (PMN) and macrophages (MC). Bacterial colonies can also be observed (arrow). (H & E) X 800


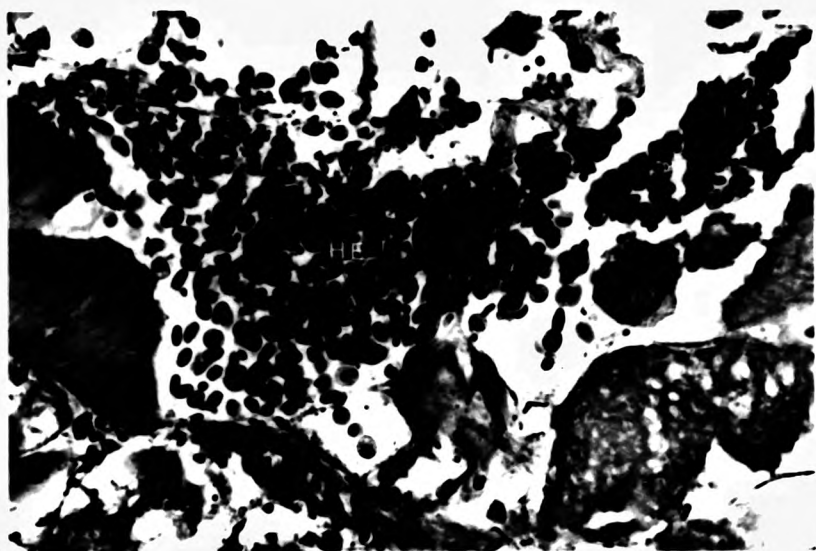




Fig. 55. Severe muscle degeneration was marked by 2 hours after the bacterial injection. (H & E) X 800


Fig. 56. Both PMN and bacterial colonies (arrow) were found within myosarcoplasma and in the intermyofibrillar space at 3 hours after the injection. (H & E) X 800





**Fig. 57. By 3 hours after the injection blood vessels were engorged with leucocytes and red blood cells. (H & E) X 800**

**Fig. 58. The junction between the area of normal and necrotic muscle bundles at 4 hours after injection. (H & E) X 400**



polymorphonuclear leucocytes in the centre and further degeneration of sarcoplasm, which was becoming pale staining, and formless, as if liquefying (Fig. 60, 61). Although very few bacteria were observed, the compactum was oedematous and had some leucocytic infiltrate, and the spongiosum was swollen and hyperaemic.

In the deeper parts of the lesions the bacteria and leucocytes often appeared to be "herded" together and contained within fibrin strands, to produce local focal aggregations, although free bacteria were still seen within this tissue (Fig. 62).

#### 10-hours

By this stage some evidence of myophagia was apparent (Fig. 63) but the lesion was still dominated by polymorphonuclear activity, which in some areas was so dense as to engulf the remains of the damaged sarcoplasm within an epithelioid cell reaction. In such areas the degree of liquefaction was then much less.

#### 12-hours

The lesion was still dominated by polymorphonuclear activity, with very little macrophage activity. There was, in focal areas, frank suppuration, where the centres of microabscesses were digested and only ghost outlines of cells or bacteria could be seen in a pink congerly (Fig. 64).

Fig. 59. By 6 hours after the injection some melanin pigments (arrow) were found around the hyperaemic blood vessels. (H & E) X 800

Fig. 60. PMN (arrow) were very obvious in the necrotic area by 8 hours after injection. (H & E) X 1600

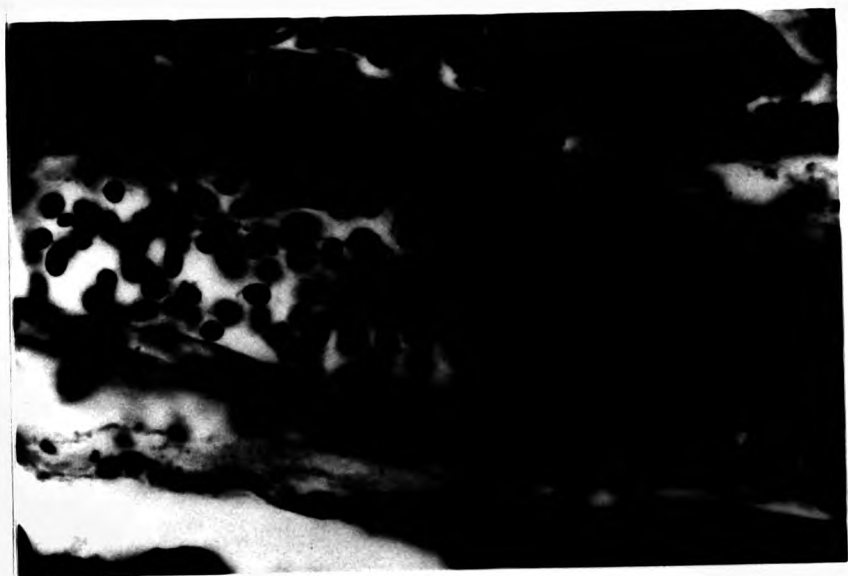

Fig. 61. By 8 hours after injection with *A. hydrophila* the degeneration of sarcoplasm with cellular debris was observed. (H & E) X 800

Fig. 62. Bacterial colonies spread throughout the myopathic area at 8 hours after injection. (H & E) X 800

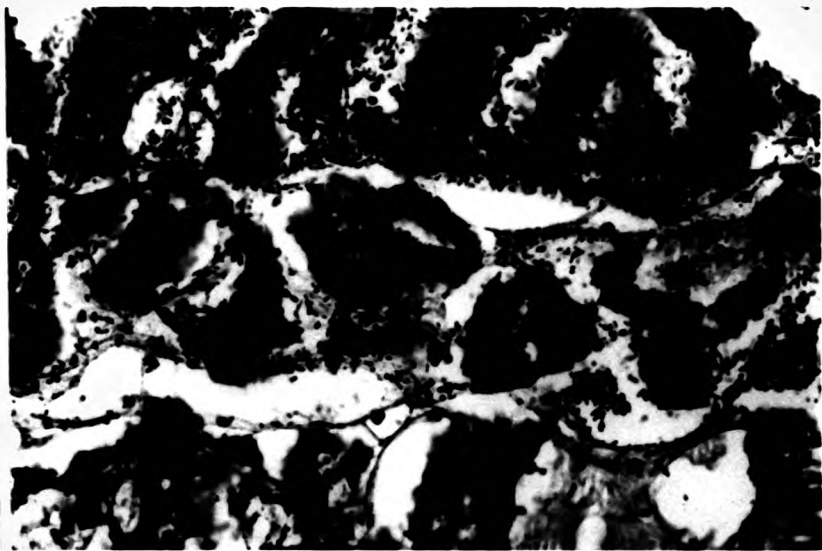

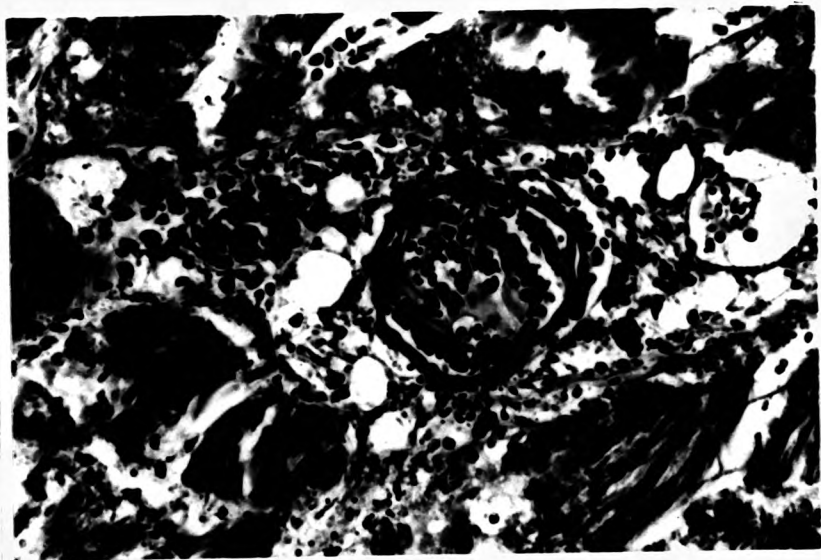





Fig. 63. By 10 hours after injection myophagia was observed. (H & E) X 800

Fig. 64. The blood vessel showing diapedesis of leukocytes and extensive inflammatory cells around the vessel at 12 hours after aeromonad injection. (H&E) X 800



#### 18 to 24-hours

There was very little change in the lesion over this period except that more bacterial colonies associated with the myonecrosis and the sarcolysis had extended significantly further towards the myotomal fascia (Fig. 65, 66). The surface was swollen due to severe inflammatory oedema in the spongiosum and compactum, but it was as yet un-ulcerated.

#### 30 to 36-hours

By this time fibroblasts had developed and appeared to encapsulate the necrosis area (Fig. 67). There were still, however, few layers of epithelioid cells developed around the infected muscle. The bacterial colonies were also still observed in the myonecrosis area. The migration of the epithelial cells from the skin at the edge of the lesion was very active and they moved down into the centre of the ulcer and separated the dead myofibrils from the normal areas, which they proceeded to cover (Fig. 68, 69, 70).

#### 42 to 48-hours

By day 2 a very dramatic and distinctive change had taken place in the lesion, with a thick ring of retaining tissue composed principally of fibroblasts and macrophages forming an investing wall around the focus of the infection, which was still largely un-altered in the centre. At the same time, at the top of the lesion, a wedge of necrotic tissue extended up into the compactum of the dermis, and into the spongiosis or actually ulcerating into the epidermis, forming an ulcer (Fig. 71, 72, 73, 74).

**Fig. 65. By 18 hours after the injection more bacterial colonies associated with muscle necrosis and cellular infiltration were observed. (H & E) X 800**

**Fig. 66. By 24 hours after the injection further sarcolysis had occurred. (H & E) X 800**



Fig. 67. Fibroblasts (arrow) developed to encapsulate the necrosis area (MN) by 30 hours after injection. (H & E) X 400

Fig. 68. Lymphocyte (arrow) accumulation and haemorrhage (H) were found at the edges of the lesion at 30 hours after injection. (H & E) X 400




Fig. 69. By 36 hours after the injection the myonecrosis had extended further towards the skin.  
(H & E) X 200 D = dermis

Fig. 70. The epithelial cells had migrated (arrow) from the skin at the edge of the lesion into the centre of the ulcer by 36 hours after the injection. (H & E) X 80  
D = dermis



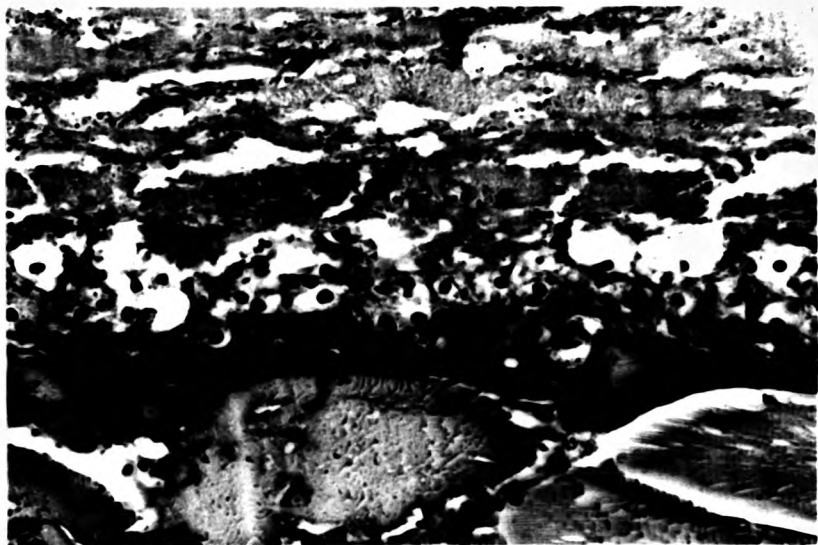

Fig. 71-72. The fibroblasts and macrophages forming an investing wall around the focus of the infection area by 36-42 hours after injection. (H & E) X 200





Fig. 73. The ring of fibroblasts and macrophages separated the necrotic material and normal muscle by 48 hours after injection. (H & E) X 800

Fig. 74. Fibrous connective tissue (arrow) surrounded the necrotic material at 48 hours after injection. (H & E) X 400



#### Day 3

By this stage the centre of the abscess, as it must be called, was filled with amorphous pink staining pus with occasional macrophages within it. The edges of the lesion had now developed a very tight fibrous encapsulation which enveloped and was tightly adherent to, normal muscle fibres on the edges.

#### Day 4

At day four the large infarcted necrotic focus that represented the abscess was enclosed in a very dense squamous epithelioid capsule, but below this was developing an extremely active, delicate macrophage layer, embedded in an argyrophilic stroma of very active fibroblasts and delicate fibres. At this stage the follicular granulomata were in the process of formation (Fig. 75) and the regenerated muscle fibres developed for the first time (Fig. 76).

#### Day 5

By this time the fibrous outer layer to the lesion was denser and very well endowed with new capillaries (Fig. 77). The abscess above it was extended to the exterior. The epidermis on either side of the defect was necrotic but still seemed to be migrating in over the edges of the defect to attempt to maintain coverage of the lesion. Many of the myofibrils on the edges, which may have been just vital, had lost all sarcoplasm and appeared as "Ghost" cells- clear structures with a delicate cell membrane, and pale nuclei but no cytoplasm.

**Fig. 75. Macrophages, containing lipofuscin in the cytoplasm (arrow), encapsulated by fibroblasts at day 4 after injection. This is an example of a follicular granuloma in the process of formation. (H & E) X 800**

**Fig. 76. Regenerating muscle fibres (NR) developing in the fibrosis area by day 4 after injection. (H & E) X 800**





#### Day 6

At this stage the pus had been expelled, and a sinus covered with inward migrated epithelium led into the depths of the lesion, which consisted only of leucocytes, with fibrosis also occurring within it. At this stage new myofibrillar buds were seen, extending, below the lesion proper (Fig. 78).

#### Day 7

By this stage, a small shrinking focus of necrotising abscessation still remained in the centre of the lesion, enclosed by a dense capsule, while the remaining area, from which this had arisen, was filled with extremely active fibroplasia, with some macrophage activity but predominantly fibroblast and capillary activity (Fig. 79).

#### Day 14

There was more dense fibrous tissue around the shrinking focus of necrotic tissue. The regenerated muscle fibres actively developed and infiltrated into the fibrous area. Focal of macrophages with lipofuscin in the cytoplasm and EGC were observed in the same area. Lymphocyte accumulation and some active macrophages were also located in the area with new capillaries as well. No bacterial colonies were observed.

#### Day 21

Muscular regeneration was almost completed and fibrous replacement with scarring of lesion area. Melanin pigment containing cells located throughout the

Fig. 77. By day 5 after the injection new capillaries (arrow) were formed in the fibrosis area at the outer layer of the lesion. (H & E) X 400

Fig. 78. Showing the new regenerating fibres buds (arrow) in the fibrosis area by 6 days after injection. (H & E) X 800



Fig. 79. Showing focal macrophages with lipofuscin in the cytoplasm (arrow) and advancing new muscle fibre regeneration (MR) at day 7 after the aeromonad injection. (H & E) X 400



healing lesions. Active macrophages were still found with the small focal of lymphocytes accumulation. The size and numbers of focal macrophages with lipofuscin in the cytoplasm were reduced.

#### Day 28

It was very difficult to locate the affected area, by this stage. The scar had joined up with the dermis, the myofibrillar regrowth was indistinguishable from normal, and the epidermis had reserved its normal form.

#### DISCUSSION

The present experimental study manifests a number of points of relevance to an understanding of the ulcerative process and cellular inflammatory response of striped snakehead associated with opportunistic pathogenic bacteria, *Aeromonas hydrophila*. It also is particularly interesting in terms of the suppurative nature of the lesion.

There is no similar study to the present one, involving the use of *A. hydrophila*. The gross pathological changes of the infected snakehead were similar to those of Klontz (1966) and Shieh (1978), in relation to *A. salmonicida* in rainbow trout. The timescales in terms of lesion development, in the snakeheads injected intramuscularly with *A. hydrophila* seem, however to be considerably faster than those of the *A. salmonicida* lesion of rainbow trout. The

darkening of the skin around the injected area in snakehead appeared and waned again within 10-60 minutes. Klontz reported the same reaction but only by 48 hours after the inoculation.

The lesion in experimental fish began to heal by day 7 to 10 and by day 14 to 24 , the healing area was distinguished grossly as being dark coloured. This contrasted with the observations of Ventura & Grizzle (1987) who induced septicaemias in channel catfish by intramuscular inoculation of a sublethal dose of *A. hydrophila*, and produced a light coloured zone at the site of injection.

The infected snakehead in this experiment never showed ascites or any evidence of the systemic infection of the internal organs which was described in the reports of Brenden and Huizinga (1986), Huizinga et al., (1979) and Ventura (1985), who found histopathological changes of the internal organs of goldfish, largemouth bass and channel catfish, respectively. This could be explained as being related to intraspecies differences of the host defence mechanisms or by variations in the virulence or dose of strains of *A. hydrophila* used in each experiment, but was more likely to be related to the different route of exposure, intraperitoneal as opposed to the intramuscular injection used in this study.

The polymorphonuclear leucocytes infiltrated into the inflammation site at the second hour after the injection and increased in numbers while the lesion progressed. These observations correlate well with the

haematological findings of Brenden and Huizinga (1986) who found marked haematological changes, especially that the PMN remained the dominant cell type throughout the sampling period in their studies on experimental haematology of *A. hydrophila* infection in large mouth bass. Nagamura and Wakabayashi (1985) also reported that PMN play a major role in primary responses against *A. hydrophila* infection in the Japanese eel, *Anguilla japonica* Temminck & Schlegel. The most unexpected finding was the bacterial accumulation in the area of the fibrinoid infiltrate between damaged muscles, and the clustering of PMN around it, resulting in the equivalent of a microabscess or pus, which is most uncommon in fish lesions. The large necrotic focus that represented the abscess was enclosed in a very dense squamous epithelioid capsule. These may represent the reason why this route of infection does not induce septicemia, as the bacteria can not develop further to the systemic stage, as all the bacterial colonies are sequestered within this granulation response at the site of infection, stimulating more PMN to migrate to the infected area.

Small numbers of macrophages were seen in the damaged muscle area by 4 hours and the leucocytes increased in number in and between apparently normal fibres of the adjacent area by 6 hours. They were not, however, principally attracted to the bacteria.

Although most bacteria were found within fibrin strands, to produce local focal aggregation, free bacteria were still seen within the lesion. These



findings were distinctly different from what had been found in the natural infection of *A. hydrophila* in snakehead (Chinabut & Limsuwan 1983a) and walking catfish (Chinabut & Limsuwan 1983b) who found no bacterial colony in damaged organs.

The histopathological changes at the site of the injection were, however, similar to those reported in brown trout (Thorpe & Roberts 1972), and goldfish (Brenden & Huizinga 1986). The severe damage to the muscle fibres at the injected area may have been caused by the enterotoxin produced by *A. hydrophila* (Kaper *et al.*, 1981). Elastase and protease are produced in vitro by this bacterium and elaboration of these enzymes in vivo may account for the progressive skeletal muscle necrosis at the site of inoculation (Brenden & Huizinga 1986). The regeneration of myofibrillar buds seen around day 6 in the area around the central of the lesion was a distinctive feature of this study but has not been described elsewhere in other species.

These findings suggest that the healthy snakehead has a well developed capacity for dealing with casual tissue invasion by *A. hydrophila*. The normal route of casual exposure in the wild is likely to be via traumatic or other damage to the skin, and not by the vascular or intraperitoneal route and it seems from this study that the snakehead is well able to respond to such infection. Why it does not, in the case of the snakehead ulcerative disease in which the type of response described above, is not found, is an important question

to be resolved.

The particularly interesting feature of this study was the dominant role of the PMN. In *A. salmonicida* infection in trout PMN only appear at the earliest stage of the infection, in this study PMN were the predominant infiltrating cells throughout the time of major activity. They contributed to the formation of abscessation in a way exactly similar to that in higher animals- a process never before described for fish.

**CHAPTER 5: EFFECT OF ACHLYA DEBARYANA INFECTION ON  
THE WOUND HEALING AND CELLULAR INFLAMMATORY RESPONSE  
OF THE STRIPED SNAKEHEAD**

## INTRODUCTION

Diseases of fungal aetiology have long been recognised in fish and the literature of fungal diseases in aquatic animals is considerable. There is little doubt that fungal infections of freshwater fish are serious problems of both natural fisheries and intensive cultivation units.

Fungal attacks on fish are very common and it is well known that whenever fish are even slightly mishandled they may well become infected with watermoulds and die. Fungal infections in fish may arise as primary infections or as secondary invasion of tissues which are already damaged by viral, bacterial or other mechanical agencies (Khulbe & Sati 1981).

Several species of watermoulds have been reported as parasites of fish by many investigators including Tiffney and Wolf (1937), Tiffney (1939 a & b), Vishniac and Nigrelli (1957), Scott and O'Bier (1962), Scott (1964), Scott and Warren (1964), Bhargava and his co-workers (1971), Srivastava (1976) and Khulbe and Sati (1981). Many of these investigators worked on either marine or freshwater tropical fishes. However, they were principally mycologists interested in the nature of the fungus species involved and so the knowledge of the inflammatory response of the fishes, especially tropical fishes, to fungal infections is still minimal.

While fungal pathogens are well recognized as secondary invaders of skin lesions in fish, their importance as primary pathogens is still debated (Neish &

Hughes 1980). Most fisheries biologists have assumed that almost all the fungal infections of fish and fish eggs are caused by the members of the genus *Saprolegnia* (Jhingran 1975). Studies made by Scott (1964), Scott and O'Bier (1962), Scott and Warren (1964), Srivastava (1976), Tiffney and Wolf (1937), and Vishniac and Nigrelli (1957) however, have shown that other members of the Saprolegniaceae are equally involved in infection of fish and their eggs. There are 17 genera in the Saprolegniaceae (Sparrow 1960) such as *Saprolegnia*, *Achlya*, *Dictyuchus* etc. A number of species of the phycomycete *Achlya* have been recorded to be pathogens of fishes (Jha et al., 1977; Scott 1964; Tiffney 1939 a, b; Vishniac & Nigrelli 1957).

In the course of the studies by Roberts and his colleagues (Roberts et al., 1986; Tonguthai 1985) on epizootic ulcerative disease of snakehead and other fish species in South East Asian countries, regular observations were made on the presence of *Achlya* spp invading the tissues of affected fishes. There was generally little or no inflammatory response to such invasion. It was considered valuable therefore to study the response of healthy snakeheads to such fungal hyphae in order to determine whether indeed it is able to multiply in fish tissues without inciting a response. This study represented an attempt to determine this response in the normal snakehead.

## REVIEW OF THE LITERATURE

## GENERAL INFORMATION ON SAPROLEGNIASIS

Saprolegniasis is a term frequently used to describe fungal infection of skin and gill. It may involve any of a wide variety of fungi of the order Saprolegniales. Members of the family Saprolegniaceae which have been recorded as parasitic in fish are *Saprolegnia*, *Achlya*, *Aphanomyces*, *Dictyuchus*, *Pythium*, *Leptolegnia*, and *Leptomites* (Alderman 1982).

The Saprolegniaceae are water moulds possessing a profusely branched, non-septate mycelium. They are commonly found in freshwater but members of the Saprolegniaceae are also commonly found in brackish estuarine waters. Salinities higher than 2.8‰ however, limit their distribution (Testrake 1959). Reproductive structures are separated from somatic hyphae by septa and asexual reproduction is by means of biflagellate zoospores (Roberts 1978). Most genera of the family Saprolegniaceae can be identified from hyphal characteristics, the nature of the zoosporangium and subsequent spore release but identification of the different species has traditionally depended on characteristics of the oogonia and antheridia (Alderman 1982).

## EXPERIMENTAL STUDIES ON SAPROLEGNIAEAE

*Saprolegnia* infections have been recognised in fish for many years. The first extensive studies were in relation to the salmon disease now recognised as ulcerative dermal necrosis (UDN) and considerable studies were carried out in the 1870's (Buckland *et al.*, 1880). The definitive work on the fungus was that of Coker (1923) and a number of studies appeared thereafter (Reviewed by Neish & Hughes 1980). The first significant study on the pathogenesis of the infection, however was that of Tiffney (1939 a) who demonstrated the ability of *Saprolegnia parasitica* to parasitize a wide range of fish and amphibian species. His experiments also revealed varying degrees of resistance to fungal infection among different hosts. Experimentally wounded fish appeared to be considerably more susceptible to infection than those not wounded. Primary saprolegniasis has been reported by Hoshina and Ookubo (1956) and Hoshina and his colleagues (1960) in cultured eels without any visible prior injury to the fish but this is questioned by others. In addition Tiffney (1939 b) isolated numbers of *Achlya* from various living fish, amphibians and reptiles in nature.

Vishniac and Nigrelli (1957) observed a leucocytic and melanocytic response to experimental infections with *Saprolegnia spp* and *Achlya spp* in platyfish.

Scott and Warren (1964) reported that *Achlya americana* showed no specificity in attacking fish. Hyphae of the parasite could be observed macroscopically,

growing from the injured areas of experimentally wounded specimens of small tropical fish within 7 to 10 hours after placing the fish in infection dishes, and all injured hosts died within 24 hours. Only two of the eight unwounded fish developed mycoses and died. They concluded that certain saprolegniaceous fungi were primary wound invaders and lethal pathogens of various fish species. Similar observations were reported by Khulbe and Sati (1981) who found that *A. americana* had infected injured areas of experimental temperate fish within 12 to 18 hours after inoculation.

Davis and Lazar (1940) found that fungal infection in rainbow trout fingerlings first developed in the lumen of the stomach and intestine and later grew out through the wall of the digestive tract into the body cavity, eventually tracking to the exterior through the body wall after the death of the fish.

Pickering and Willoughby (1977) found *Achlya* tending to dominate the more advanced ulcers of an epidermal lesion on perch, *Perca fluviatilis* L.

Srivastava & Srivastava (1977 a,b) reported that *Achlya prolifera* was capable of parasitising a wide range of scaly fishes. A marked difference in the resistance of difference species to attacks by this mould were observed. The non-scaly fish, *Mystus tengara* (Ham.) appeared to be immune to the fungus. Another observation was that the fish which ate the mycelial mat of the fungus did not show any intestinal infection by the mould.



Sohnle and Chusid (1983) reported that healthy rainbow trout were quite resistant to infection by opportunistic fungi of the family Saprolegniaceae. They occasionally found that the inflammatory cells were present around the fungal hyphae. They also found that fungus was unable to grow in live fish tissue but grew well in tissue of dead fish, where an inflammatory infiltrate was not present.

Examination of the muscle underlying sites of inoculation of fish at 24 to 72 hours showed an infiltrate containing neutrophils and macrophages (Nolard-Tintigner 1973; Wolke 1975). However, in some fish infected with saprolegnias, there was no inflammatory response in the musculature (Bootsma 1973). Pickering and Richards (1980) confirmed that inflammatory response in fungal infected dermal lesions were generally absent unless a dermal bacterial infection also developed.

Singhal and his colleagues (1987) reported that during the early periods of *Saprolegnia* complex and *Achlya racemosa* infection the fish showed no apparent changes in behaviour but in the later stages when the gills were covered and clogged, the fish came to the surface of the water to gulp air. Fungi were transmitted to healthy fish directly, by intramuscular injection, and the time taken for the disease to be detectable in injected fish was 8 to 10 days.

Noga and Dykstra (1986) suggested that the *Saprolegnia* fungi were actively contributing to the

pathogenesis of epidermal lesions and may be responsible for initiating the ulcers.

Richards and Pickering (1978) reported that in both sexes of brown trout, the areas most vulnerable to *Saprolegnia* infection appear to be along the leading edges of the fins.

#### TEMPERATURE AND FUNGAL INFECTION

Temperature has a significant effect on the development of fungal infections. Whilst infection following trauma may occur at any temperature compatible with fish life, most epizootics occur when temperatures are low for the particular species (Roberts 1978). The fungi of the family Saprolegniaceae normally grow much more rapidly at temperatures higher than those usually encountered by trout, although they do grow, albeit very much but more slowly, at temperatures near the freezing point of water (Sohnle & Chusid 1983).

Hoshina and Ookobo (1956) and Hoshina *et al.*, (1960) pointed out that saprolegniasis of eels ceased when the water temperatures rose above 18° C. However, the stress of high temperature may also on occasion induce fungal invasion. Roth (1972) noted that fungal infection in experimental white suckers, generally took place when temperature exceeded 10° C. Neish (1976) found that both hyphal growth and zoospore production by the fungus decreased with decreasing temperature, but it would seem from the evidence above that despite this lower growth and reproduction rate of the fungus, low

temperature reduced the resistance of the host so much that even small numbers of zoospores can initiate infection.

#### FUNGUS TOXICITY

It does not appear likely that saprolegnian fungi produce any toxins (Nolard-Tintigner 1973; Peduzzi *et al.*, 1976). The damage done by these fungi can be directly related to a chymotrypsin-like enzyme activity (Peduzzi *et al.*, 1976; Peduzzi & Bizzozzero 1977). The time of death will be a function of the growth rate of the fungus, the initial site of infection, the type and quantity of tissue destroyed and the ability of the individual fish to withstand the stress of the disease (Neish & Hughes 1980).

#### THE BIOLOGY OF THE ACHLYA

Fungi of the genera *Achlya* are among the most important in fish pathology. A number of species of *Achlya*, including *A. bisexualis*, *A. americana*, (cf *A. debaryana* see below) (Jha *et al.*, 1977; Scott 1964; Tiffney 1939 a; Vishniac & Nigrelli 1957), *A. racemosa* (Shah *et al.*, 1977) has been recorded to be a pathogen of fish. In the majority of cases the infection has arisen from secondary invasion of open wounds on the body of the fish (Neish & Hughes 1980).

The genus *Achlya*, comprising somewhat over a hundred taxa, is the largest genus of the

Saprolegniaceae. *Achlya prolifera* is the type species of the genus, and is designated as the nomenclatured type (Johnson 1956). They belong to the class Oomycetes, Order Saprolegniales and family Saprolegniaceae (Neish & Hughes 1980).

The thalli of members of the genus *Achlya* consist of coenocytic aggregations of hyphae, the walls of which show a reaction of unmodified cellulose upon treatment with chloriodide of zinc. The vegetative mycelium consists of two components, the substrate penetrating rhizoidal or holdfast system, and the emergent or hyphal system. Septa are normally formed in the hyphae only to delimit the organs of asexual reproduction, zoosporangia and gemmae, and the sexual reproductive bodies, the oogonial and antheridial cells (Johnson 1956). In the genus *Achlya*, the spores encyst at the mouth of the sporangium where they form a hollow ball. There is no free swimming primary zoospore. Secondary zoospores emerge from the cysts at the mouth of the sporangium (Neish & Hughes 1980).

*Achlya debaryana* Humphrey

This species, virtually synonymous with *A. polyandra* (de Bary's) and very closely similar to *A. americana* (Johnson 1956) was the species used in the study described below. According to Johnson (1956) its features are as follows: main hyphae stout usually ending in primary sporangia under which the secondary ones appear in sympodial arrangement. Oogonia short-stalked, racemously arranged, seldom intercallary, and often

terminal on slender hyphae; wall stout here and there with somewhat thinner places but not pitted, occasionally with a few wartlike projections. Antheridial branches almost always androgynous, much contorted and branched, arising from the same principal axes which bear the oogonia, but never from the oogonial stalks. Antheridial cells on the branched types of the antheridial branches, attached by their sides to the oogonia and sending into them one or two fertilizing tubes. Oospores varying in number, but mostly numerous; eccentric.

*Achlya debaryana* is remarkably similar to *A. americana*, a species from which it differs principally on the basis of pitted oogonia, as contrasted with the unpitted oogonia of *A. debaryana*.

#### EXPERIMENTAL DESIGN

Numerous accounts have appeared in the literature of the infection of fishes by saprolegniaceous fungi. These fungi are found to infect the eggs, fry, fingerlings and adult fish. Generally the fungal infection starts when the host is injured either mechanically or as a result of non fungal infections (Srivastava 1980 a,b). Such infections usually result in high mortality rates in fish populations.

Fungal infection has been involved with the outbreak of fish disease in the Southeast Asian Region (Tonguthai 1985; Roberts *et al.*, 1986). Pure isolates of *Achlya sp* were the only fungal species found from the lesions of diseased fish. *Saprolegnia sp* and other genera which have been recorded as pathogenic in many such fishes were not found to be involved at all in this event (Pichyangkura 1987).

To determine the standard histopathological response to the presence of the *Achlya* hyphae and zoospores in tissues, healthy snakehead fingerlings were inoculated with *Achlya debaryana* zoospore solution intramuscularly above the broken lateral line, and examined sequentially over a period of 7 days. The cellular inflammatory response and histopathological changes were observed and discussed.

## MATERIALS AND METHODS

### Fish

Young healthy snakeheads were obtained from a private farm in Suphanburi province, Thailand. The average length of the experimental fish was 10.0 cm (10.0-13.5 cm). The fish were reared at the National Inland Fisheries Institute laboratory in glass aquaria. They were fed with live fish fry once a day. The fish were acclimatized to the laboratory conditions for 3-4 weeks before the experiment started.

### Aquaria Holding

Snakehead fingerlings were stocked in 150 L glass aquaria (100 x 45 x 45 cm), containing static underground water of pH 7.1-7.4, alkalinity 270-290 mg/L as CaCO<sub>3</sub>, hardness 130-136 mg/L as CaCO<sub>3</sub>. Average water temperature was 28.0° C (26.0-30.0° C). Aeration was supplied via a compressor and air-stone throughout the experiment. Water was changed once daily.

### Preparation of Inocula

*Achlya debaryana* culture was obtained from the Institute of Aquaculture, University of Stirling. The subculture was grown on River Glucose Yeast (RGY) agar for 7-9 days before the inoculation.

Using sterile scissors and forceps, *A. debaryana* mycelial growths including the sporangia were trimmed off culture plates and transferred to separate vials of 5 ml sterile distilled water. The presence of motile secondary zoospores were confirmed under the light microscope.

### Injection

A total of 40 anaesthetized snakehead fingerlings were injected intramuscularly above the dropping abruptly lateral line with 0.1 ml of the prepared inoculum, containing the *Achlya* zoospores. The same volume of sterile distilled water was injected in the same way as in experimental fish into 11 fish acting as controls.

### Sampling Procedures

Experimental fish were examined regularly for behavioural changes after the injection. Three fish were sacrificed at 1, 6, 12, and 24 hours, then every day for 7 days after inoculation, for the histological observation.

### Fixation and Staining for Histology

The blocks of muscle at the injected site were fixed in cold 10% buffer formalin for 24 hours. The blocks of tissue were trimmed into a smaller size (0.5 x 0.7 x 0.2 cm) and dehydrated through decreasing alcohol series, two changes in absolute alcohol, chloroform, and paraffin wax, then embedded in paraplast. The tissue blocks were cut at 5-6 micron and stained with standard haematoxylin and eosin (H&E), PAS (Periodic Acid-Shiff), GMS (Grocott's Methanamine Silver method). A detailed record of the sequential pathology of the infected fish was obtained.



## RESULTS

There was no clinical evidence of any change in the external appearance of the lesion in the experimental snakehead fingerlings injected with *A. debaryana*.

### Histopathological Observations

#### 1 hour

At this early stage the myotomes were damaged immediately at the injection site with loss of striations and rupture of sarcolemmæ and endomysia caused by the trauma of injection. There were mild haemorrhages and slight hyperaemia of blood vessels at the edges of the lesion.

#### 6-12 hours



By six to twelve hours, there was some infiltration of polymorphonuclear leucocytes and lymphocytes in between the necrotic myofibres. The sarcoplasmic degeneration was increased and spread through the lesion. There was marked diapedesis of leucocytes from blood vessels (Fig. 80, 81).

#### 1 day

At this stage the lesions were similar and small numbers of macrophages were observed in the inflammatory area and adjacent to the degenerate muscle bundles. Small foci of haemorrhage were seen throughout the infected site. There were some melanin granules

**Fig. 80. Damaged myotomes 6 hours after the fungus injection. (H & E) X 800**

**Fig. 81. Infiltration of PMN, macrophages (MC) and lymphocytes (LM) between the necrotic myofibres at 12 hours after injection of fungus. (H & E) X 800**



accumulated near the blood vessels around the necrotic area (Fig. 82).

#### 2 days

The lesion was still dominated by macrophage activity with very little evidence of PMN's. The necrotic myofibrils were spread throughout the lesion. Small numbers of fibroblasts had migrated into the inflammatory site (Fig 83, 84).

#### 3 days

By this stage there was some evidence that more fibroblasts had infiltrated into the infected area to substitute for the host myopathic fibrils which were at the centre of the lesion. There were some lymphocytes found at the edge of the necrosis area and new capillaries were growing into the inflammatory area.

#### 4 days

By day 4, the lesion appeared to have been clearly circumscribed. A very distinctive muscle regeneration had taken place in the lesion with some new formation of capillaries (Fig. 85). The phagocytic macrophages were now only found in the small area of necrotic muscle fibres. Small haemorrhages were present between the muscle fibres and cellular infiltration of muscle fibres was more pronounced.

#### 5 days

By this time the lesions were almost free of necrotic muscle fibres. There were some macrophage

Fig. 82. Small numbers of macrophages were observed adjacent to the degenerated muscle bundles at 24 hours after injection. (H & E) X 800

Fig. 83. By 48 hours after injection the necrotic myofibrils were increased with dominant active macrophages (MC) and some fibroblasts (arrow). (H & E) X 800



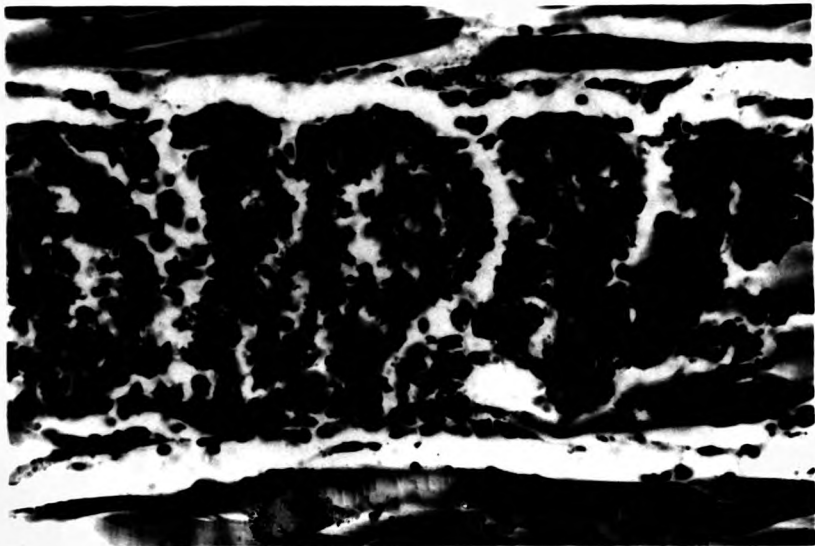


Fig. 84. Myophagic macrophages 2 days after fungal injection. (H & E) X 800

Fig. 85. Muscle regeneration (MR) development taking place in the lesion 4 days after injection. (H & E) X 800





centres with lipofuscin accumulated in the cytoplasm of the macrophages, regenerated muscle fibres and fibrous connective tissues (Fig. 86).

6 days

By this stage the histology at the injected site was virtually like the control fish.

#### DISCUSSION

The present study indicated that healthy snakeheads have an active defence mechanism which may employ inflammatory cells, such as polymorphonuclear leucocytes and macrophages, and chronic inflammatory processes such as fibrosis in the defence against *A. debaryana* infection. This defence also involves destruction of the zoospores of the fungus which is initiated by an extracellular mechanism. The cellular inflammatory response of the snakehead to fungus infection was very mild. This agrees with the report of Corbell (1975) that the cellular response to mycotic infection in fish is quite varied, ranging from granulomata formation to complete absence of response.

The myofibrillar lesions produced at the early stages of the infection may be the effect of the traumatic activity of the injection and the zoospore activity (McQueen *et al.*, 1973). Recent work has suggested that the surface damage caused by *Saprolegnia* infection may relate to a chymotrypsin-like enzyme activity (Peduzzi *et al.*, 1976; Peduzzi & Bizzozero 1977).

Fig. 86. By 5 days after the injection some macrophage centres with lipofuscin accumulated (arrow) were found in the area of muscle regeneration. (H & E) X 800



This may explain the local acantholysis occurring around fungal hyphae in the early stages. If such enzymes are also produced by *Achlya* it might help explain the local tissue damage.

A few polymorphonuclear leucocytes and lymphocytes appeared in the inflammatory area around 6-12 hours. Macrophages had migrated to the necrotic area by the end of day one and they increased in numbers by day 2, about the same time as the total number of PMN decreased.

Lymphocytes were still found at the edge of the necrotic site by day 3. No explanation for the appearance of lymphocytes so soon after injection is available. In the adjuvant study ( Chapter 3 ) lymphocytes, presumably associated with cell mediated immunity, did not appear until much later in the disease process.

The fibrosis and new blood capillaries were found on day 3 and the muscle regeneration was recognized by day 4. The reparative rate of the lesion was very rapid so the infected site became normal as in the control fish by around day 6.

There were some macrophage centres with lipofuscin-like material in the cytoplasm at the healing site by the 5<sup>th</sup> day.

In the present study no zoospore or fungal hyphae grew in the lesion. This supported Sohnle & Chusid (1983) who reported that Saprolegneaceae fungus was unable to grow in live fish, but grew quite readily

in dead fish tissues. Copeland & Willoughby (1982) suggested that the external environment provided a better growth medium to fungus than the oedematous and degenerative tissues at the site of infection. The possible explanation for this may be the higher level of oxygen and other nutrients in the water compared to the level in necrotic area, and Liu & Volz (1976) also reported that low oxygen levels is one of the major limiting factor for the growth of fungus.

It is apparent from the results of the present study that healthy snakehead are quite resistant to opportunistic fungal infection by the species *Achlya debaryana*. *Achlya* fungus may be a very host specific pathogen (Scott & Warren 1964) but this seems an unlikely explanation for the failure to demonstrate fungal growth. Much more likely is that the *Achlya* fungi cannot grow in the depths of healthy tissue but only on necrotic external ulcerated areas. These findings may supported by the results of Sohnle & Chusid (1983) who reported that healthy rainbow trout were able to resist infection after inoculation with Saprolegneaceae fungi, even at very cold temperatures (2-4 °C).

**CHATER 6: GENERAL DISCUSSION**

The experiments described in this study were established in order to attempt to define the range and type of inflammatory responses which the striped snakehead can make to various noxious stimuli. These were as far as possible standard stimuli against which the response of other groups of fishes was already defined or else responses to agents associated with aspects of the epizootic ulcerative disease of rice field fishes which is currently spreading through the South East Asian Region. Clearly these responses were those of healthy fish, and represented a range of responses which may not be possible in the fish affected with that disease, but it is an important contribution to know the basic corpus of changes that can take place in normal fish.

All of the experiments conducted to stimulate cellular response of striped snakehead demonstrated similar patterns of response but the degree or time scale of the response and the ultimate result was different depending on the types of stimulus.

Freund's complete adjuvant or *Achlya* injection and surgical wounding of snakehead did not develop to ulceration or the darkened skin scar which was characteristic of the *Aeromonas* injected snakehead. This is possibly largely because the traumatic injury from the needle insertion or sharp blade did not cause much damage to the melanin pigment containing cells in the epidermis, but the ulcerative lesion caused by *Aeromonas* infection caused severe damage to those cells.

Epithelialization in the surgical incision used as a model for wound healing in the snakehead was complete within 2-3 hours, a most remarkable rate of cell migration and very much faster than that observed by Bullock and his co-workers (1978) in the temperate species. It took 6-7 days for the ulceration produced by *Aeromonas* infection to heal. This difference in time scales can probably be explained in part by the larger size of the lesion but much more significance is probably due to the toxin produced by the *Aeromonas* which caused severe damage and a large open wound. This is similar to the findings of Bullock and Roberts (1980) who showed that the presence of pathogenic bacteria on the surface of the ulcer completely inhibited any migration of peripheral epidermal cells.

Macrophages were found in the inflammatory area of the incision wound and Freund's complete adjuvant infected snakehead 2-3 hours after stimulus which was much faster than in the *Aeromonas* (8 hours) and *Achlya* (24 hours) infected fish. Small numbers of macrophages were involved in the *Aeromonas* infected lesion in comparison with the other experiment in this study.

Results from this present study suggest that macrophages play an important role in the inflammatory response of snakeheads against injury or pathogenic infection. Macrophages are considered to be the effector cells in non-specific immunity because they are active against a wide array of microorganisms including viruses, bacteria, fungi and protozoa (Allison 1978), and because



when their function is impaired, resistance to disease is decreased (Oliver *et al.*, 1985). More importantly however, macrophages are phagocytic to any particle foreign to the body and particularly to damaged host cells, so that debridement of the wound area and removal of damaged tissue which is essential to repair, is entirely due to their activities.

Polymorphonuclear leucocytes were found in the early stages of the wounded, Freund's complete adjuvant and *Achlya* infected snakehead and disappeared very soon after their first appearance. No obvious role was apparent for them in these cases. In *Aeromonas* infection on the other hand, the PMN were very active from the early stages and seem to be the major responsible leucocyte in the bacterial infection area. Many reports indicated *A. hydrophila* produced toxic substances (Wolke 1975; Huizinga *et al.*, 1979; Wakabayashi *et al.*, 1981; Kanai & Wakabayashi 1984), which may stimulated PMN infiltration (Nagamura & Wakabayashi 1985).

The role of the PMN in fishes has been questioned by many authors (e.g. Klontz 1966; Roberts 1978) and generally it is assumed that PMN leucocytosis, suppuration and abscess formation do not occur in fishes. However, in this particular case there can be no doubt that PMN activity, leading to typical suppuration and abscessation was a very marked feature of the response of the snakehead to this particular insult. It may be that the route of infection, and the form in which the

bacteria were presented were not typical of a normal pathological process, for fish. There can be no doubt, however that the development of an abscess is certainly one option for the snakehead in its response to bacterial pathogens. A study of the effects of exposing other species to this form of insult would prove whether the snakehead is unusual in this respect.

Timur G. (1975) and Finn & Nielson (1971 a,b) who studied chronic inflammation in plaice and rainbow trout, respectively, did not mention any occurrence of melanin pigments or eosinophilic granular cells in the granulomatous lesion produced. This was a major difference to the results of this study. Numbers of melanin pigmented cells and EGC's were found around the granuloma especially in the later stages of the granulation development. This finding, conversely, was not observed in the *Aeromonas* experiment and only mild melanization was found in the inflaming sites of wounded and *Achlya* experimental fish. Melanization and EGC formation is of course more frequently involved with chronic inflammation than acute.

The involvement of melanin containing cells in the encystment response to metacercaria in plaice has been described by McQueen and his co-workers (1973). Similarly EGC's have been reported in the tissue of parasitised fish (Lester & Daniels 1976; Reimschuessel et al., 1987; Roberts 1978), and in fish exposed to insecticide (Matthiessen & Roberts 1982). The EGC is however a cell about which little is known, and so its

role in this case can only be speculative.

Giant cells were found only in Freund's complete adjuvant injected snakehead which confirmed that the formation of giant cells is definitely associated with the chronic lesion where a balance between infection and resistance has been established (Medlar 1926). The exact role of giant cells in fishes is still unclear, Secombes (1985) found that giant cells were capable of phagocytosis, but had a lower phagocytic performance than macrophages.

Vascularization, myofibrillar regeneration and fibrosis development in the experimental snakehead were very rapid. These findings help explain why the lesion of snakehead healed and returned to the normal condition so quickly if they were kept in non-stressed condition. Snakeheads are, of course, fish which live in a very hostile environment both microbiologically and predator-wise, so rapid wound healing is particularly important.

The results of this study show strong general similarity yet distinct detail differences, in the response of the snakehead to inflammatory stimuli, when compared with other fish species.

The histopathological response described in ulcerated snakehead in the epizootic condition is very different from that observed in the present case (Roberts et al., 1986). It is obvious that the healthy snakehead can mount a most effective and rapid response both in terms of localization and healing, to the various types of ulceration, tissue damage and secondary pathogenic

invasion seen in snakeheads with ulcer disease. The failure to mount such responses in that disease may well therefore represent a suppressive feature of the rhabdovirus which is often associated with the condition rather than an intrinsic inability of the snakehead to deal with such pathogens.

**REFERENCES**

- Agius, C. and Agbede, S.A. 1984. An electron microscopical study on the genesis of lipofuscin melanin and haemosiderin in the haemopoietic tissue of fish. *J. Fish Biol.* 24:471-488.
- Al-Hassan, J.M. 1983. Accelerated wound healing by a preparation from skin of the Arabian Gulf catfish. *The lancet* No. 8332:1043-1083.
- Al-Hassan, J.M., Thomson, M., Criddle, K.R., Summers, B., and Criddle, R.S. 1985. Catfish epidermal secretions in response to threat or injury: a novel defense response. *Mar. Biol.* 88(2):117-124.
- Aldaba, V.C. 1931. The dalag fishery of Laguna de Bay. *Phil. J. Sci.* 45(11):41-61.
- Alderman, D.J. 1982. Fungal disease of aquatic animals. In: *Microbial Diseases of Fish*. Ed. R.J. Roberts. Academic Press, London. 189-242 pp.
- Alexander, D.M. 1913. A review of piscine tubercle, with a description of an acid-fast bacillus found in the cod. *Trans. Liverpool Biol. Soc.* 27:219-226.
- Alikunhi, K.H. 1953. Notes on the bionomics, breeding and growth of the murrel, *Ophicephalus striatus* Bloch. *Proc. Indian Acad. Sci. B.* 38:10-20.
- \_\_\_\_\_ 1957. Fish culture in India. *Fm. Bull. Indian Coun. agric. Res.* 20:144
- Allison, A.C. 1978. Macrophage activation and non-specific immunity. *Intl. Rev. Exptl. Pathol.* 18:303
- Amlacher, E. 1961. *Taschenbuch der Fischkrankheiten*. Jena, Gustav Fischer Verlag. 286 p.
- \_\_\_\_\_ 1970. *Text Book of Fish Diseases*. T.F.H. Publish, Jersey U.S.A. 117-135 pp.
- Anderson, C.D. and Roberts, R.J. 1975. A comparison of the effects of temperature on wound healing in a tropical and a temperate teleost. *J. Fish Biol.* 7:173-182.
- Andrews, J.W. and Murai, T. 1975. Studies on the vitamin C requirements of channel catfish (*Ictalurus punctatus*). *J. Nutrition.* 105:557-561.
- Aoki, T., Egusa, S., Ogata, Y., and Watanabe, T. 1971. Detection of resistance factors in fish pathogen *Aeromonas liquefaciens*. *J. Gen. Microbiol.* 65:343-349.

- Aoki, T., Egusa, S., Yoda, C. and Watanabe, T. 1972. Studies of drug resistance and R factors in bacteria from pond-cultured Salmonids. Jpn. J. Microbiol. 16:233-238.
- Aoki, T., Egusa, S. and Watanabe, T. 1973. Detection of R+ bacteria in cultured marine fish, Yellowtails (*Seriola quinqueradiata*). Jpn. J. Microbiol. 17:7-12.
- Arey, L.B. 1936. Wound healing. Physiol. Rev. 16:327-406.
- Aronson, J.D. 1926. Spontaneous tuberculosis in saltwater fish. J. Infect. Dis. 39:315-320.
- Arumugam, T.M. 1966. Murrel culture as a commercial fishery in Madras State. Madras J. Fish. 2:54-63.
- Ashley, L.M., Halver, J.E. and Smith, R.R. 1975. Ascorbic acid deficiency in rainbow trout and coho salmon and effects on wound healing. In: The Pathology of Fish. Ed. W.E. Ribelin & G. Migaki. The university of Wisconsin Press. 769-778 pp.
- Atkinson, H.M. and Trust, T.T. 1980. Haemagglutination properties and adherence ability of *Aeromonas hydrophila*. Infect. Immun. 27:938-946.
- Bach, R., Chen, P.K. and Chapman, G.B. 1978. Changes in the spleen of the channel catfish *Ictalurus punctatus* Rafinesque. induced by infection with *Aeromonas hydrophila*. J. Fish Dis. 1:205-217.
- Bagnara, J.T. and Hadley, M.E. 1973. Chromatophores and color change. Prentice Hall, New Jersey. p.4
- Banerjee, S.R. 1974. Hypophysation and life history of *Chana punctatus* (Bloch). J. Inland Fish. Soc. India. 6:62-73.
- Barber, D.L. and Westermann, J.E.M. 1978. Occurrence of the periodic acid-Schiff positive granular leucocyte (PAS-GL) in some fishes and its significance. J. Fish Biol. 12:35-43.
- Bardach, J.E. and Atema, J. 1971. The sense of taste in fishes. In: Beidler, L.M. (Ed.), Handbook of Sensory Physiology. Vol.IV/2, Taste. Springer, Berlin-Heidelberg-New York, 293-336 pp.
- Becker, J. 1942. Die Abwehreinrichtungen von Haut und Kiemen beim Karpfen gegenüber mechanischen, chemischen und parasitären Reizen. Int. Rev. Hydrobiol. 41: 266-344.

- Bhargava, K.S., Swarup, K. and Singh, C.S. 1971. Fungi parasitic on certain fresh water fishes of Gorakhpur. *Indian Biologist*. 3:65-69.
- Bhattacharya, R.N. 1946. On the life history of *Ophicephalus striatus* Bloch. *Sc. Cong. Part III Abstracts*.
- Bisset, K.A. 1946. The effect of temperature on non-specific infections of fish. *J. Path. Bact.* 58:251-267.
- Bootsma, R. 1973. Infections with *Saprolegnia* in pike cultures (*Esox lucius* L.). *Aquaculture*. 2:385-394.
- Boulanger, S., Lallier, R. and Cousineau, G. 1977. Isolation of enterotoxigenic *Aeromonas* from fish. *Can. J. Microbiol.* 23:1161-1164.
- Bradshaw, C.W., Richard, A.S. and Sigel, M.M. 1971. IgM antibodies in fish mucus. *Proc. Soc. exp. Biol. Med.* 136:1122-1124.
- Braun-Nesje, R., Bertheussen, K., Kaplan, G. and Seljelid, R. 1981. Salmonid macrophages: separation, in vitro culture and characterization. *J. Fish Dis.* 4:141-151.
- Bremer, H. 1972. Histochemistry of the secretory elements of the teleost epidermis. *Acta Histochem.* 43:28-42.
- Brenden, R.A. and Huizinga, H.W. 1986. Pathophysiology of experimental *Aeromonas hydrophila* infection in goldfish, *Carassius auratus* (L.). *J. Fish Dis.* 4:163-167.
- Brown, G.A. and Wellings, S.R. 1969. Collagen formation and calcification in teleost scales. *Z. Zellforsch.* 93:571-582.
- . 1970. Electron microscopy of the skin of the teleost *Hippoglossoides ellassodon* L. *Z. Zellforsch. mikrosk. Anat.* 103:149-169.
- Buchanan, R.E. and Gibbons, N.E.(ed.) 1974. *Bergey's Manual of Determinative Bacteriology*, 8th edition. Williams and Wilkins Company, Baltimore, U.S.A. 1268 pp.
- Buckland, F.S., Walpole, S. and Young, A. 1880. Report on the disease which has recently prevailed among the salmon in the Tweed, Eden and other rivers in England and Scotland. (C-2660), H.M.S.O., London. 125 pp.



- Buckley, J.T., Halasa, L.N., Lund, K.D. and MacIntyre, S. 1981. Purification and some properties of the hemolytic toxin aerolysin. *Can. J. Biochem.* 58:430-435.
- Bullock, A.M., Marks, R. and Roberts, R.J. 1978. The cell kinetics of teleost fish epidermis: Epidermal mitotic activity in relation to wound healing at varying temperatures in plaice (*Pleuronectes platessa*). *J. Zool., Lond.* 185:197-204.
- Bullock, A.M. and Roberts, R.J. 1975. The dermatology of marine teleost fish. I. The normal integument. *Oceanogr. Mar. Biol. Ann. Rev.* 13:383-411.
- 
- \_\_\_\_\_. 1980. Inhibition of epidermal migration in the skin of rainbow trout, *Salmo gairdneri* Richardson in the presence of achromogenic *Aeromonas salmonicida*. *J. Fish Dis.* 3:517-524.
- Bullock, G.L. 1961. The identification and separation of *Aeromonas liquefaciens* from *Pseudomonas fluorescens* and related organisms occurring in diseased fish. *Appl. Microbiol.* 9:587-590.
- Bullock, G.L., Conroy, D.A. and Snieszko, S.F. 1971. Bacterial Diseases of fish. (Ed). S.F. Snieszko & H.R. Axelrod, T.F.H. Publications, Jersey City. 105-112 pp.
- Burke, J. and Rodgers L. 1981. Identification of pathogenic bacteria associated with the occurrence of red spot in sea mullet, *Mugil cephalis* L., in south eastern Queensland. *J. Fish Dis.* 4:153-159.
- Burns, J.J. 1957. Missing step in man, monkey and guinea pig required for the biosynthesis of L-ascorbic acid. *Nature.* 180:553.
- Burton, D. 1978. Melanophore distribution within the integumentary tissues of two teleost species, *Pseudopleuronectes americanus* and *Gasterosteus aculeatus* from *leirus*. *J. Can. Zool.* 56:526-535.
- Cameron, A.M. and Endean, R. 1973. Epidermal secretions and the evolution of venom glands in fishes. *Toxicon.* 11:401-410.
- Cannon, M.S., Mallenhauer, H.H., Eurell, T.E., Lewis, D. H., Cannon, A.M. and Tompkins, C. 1980. An ultrastructural study of the leucocytes of the channel catfish, *Ictalurus punctatus*. *J. Morphol.* 164:1-10.

- Cappel, D.F. and Anderson, J.R. 1971. Muir's Textbook of Pathology, 9th edition. Edward Arnold Ltd., 25 Hill Street, London. 976 pp.
- Carlson, B.M. 1973. The regeneration of skeletal muscle: A review. *Amer. J. Anat.* 137:119-150.
- Chaicharn, A. and Bullock, W.L. 1967. The histopathology of acanthocephalan infections in suckers with observations on the intestinal histology of two species of Catostomid fishes. *Acta Zool. (Stockholm)* 48:19-42.
- Chapman, J.A. 1961. Morphological and chemical studies of collagen formation. *J. Biophys. Biochem. Cytol.* 9:639-651.
- Charnchit, K. 1985. Pathogenicity and therapeutic studies of *Aeromonas hydrophila* infection in sand Goby (*Oxyeleotris marmoratus* Bleeker). Master thesis, Kasetsart University, Thailand. (in Thai).
- Chatterjee, I.B. 1973. Evolution and biosynthesis of ascorbic acid. *Science.* 182:1271-1272.
- Chatterjee, I.B., Majumder, A.K., Ghosh, N.C. and Guha, B.C. 1961. Biosynthesis of L-ascorbic acid: missing steps in animals incapable of synthesizing the vitamin. *Nature.* 192:163-164.
- Chiakulas, J.J. 1952. The role of tissue specificity in the healing of epithelium wound. *J. Exp. Zool.* 121:383-417.
- Chiller, J.M., Hodgins, H.O., Chambers, V.C. and Weiser, R.E. 1969. Antibody response in rainbow trout, (*Salmo gairdneri*), I. Immunocompetent cells in the spleen and anterior kidney. *J. Immun.* 102:1193-1201.
- Chinabut, S. and Limsuwan, C. 1983a. Histopathological changes in some freshwater fishes found during the disease outbreak: 1982-1983. *The Fisheries Gazette.* 36(3):281-289. (in Thai)
- 1983b. Histopathology of walking catfish (*Clarias batrachus*) infected by *Aeromonas hydrophila*. Technical Paper No. 24, National Inland Fisheries Institute, Thailand. 6 pp. (in Thai)
- Church, J.C.T. 1969. Satellite cells and myogenesis; a study in the fruit-bat web. *J. Anat.* 105:419-438.

- Cohn, Z.A. and Benson, B. 1965. The differentiation of mononuclear phagocytes. Morphology, cytochemistry and biochemistry. *J. Exp. Med.* 121:153.
- Coker, C.W. 1923. The Saprolegniaceae. Chapel Hill: University of North Carolina Press.
- Collins, C.H. and Lyne, P.M. 1976. Microbiological Methods, 4<sup>th</sup> edition. Butterworth, London.
- Conant, E.B. 1970. Regeneration in the African lungfish *Protopterus*. I. Gross aspects. *J. exp. Zool.* 174:15-32.
- Copeland, J.W. and Willoughby, L.G. 1982. The pathology of *Saprolegnia* infections of *Anguilla anguilla* L. eelers. *J. Fish Diseases.* 5(5):421-428.
- Corbel, M.J. 1975. The immune response in fish: a review. *J. Fish Biol.* 7:539-563.
- Cordier, R. 1964. The Cell, Vol.6, (Ed). J. Brachet and A.E. Mirsky, Academic Press, London & New York, 313-386 pp.
- Cumberbatch, N., Gurwith, M.J., Langston, C., Sack, R.B. and Burnton, J.L. 1979. Cytotoxic enterotoxin produced by *Aeromonas hydrophila* relationship of toxigenic isolates to diarrheal disease. *Infection and Immunity.* 23(3):829-837.
- Davies, H.G. and Haynes, M.E. 1975. Light and electron microscope observations on certain leucocytes in a teleost fish and a comparison of the envelope-limited monolayers of chromatin structural units in different species. *J. Cell Sci.* 17:263-285.
- Davis, H.S. and Lazar, E.C. 1940. A new fungus disease of trout. *Trans. Amer. Fish. Soc.* 70:264-271.
- Davis, J.F. and Hayasaka, S.S. 1983. Pathogenic bacteria associated with cultured american eels, *Anguilla rostrata* Le Sueur. *J. Fish Biol.* 23:557-564.
- Davis, W.A., Kane, J.G. and Garugusi, V.P. 1978. Human *Aeromonas* infections a review of the literature and a case of endocarditis. *Medicine.* 57:267-277.
- De Figueiredo, J. and Plumb, J.A. 1977. Virulence of different isolates of *Aeromonas hydrophila* in channel catfish. *Aquaculture.* 11:349-354.

- Dehadrai, P.V. 1962. Observations on certain physiological reactions in *Ophicephalus striatus* exposed to air. *Life. Sci.* 11:653-657.
- Deraniyagala, P.E.P. 1929. The Labyrinthici of Ceylon. *Ceylon J. Sci.*, sect. B. Zoology and Geology *Spotia Zeylanica.* 15(2):79-111.
- DiConza, J.J. and Halliday, W.J. 1971. Relationship of catfish serum antibodies to immunoglobulin in mucus secretions. *Australian Journal Experimental Biology and Medical Science.* 49:517-519.
- Dumont, A. and Sheldon, H. 1965. Changes in the fine structure of macrophages in experimentally produced tuberculous granulomas in hamsters. *Lab. Invest.* 14:2034-2053.
- Dunphy, J.E. 1963. The fibroblast- A ubiquitous ally for the surgeon. *New Engl. J. Med.* 268:1367-1377.
- Edelstein, L.M. 1971. Melanin: a unique biopolymer. In: *Pathobiology Annual*, Ed. H.L. Loachin, pp.309-324. New York, Appleton-Century-Crofts.
- Edward, L.C. and Dunphy, J.E. 1958. Wound healing: I. Injury and normal repair. *New Engl. J. Med.* 259:224-233.
- Elliot, D.G. and Shotts, E.B. 1980. Aetiology of an ulcerative disease in goldfish, *Carassius auratus* (L.): microbiological examination of diseased fish from seven locations. *J. Fish Dis.* 3:133-143.
- Ellis, A.E. 1974. Aspects of the lymphoid and reticulo-endothelial systems in the plaice, *Pleuronectes platessa* L. PhD. Thesis, University of Aberdeen, Scotland.
- \_\_\_\_\_ 1976. Leucocytes and related cells in the plaice (*Pleuronectes platessa*). *J. Fish Biol.* 8:143-156.
- \_\_\_\_\_ 1977. The leucocytes of fish: a review. *J. Fish Biol.* 11:453-464.
- \_\_\_\_\_ 1980. Antigen trapping in the spleen and kidney of the plaice, *Pleuronectes platessa*. *J. Fish Dis.* 3:413-426.
- \_\_\_\_\_ 1981. Non-specific defence mechanism in fish and their role in disease process. In: *Developments in Biological Standardization*, Vol.49, International Symposium on Fish Biology: Serodiagnostic and Vaccines. Ed. D.P. Anderson and W. Hennessen. Basel, Switzerland: S. Karger. 337-352 pp.

- Ellis, A.E. 1982. Difference between the immune mechanisms of fish and higher vertebrates. In: *Microbial Disease of Fish*. Ed. R.J. Roberts. Academic Press, London. 1-30 pp.
- \_\_\_\_\_ 1985. Eosinophilic granular cells (EGC) and histamine responses to *Aeromonas salmonicida* toxins in rainbow trout. *Develop. Comp. Immunol.* 9(2):251-260.
- Ellis, A.E., Hastings, T.S. and Munro, A.L.S. 1981. The role of *Aeromonas salmonicida* extra cellular products in the pathology of furunculosis. *J. Fish Dis.* 4:41-51.
- Ellis, A.E., Munro, A.L.S. and Roberts, R.J. 1976. Defence mechanisms in fish. I. A study of the phagocytic system and the fate of intraperitoneally injected particulate material in the plaice (*Pleuronectes platessa* L.). *J. Fish Biol.* 8:67-78.
- Ellis, A.E. and Sousa, M.A.B., De. 1974. Phylogeny of the lymphoid system I. A study of the fate of circulating lymphocytes in the plaice. *European J. Immunol.* 4:338-343.
- Ellis, A.E. and Wootton, R. 1978. Costiasis of Atlantic salmon, *Salmo salar* L. smolts in sea water. *J. Fish Dis.* 1:389-393.
- Enomoto, N., Nakagawa, H. and Tomigasu, Y. 1964. Studies on the external mucous substance of fishes-IX. Preparation of crystalline n-acetylneuraminic acid from the external mucous substance of loach. *Bull. Jap. Soc. scient. Fish.* 30:495-499.
- Ezeasor, D.N. and Stokoe, W.M. 1980. A cytochemical, light and electron microscopic study of the eosinophilic granule cells in the gut of the rainbow trout, *Salmo gairdneri* Richardson. *J. Fish Biol.* 17:619-634.
- FAO. 1972. Culture of snakehead. *FAO Aquaculture Bull.* 5(1):7.
- FAO. 1975. Seed production and culture of air-breathing fishes. *FAO Aquaculture Bull.* 7(3-4):4.
- Ferguson, H.W. 1975. Phagocytosis by the endocardial lining cells of the atrium of plaice (*Pleuronectes platessa*). *J. Comp. Path.* 85: 561-569.
- \_\_\_\_\_ 1976. The ultrastructure of plaice (*Pleuronectes platessa*) leucocytes. *J. Fish Biol.* 8:139-142.

- Finn, J.P. 1970. The protective mechanisms in fish disease. *Vet. Bull.* 40(12):873-886.
- Finn, J.P. and Nielson, N.O. 1971a. The effect of temperature variation on the inflammatory response of rainbow trout. *J. Path. Bact.* 105:257-268.
- 
- 1971b. The inflammatory response of rainbow trout. *J. Fish Biol.* 3:463-478.
- Fishelson, L. 1972. Histology and ultrastructure of the skin of *Lepadichthys lineatus* (Gobiesocidae: Teleostei). *Marine Biol.* 17:357-364.
- Fitton-Jackson, S. 1968. The morphogenesis of collagen. In: *Treatise on collagen*. Ed. B.S. Gould. New York, Academic Press. 2(B):1-66
- Fleischmajer, R. and Billingham, R.E.(Ed.). 1968. *Epithelial-mesenchymal interactions*. Williams & Wilkins, Baltimore.
- Fletcher, T.C. 1978. Defence mechanisms in fish. In: *Biochemical and Biophysical Perspectives in Marine Biology*. Vol. IV. Ed. D.C. Malins and J.R. Sargent. London, Academic Press. 189-222 pp.
- Fletcher, T.C. and Grant, P.T. 1968. Glycoprotein in the external mucus secretions of the plaice, *Pleuronectes platessa* and other fishes. *Biochem. J.* 106:12.
- 
1969. Immunoglobulins in the serum and mucus of the plaice (*Pleuronectes platessa*). *Biochem. J.* 115:65.
- Fletcher, T.C. and White, A. 1973. Lysozyme activity in the plaice (*Pleuronectes platessa*). *Experientia* 29:1283-1285.
- Flock, A<sup>o</sup>. 1965. Electron microscopic and electrophysiological studies on the lateral line canal organ. *Acta oto-lar. Suppl.* 199:1-90.
- Flock, A<sup>o</sup>. 1971. The lateral line organ mechanoreceptors. In: *Fish Physiology*. Ed. W.S. Hoar and D.J. Randall, Vol.5, New York and London, Academic Press. 241-263 pp.
- Frerichs, G.N. 1988. Ulcerative fish disease in Sri Lanka. *Aquaculture News*, No.6. p. 17.
- Frerichs, G.N., Millar, S.D. and Roberts, R.J. 1986. Ulcerative rhabdovirus in fish in South East Asia. *Nature*. 332(6076):216.

- Fujii, R. 1969. Chromatophores and pigments. In: Fish Physiology. Ed. W.S. Hoar and D.J. Randall, Vol. 3, New York and London, Academic Press. 307-344 pp.
- Gaines, J.C., Jr. 1972. Pathology of experimental infection of *Aeromonas hydrophila* (Chester) Stanier (Bacteria: Pseudomonadales), in the channel catfish, *Ictalurus punctatus* (Rafinesque). Ph.D thesis, Auburn Univ., Auburn, Alabama, USA.
- Geldreich, E.E. 1973. Microbiology of water. J. Water Pollution Control Federation. 45:1244-1259.
- Giavenni, R. and Finazzi, M. 1980. Tuberculosis in marine tropical fishes in an aquarium. J. Wildl. Dis. 16:161-168.
- Groman, D.B. 1982. Histology of the striped Bass. Monograph No. 3., American Fisheries Society, Bethesda, Maryland.
- Greenwood, P.H., Rosen, S.H., Weitzman, S.H. and Meyers, G.S. 1966. Phyletic studies of teleostean fishes, with a provisional classification of living fishes. Bull. Amer. Mus. Nat. Hist. 131:339-456.
- Grillo, H.C. 1963. Origin of fibroblasts in wound healing: An autoradiographic study of inhibition of cellular proliferation by local X irradiation. Ann. Surg. 157:453-467.
- Grizzle, J.M. and Rogers, W.A. 1976. Anatomy and Histology of the Channel Catfish. Auburn Univ. Agricultural Experiment Station, Auburn Univ., Alabama, USA.
- Groberg, W.J., McCoy, R.H., Pilcher, K.S. and Fryer, J.L. 1978. Relation of water temperature to infections of coho salmon (*Oncorhynchus kisutch*) chinook salmon (*O. tshawytscha*) and steelhead trout (*Salmo gairdneri*) with *Aeromonas salmonicida* and *A. hydrophila*. J. Zool. (Lond.). 184(4):519-543.
- Grollman, A.P. and Lehninger, A.L. 1957. Enzymic synthesis of L-ascorbic acid in different animal species. Archives of Biochemistry and Biophysics. 69:458-467.
- Hadfield, G. 1963. The tissue of origin of the fibroblasts of granulation tissue. Brit. J. Surg. 50:870-881.

- Haley, R., Davis, S.P. and Hyde, J.M. 1967. Environmental stress and *Aeromonas liquefaciens* in American and threadfin shad mortalities. Prog. Fish Cult. 29(4):193.
- Halver, J.E. 1972. The role of ascorbic acid in fish disease and tissue repair. Bull. Jap. Soc. Sci. Fish. 38(1):79-92.
- Halver, J.E., Ashley, L.M. and Smith, R.R. 1969. Ascorbic acid requirements of coho salmon and rainbow trout. Trans. Amer. Fish. Soc. 98:762-771.
- Halver, J.E., Smith, R.R., Tolbert, B.M. and Baker, E.M. 1975. Utilization of ascorbic acid in fish. Ann. N.Y. Acad. Sci. 258:81-102.
- Harrel, L.W., Etlinger, H.M. and Hodgins, H.O. 1976. Humoral factors important in resistance of salmonid fish to bacterial disease. II. Anti-vibrio anguillarum activity in mucus and observations on complement. Aquaculture. 7:363-370.
- Harris, J.E. 1972. The immune response of a cyprinid fish to infections of the acanthocephalan *Pomphorhynchus laevis*. International Journal for Parasitology. 2:459-469.
- Harris, J.E. and Hunt, S. 1973. Epithelial mucins of the Atlantic salmon (*Salmo salar* L.). Biochem. Soc. Trans. 531st. Meeting, Lancaster. 1:153-276.
- Harris, J.E., Watson, A. and Hunt, S. 1973. Histochemical analysis of mucous cells in the epidermis of brown trout, *Salmo trutta* L. J. Fish Biol. 5:345-351.
- Hawkes, J.W. 1974. The structure of fish skin. I. General. Cell. Tiss. Res. 149, pt2, 147-158pp.
- Hazen, T.C., Fliermans, C.B., Hirsch, R.P. and Esch, G.W. 1978. Prevalence and distribution of *Aeromonas hydrophila* in the United States. Applied and Environmental Microbiology. 36(5):731-738.
- Henrickson, R.C. 1967. Incorporation of tritiated thymidine by teleost epidermal cells. Experientia. 23:357-358.
- Henrickson, R.C. and Matoltsy, A.G. 1968a. The fine structure of teleost epidermis. I. Introduction and filament-containing cells. J. Ultra-structure Res. 21:194-212.



- Henrickson, R.C. and Matoltsy, A.G. 1968b. The fine structure of teleost epidermis. II. Mucous cells. *J. Ultrastructure Res.* 21:213-221.
- Herrick, C.J. 1904. The organ and sense of taste in fishes. *Bull. U.S. Fish. Comm.* No.22:238-272.
- Hickey, G.M. 1979. Survival of fish larvae after injury. *J. Exp. Mar. Biol. Ecol.* 37:1-17.
- \_\_\_\_\_ 1982. Wound healing in fish larvae. *J. Exper. Marine Biol. Ecol.* 57(2-3):149-168.
- Hildemann, W.H. 1959. A cichlid fish, *Symphysodon discus*, with unique nature habits. *Am. Nat.* 93:27-34.
- Hilton, J.W., Cho, C.Y. and Shinger, S.J. 1978. Effect of graded levels of supplemental ascorbic acid in practical diets fed to rainbow trout (*Salmo gairdneri*). *J. Fish Res. Bd. Can.* 35:431-436.
- Hirata, Y. 1966. Fine structure of terminal buds on the barbels of fishes. *Arch. Histol. Jpn.* 26:507-523.
- Hjelmeland, K., Christie, M. and Raa, J. 1983. Skin mucus protease from rainbow trout, *Salmo gairdneri* Richardson, and its biological significance. *J. Fish Biol.* 23:13-22.
- Holmberg, k. 1968. Ultrastructure and response to background illumination of the melanophores of the Atlantic hagfish, *Nyxine glutinosa*. *General and Comparative Endocrinology.* 10:421-428.
- Hoole, D. and Arme, C. 1983. *Ligula intestinalis* (Cestoda:Pseudophyllidae): an ultrastructural study on the cellular response of roach fry, *Rutilus rutilus*. *Int. J. Parasitol.* 13:359-363.
- Hora, S.L. 1935. Physiology, bionomics and ovulation of the air-breathing fishes of India. *Trans. nat. Inst. Sci. India.* 1:1-16.
- Hoshina, T. and Ookubo, N. 1956. Mycosis in eels. *J. Tokyo Univ. Fish.* 42:1.
- Hoshina, T., Sano, T. and Sunayama, M. 1960. Studies on the saprolegniosis of eels. *J. Tokyo Univ. Fish.* 47:59-67.

- Huizinga, H.W., Esch, G.W. and Hazen, T.C. 1979. Histo-pathology of red-sore disease (*Aeromonas hydrophila*) in naturally and experimentally infected largemouth bass *Micropterus salmoides* (Lacepede). *J. Fish Dis.* 2:263-277.
- Hyman, L.H. 1962. The comparative anatomy of the skin and the exoskeleton. In: *Comparative vertebrate anatomy*. Chicago: University of Chicago Press. 79-98 pp.
- Ingram, G.A. 1980. Substances involved in the natural resistance of fish to infection: A review. *J. Fish Biol.* 16:23-60.
- Jakobowski M. 1958. The structure and vascularization of the skin of pond-loach (*Misgurnus fossilis* L.). *Acta Biol. Cracov. Ser. Zool.* 1:113-127.
- Jakowska, S. 1953. Localized responses in fish to experimental inflammation caused by pathogenic bacteria. *Anat. Rec.* 117:526.
- \_\_\_\_\_ 1963. Mucous secretion in fish - A note. *Ann New York. Acad. Sci.* 106:458-462.
- Jakowska, S. and Nigrelli, R.F. 1953. Localised responses in fish to experimental inflammation caused by pathogenic bacteria. *Anat. Rec.* 117:526.
- Jauncey, K., Soliman, A. and Roberts, R.J. 1985. Ascorbic acid requirements in relation to wound healing in the cultured tilapia *Oreochromis niloticus* (Trenavas). *Aquaculture and Fisheries Management.* 16:139-149.
- Jha, B.C., Seth, R.N. and Srivastava, K.P. 1977. Occurrence of *Achlya* sp. on a new host *Mystus* spp. *Curr. Sci.* 46(2), 60pp.
- Jhingran, V.G. 1975. *Fish and Fisheries of India*. Hindustan Publishing Cooperation of India. Delhi, India.
- Johnson, T.W. Jr. 1956. The genus *Achlya*; Morphology and Taxonomy. Univ. Michigan Press Ann. Arbor. 180pp.
- Jordan, D.S. 1907. *Fishes*. Henry Holt & Co., New York.
- Jordan, H.E. and Speidel, C.C. 1924. Studies on lymphocytes. II. The origin, structure and fate of the lymphocytes in fishes. *J. Morph.* 38:529-549.

- Joseph, S.W., Daily, O.P., Hunt, W.S., Seidler, R.J., Allen, D.A. and Colwell, R.R. 1979. *Aeromonas* primary wound infection of a driver in polluted waters. *J. clin. Microbiol.* 10:46-49.
- Kanai, K. and Wakabayashi, H. 1984. Purification and some properties of protease from *Aeromonas hydrophila*. *Bull. Jap. Soc. Sci. Fish.* 50(8):1367-1374.
- Kaper, J.B., Lockman, H and Colwell, R.R. 1981. *Aeromonas hydrophila*: Ecology and toxigenicity of isolates from an estuary. *J. Appl. Bact.* 50:359-377.
- Kapoor, B.G., Smith, H. and Verighina, I.A. 1975. The alimentary canal and digestion in teleosts. *Adv. mar. Biol.* 13:109-239.
- Khulbe, R.D. and Sati, S.C. 1981. Studies on parasitic water moulds of Kumaun Himalaya; Host range of *Achlya americana* Humphrey, on certain temperate fish. *Mykosen.* 24(3):177-180.
- King, J.M. 1975. Nutritional myopathy in fish. In: *The Pathology of Fish*, Ed. W.E. Ribelin & G. Migaki. Madison, Wisconsin: University of Wisconsin Press. 787-792 pp.
- Kitamura, S. 1969. Summary on the hypovitaminosis C of rainbow trout, *Salmo gairdneri*. *Fish Pathol.* (Japan). 3:73-92.
- Kitamura, S., Ohara, S., Suwa, T. and Nakawa, K. 1965. Studies on vitamin requirements of rainbow trout *Salmo gairdneri*. I. On the ascorbic acid. *Bull. J. Soc. Sci. Fish.* 31(10):818-826.
- Kitzan, S.M. and Sweeny, P.R. 1968. A light and electron microscope study of the structure of *Protopterus annecteus* epidermis. I. Mucus production. *Can. J. Zool.* 46:767-772.
- Klontz, G.W. 1966. Bacterial diseases of the Salmonidae in the Western United States: Pathogenesis of ferunculosis in rainbow trout. *Am. J. Vet. Res.* 27:1455-1460.
- 1972. Ueber eine Gaerungsmikrobe infaekalien und Muchen Larven. *Zbl. Bakt.* 2 Abt. 85:223-250.
- Klontz, G.W. and Anderson, D.P. 1968. Fluorescent antibody studies of isolates of *Aeromonas salmonicida*. *Bull. Off. Int. Epiz.* 69:1149-1157.

- Krawczyk, W. 1971. A pattern of epidermal cell migration during wound healing. *J. Cell. Biol.* 49:247-263.
- Kudokotsev, V.P. and Silkina, M.V. 1967. Regeneration process after amputation of the posterior end of bony fishes (in Russ.). *Biol. Nauk.* 10:39-42.
- Laird, L.M., Roberts, R.J., Shearer, W. M. and McArdle, J.F. 1975. Freeze branding of juvenile salmon. *J. Fish Biol.* 7:888-999.
- Lallier, R., Bernad, F. and Lalonde, G. 1984. Difference in the extracellular products of two strains of *Aeromonas hydrophila* virulent and weakly virulent for fish. *Can. J. Microbiol.* 30(7):900-915.
- Lallier, R. and Daigneault, P. 1984. Antigenic differentiation of pili from nonvirulent and fish-pathogenic strains of *Aeromonas hydrophila*. *J. Fish Dis.* 7(6):509-512.
- Laskin, A. and Lechevalier, H. 1972. *Macrophages and Cellular Immunity*. London: Butter-Worths.
- Lehtonen, A., Karkkainen, J. and Haashti, E. 1966. Carbohydrate components in the epithelial mucin of hagfish, *Myxine glutinosa*. *Acta chem. scand.* 20:1456-1462.
- Leppi, T.J. 1968. Morphochemical analysis of mucous cells in the skin and slime glands of hagfishes. *Histochemie.* 15:68-78.
- Lerssuthichawal, T. 1987. Effect of temperature on the susceptibility of walking catfish to *Aeromonas hydrophila*. M.S. thesis, Kasetsart University, Thailand. (in Thai).
- Lester, R.J.G. and Desser, S.S. 1975. Ultrastructural observations on the granulocytic leucocytes of the teleost, *Catostomus commersoni*. *Can. J. Zool.* 53:1648-1657.
- Lester, R.J.G. and Daniels, B.A. 1976. The eosinophilic cell of the white sucker, *Catostomus commersoni*. *J. Fish. Res. Bd. Can.* 33:139-144.
- Lewis, M.R. and Lewis, W.H. 1926. The transformation of mononuclear blood cells into macrophages, epithelioid cells and giant cells in hanging drop blood cultures from lower vertebrates. *Cont. Emb.* 18:95-120.
- Leydig, F. 1851. Ueber die aussere Haut einiger Subwasserfische. *Z. wiss. Zool.* 3:1-12.

- Lim, C. and Lovell, R.T. 1978. Pathology of vitamin C deficiency syndrome in channel catfish (*Ictalurus punctatus*). *J. Nutr.* 108:1137-1146.
- Limsuwan, C. and Chinabut, S. 1986. Pathogenesis and its chemical treatments of *Aeromonas hydrophila* infection in *Clarias batrachus* and *Ophicephalus striatus*. Fisheries Faculty, Kasetsart University, Thailand. (in Thai)
- Limsuwan, C., Chinabut, S., Pawaputanon, K. and Lawhavinit, O. 1983. Tuberculosis (Mycobacteriosis) in snakehead (*Ophicephalus striatus*). Technical Paper No.32, National Inland Fisheries Institute, Thailand. 9 pp.
- Limsuwan, C., Kitsawhat, P. and Chinabut, S. 1986. Histology of walking catfish. Kasetsart Univ. 183 pp.
- Ling, S.W. 1977. Aquaculture in South East Asia: A historical overview. Washington Sea Grant Publication. Washington University Press, Seattle and London. 198 pp.
- Liu, C. and Volz, P.A. 1976. On the ecology of the Saprolegniaceae. *Phytologica.* 34:209-230.
- Llobrera, A.T. and Gacutan, R.Q. 1987. *Aeromonas hydrophila* associated with ulcerative disease epizootic in Laguna de Bay, Philippine. *Aquaculture.* 67:273-278.
- Logan, V.H. and Odense, P.H. 1974. The integument of the ocean sunfish (*Mola mola* L.) (Plectognathi) with observations on the lesions from two ectoparasites, *Capsala martinieri* (Trematoda) and *Philorthagoriscus servatus* (Copepoda). *Can. J. Zool.* 52:1039-1045.
- MacArthur, J.I., Fletcher, T.C., Pirie, B.J.S., Davidson, R.J.L. and Thomson, A.W. 1984. Peritoneal inflammatory cells in plaice, *Pleuronectes platessa* L.: effect of stress and endotoxin. *J. Fish Biol.* 25:69-81.
- Mackmull, G. and Michels, N.A. 1932. Absorption of colloidal carbon from the peritoneal cavity in the teleost, *Tautoglabrus adspersus*. *Am. J. Anat.* 51:3-45.
- Mahajan, C.L. and Agrawal, N.K. 1980. Nutritional requirement of ascorbic acid by Indian major carp, *Cirrhina mrigala*, during early growth. *Aquaculture.* 19(1):37-48.

- Mahajan, C.L. and Dheer, J.M.S. 1980. Origin and development of neutrophils in air breathing fish *Channa punctatus* (Bloch). *Acta. Zool.* 61:261-264.
- Majeed, S.K., Gopinath, C. and Lolly, D.W. 1981. Pathology of spontaneous tuberculosis and pseudo-tuberculosis in fish. *J. Fish Dis.* 4:507-512.
- Matthiessen, P. and Roberts, R.J. 1982. Histopathological changes in the liver and brain of fish exposed to endosulfan insecticide during tsetse fly control operations in Botswana. *J. Fish Dis.* 5:153-159.
- Mauck, W.L., Mehrle, P.M. and Mayer, F.L. 1978. Effect of polychlorinated bi phenyl arocalor 12554 on growth, survival, and bone development in brook trout (*Salvelinus fontinalis*). *J. Fish. Res. Bd. Can.* 35:1084-1088.
- Mauro, A. 1961. Satellite cell of skeletal cell fibres. *J. biophys. biochem. Cytol.* 9:493-494.
- Mawdesley-Thomas, L.E. and Bucke, D. 1973. Tissue repair in a poikilothermic vertebrate *Carassius auratus* (L.) a preliminary study. *J. Fish Biol.* 5:115-119.
- Mawdesley-Thomas, L.E. and Young, P.C. 1967. Cutaneous melanosis in a flounder (*Platichthys flesus*). *Vet. Rec.* 81:384-385.
- McMinn, R.M.H. 1967. The cellular morphology of tissue repair. *Intr. Rev. Cytol.* 22:64-128.
- McQueen, A., MacKnight, K., Roberts, R.J. and Young, H. 1973. Studies on the skin of plaice (*Pleuronectes platessa*) III. The effect of temperature on the inflammatory response to the metacercaria of *Cryptocotyle lingua* (Creplin 1825). *J. Fish Biol.* 5:241-247.
- McVicar, A.H. and Mclay, H.A. 1985. Tissue response of plaice, haddock and rainbow trout to the systemic fungus *Ichthyophonus*. In: *Fish and Shellfish Pathology*. Ed. A.E. Ellis. Academic Press, London. 329-346 pp.
- McVicar, A.H. and White, P.G. 1979. Fin and skin necrosis in cultivated Dover sole, *Solea solea* (L.). *J. Fish Dis.* 2:557-562.
- Medlar, E.M. 1926. Giant cells and their relation to caseation in tuberculosis. *Am. J. Path.* 2:291-299.

- Merrilees, M.J. 1974. Epidermal fine structure of the teleost *Esox americanus* (Esocidae, Salmoniformes). *J. Ultrastructure Res.* 47:272-283.
- Metchnikoff, E. 1891. Lectures on the comparative pathology of inflammation delivered at the Pasteur Institute in 1891. English translation by F.A. Starling and H.E. Starling. London. 218 pp.
- Meyer, M.C. 1970. Cestode soonoses of aquatic animals. *J. Wildl. Dis.* 6:249-254.
- Miller, R.W. and Chapman, W.A. 1976. Epistylis and *Aeromonas hydrophila* infections in fishes from North Carolina reservoirs. *Prog. Fish Cult.* 38:165-168.
- Miquel, J., Oro, L., Bensch, K.G. and Johnson, J.E. 1977. Lipofuscin: Fine structural and biochemical studies. In: *Free Radicals in Biology Vol. 3*, Ed. W.A. Pryon. 133-182 pp.
- Misra, K.S. 1959. An aid to commercial fishes. *Records of the Indian Museum.* 57:217-222.
- Mittal, A.K. 1968. Studies on the structure of the skin of *Rita rita* (Ham) (Bagridae, Pisces) in relation to its age and regional variations. *Indian J. Zootomy.* 9:61-78.
- Mittal, A.K., Agarwal, S.K. and Banerjee, T.K. 1976. Protein and carbohydrate histochemistry in relation to the keratinization in the epidermis of *Barbus sophur* (Cyprinidae, Pisces). *J. Zool., Lond.* 179:1-17.
- Mittal, A.K. and Banerjee, T.K. 1975a. Histochemistry and the structure of the skin of a murrel, *Channa striatus* (Bloch 1797) (Channiformes, Channidae). I. Epidermis. *Can. J. Zool.* 53(6):833-843.
- 
- 1975b. Histochemistry and the structure of the skin of a murrel, *Channa striatus* (Bloch 1797) (Channiformes, Channidae). II. Dermis and Subcutis. *Can. J. Zool.* 53(6):844-852.
- Mittal, A.K. and Munshi, J.S.D. 1970. Strucyutr of the integument of a freshwater teleost, *Bagarius bagarius* (Ham)(Sisoridae, Pisces). *J. Morph.* 130:3-10.
- Mittal, A.K. and Munshi, J.S.D. 1971. A comparative study of the structure of the skin of certain air-breathing fresh-water teleost. *J. Zool. Proc. Zool Soc. Lond.* 163:515-532.

- Mittal, A.K. and Munshi, J.S.D. 1974. On the regeneration and repair of superficial wounds in the skin of *Rita rita* (Ham.) (Bagridae; Pisces). *Acta. Anat.* 88:424-442.
- Mittal, A.K., Rai, A.K. and Banerjee, T.K. 1978. Studies on the pattern of healing of wound in the skin of a catfish, *Heteropneustes fossilis* (Bloch.) (Heteropneustidae, Pisces). *Z. Mikrosk-Anat. Forsch.* 91(2):270-286.
- Mookerjee, H.K., Ganguly, D.N. and Bhattacharya, R.N. 1948. On the bionomus breeding habits and development of *Ophicephalus striatus* Bloch. *Proc. Zool. Soc. Bengal.* 1:58-64.
- Munshi, J.S.D. 1962. On the accessory respiratory organs of *Ophicephalus punctatus* (Bloch) and *O. striatus* (Bloch). *J. Linn. Soc. Lond. (Zool.)*. 44:616-626.
- \_\_\_\_\_ 1976. Gross and fine structure of the respiratory organs of air-breathing fishes. In: *Respiration of amphibious vertebrates*. Ed. G.M. Hughes. London: Academic Press. 73-104 pp.
- Murai, T., Andrew, J.W. and Bauernfeind, J.C. 1978. Use of L-ascorbic acid, ethocel coated ascorbic acid and ascorbate 2-sulfate in diets for channel catfish, *Ictalurus punctatus*. *J. Nutr.* 108(11):1761-1766.
- Murray, R.G. 1973. The ultrastructure of taste buds. In: *The Ultrastructure of Sensory Organs*. Ed. I. Friedemann. North Holland Publishing Company, Amsterdam-London. 1-81 pp.
- Murugesan, V.K. 1978. The growth potential of the murrel, *Channa marulius* (Hamilton) and *C. striatus* (Bloch). *J. Inland Fish. Soc. India.* 10:169-170.
- Nagamura, Y. and Wakabayashi, H. 1985. Changes in glycogen content of neutrophils in eel, *Anguilla japonica* by bacterial infection. *Fish Path.* 20(2-3):389-394.
- Neave, F. 1936a. Origin of the teleost scale-pattern and the development of the teleost scale. *Nature (London.)* 137:1034-1035.
- Neave, F. 1936b. The development of the scales of *Salmo*. *Trans. roy. Soc. Can., Sect. V.* 30:55-72.
- Neilson, A.H. 1978. The occurrence of *Aeromonads* in activated sludge: isolation of *Aeromonas sobria* and its possible confusion with *Escherichia coli*. *J. Appl. Bacteriol.* 44:259-264.



- Neish, G.A. 1976. Observations on the pathology of saprolegniasis of Pacific salmon and on the identity of the fungi associated with this disease. Ph.D. thesis, University of British Columbia, Vancouver.
- Neish, G.A. and Hughes, G.C. 1980. Diseases of Fish, Book 6. Fungal Diseases of Fish. Ed. S. Snieszko and H.R. Axelrod. T.F.H. Publications, New Jersey.
- Nelson, R.A. Jr. and Gigli, I. 1968. Initial studies on the phylogeny of the complement system. J. Immunol. 101:815-816.
- Newman, S.G. 1983. *Aeromonas hydrophila*: A review with emphasis on its role in fish disease. In: Les Antigenes des Micro-organismes Pathogenes des Poissons. Symposium International de Talloires. Ed. D.P. Anderson, M. Dorson and P.H. Dubourget. Collection Marcel Merieuse, Lyon. 87-117 pp.
- Nigrelli, R.F. and Vogel, H. 1963. Spontaneous tuberculosis in fish and in other cold-blooded vertebrates with special reference to *Mycobacterium fortuitum* Cruz from fish and human lesion. Zoologica. 48:131-144.
- Noga, E.J. 1986. The importance of *Lernaea cruciata* (Le Sueur) in the innitiation of skin lesions in largemouth bass *Micropterus salmoides* (Lacepede), in the Chowan River, North Carolina U.S.A. J. Fish Dis. 9:295-302.
- Noga, E.J. and Dykstra, M.J. 1986. Oomycete fungi associated with ulcerative and mycosis in menhaden, *Brevoortia tyrannus* (Latrobe). J. Fish Dis. 9:47-53.
- Nolard-Tintigner, N. 1973. Etude experimentale sur l'epidemiologie et la pathogenic de la Saprolegniose Chez *Lebistes reticulatus* et *Xiphophorus helleri*. Acta. Zool. Path. Antverpiensia. 57:1-127.
- Nord, C.E., Sjoberg, L., Wadstrom, T. and Wrethind, B. 1975. Characterization of three *Aeromonas* and more *Pseudomonas* species by extracellular enzymes and hemolysins. Med. Microbiol. Immunol. 161:79-87.
- Olivier, G., Evelyn, T.P.T. and Lallier, R. 1985. Immunity to *Aeromonas salmonicida* in coho salmon (*Oncorhynchus kisutch*) induced by modified Freund's complete adjuvant, its non specific nature and the possible role of macrophages in the phenomenon. Dev. Comp. Immunol. 9:419-432.

- Ourth, D.D. 1980. Secretory IgM, lysozyme and lymphocytes in the skin mucus of the channel catfish, *Ictalurus punctatus*. *Devel. Comp. Immunol.* 4(1):65-74.
- Pandian, T.J. 1980. Culture of air-breathing fishes. *Tropical Ecology & Development.* 1223-1227 pp.
- Pantulu, V.R. 1976. Floating cage culture of fish in the lower Mekong basin. In: *FAO Technical Conference on Aquaculture, Kyoto, Japan, 26 May-2 June 1976, Fir:AQ/CONE/76/E10.*
- Papadimitriou, J.M. and Spector, W.G. 1971. The origin, properties and fate of epithelioid cells. *J. Path.* 105:187-203.
- Parameswaran, S. and Murugesan, V.K. 1976. Breeding season and seed resources of murrels in swamps of Karnataka State. *J. Inland Fish. Soc. India.* 8:60-67.
- Parameswaran, S., Selvaraj, C. and Radhakrishnan, S. 1970. Observations on the maturation and breeding season of carps in Assam. *J. Indian Fish. Soc. India.* 2:16-29.
- Parisot, T.J. and Wood, E.M. 1960. A comparative study of the causative agent of a mycobacterial disease of salmonid fishes. *Am. Rev. Resp. Dis.* 82:212-222.
- Peduzzi, R. and Bizzozero, S. 1977. Immunochemical investigation of four *Saprolegnia* species with parasitic activity in fish: serological and kinetic characterization of a chymotrypsin-like activity. *Microbial Ecol.* 3:107-119.
- Peduzzi, R., Nolard-Tintigner, N. and Bizzozero, S. 1976. Recherches sur La Saprolegniose II. *Riv. It. Piscic. Ittiop.* 11:109
- Peleteiro, M.C. and Richards, R.H. 1985. Identification of lymphocytes in the epidermis of the rainbow trout, *Salmo gairdneri* Richardson. *J. Fish Dis.* 8:161-172.
- Phromsuthirak, P. 1976. Electron microscopy of cellular reactions during wound healing in the three-spined stickle back, *Gasterosteus aculeatus* L. Ph.D. thesis, University of London.
- Pichyangkura, S. 1987. Histopathology of *Ophicephalus striatus* on *Achlya* fungus infection. The Symposium on Freshwater Fishes Epidemic: 1982-1983, Chulalongkorn University. 206-211 pp. (in Thai).

- Pickering, A.D. 1974 The distribution of mucous cells in the epidermis of the brown trout, *Salmo trutta* (L.) and the char, *Salvelinus alpinus* (L.). *J. Fish Biol.* 6:111-118.
- 1977. Seasonal changes in the epidermis of the brown trout, *Salmo trutta* (L.). *J. Fish Biol.* 10:561-566.
- Pickering, A.D. and Macey, D.J. 1977. Structure, histochemistry and the effect of handling on the mucous cells of the epidermis of the char, *Salvelinus alpinus* (L.). *J. Fish Biol.* 10:506-512.
- Pickering, A.D. and Richards, R.H. 1980. Factors influencing the structure, function and biota of the salmonid epidermis. Proceeding of the Royal Society of Edinburgh. 79B:93-104.
- Pickering, A.D. and Willoughby, L.G. 1977. Epidermal lesions and fungal infection on the perch, *Perca fluviatilis* L., in Windermere. *J. Fish Biol.* 11:349-354.
- Plumb, J. A., Grizzle, J.M. and Defigueiredo, J. 1976. Necrosis and bacterial infection in channel catfish (*Ictalurus punctatus*) following hypoxia. *J. Wildl. Dis.* 12:247-253.
- Popoff, M. and Veron, M. 1976. A taxonomic study of the *Aeromonas hydrophila*, *Aeromonas punctata* group. *J. Gen. Microbiol.* 94:11-22.
- Post, G. 1963. The immune response of rainbow trout (*Salmo gairdneri*) to *Aeromonas hydrophila*. State of Utah Department of fish and Game, Departmental Information Bulletin. 63-67 pp.
- Post, G. 1983. Textbook of Fish Health. T.F.H. Publication, Inc., Neptune City, New Jersey. 256 pp.
- Prasdnikov, E.V. and Mikhailova, I.G. 1968. Inflammation phenomenon in prelarval pink salmon. *Biol. Abstr.* 49:109-307.
- Prosser, C.L. 1962. Acclimation of poikilothermic vertebrates to low temperatures. In: Comparative Physiology of temperature Regulation. Ed. Hanon and Viereck. Alaska: Arctic Aeromedical Laboratory.
- Przybylski, R.J. and Blumberg, J.M. 1966. Ultrastructural aspects of myogenesis in the chick. *Lab Invest.* 15:836-863.

- Qasim, S.Z. and Qayyum, A. 1961. Spawning frequencies and breeding seasons of some freshwater fish with special reference to those occurring in the plains of northern India. *Indian J. Fish.* 8:24-43.
- Raj, S.B. 1916. Notes on the freshwater fish of Madras. XVII. *Rec. Ind. Mus. Calcutta.* 12:249-294.
- Ramachandran, P. and Thangavelu, M. 1969. A comparative study of wound healing. *Ind. J. Exper. Biol.* 7:148-151.
- Reed, G.B. and Toner, G.C. 1941. Red sore disease in pike. *Can. J. Res., Ser. D.* 19:139.
- Reif, W.E. 1978. Wound healing in sharks: From and arrangement of repair scales. *Zoomorphol.* 90(2):101-111.
- Reimschuessel, R., Bennett, R.O., May, E.B. and Lipsky, M.M. 1987. Eosinophilic granular cell response to a microsporidian infection in a sergeant major fish, *Abudefduf saxatilis* (L.). *J. Fish Dis.* 10:319-322.
- Reulter, K. 1978. Taste organ in the bullhead (Teleostei). *Adv. Anat. Embryol. Cell. Biol.* 55/1:1-98.
- 1982. Taste organ in the barbel of the bullhead. In: *Chemoreception in Fishes*. Ed. T.J. Hara. Elsevier Scientific Publishing Company. Amsterdam. 77-91 pp.
- Reznikoff, P. and Reznikoff, D.G. 1934. Haematological studies in dogfish (*Mustelus canis*). *Biol. Bull. mar. biol. Lab. Woods Hole.* 66:115-123.
- Richards, R.H., Halliman, A. and Helgason, S. 1978. Naturally occurring *Exophiala salmonis* infection in Atlantic salmon (*Salmo salar* L.). *J. Fish Dis.* 1:357-369.
- Richards, R.H. and Pickering, A.D. 1978. Frequency and distribution patterns of *Saprolegnia* infection in wild and hatchery-reared brown trout *Salmo trutta* L. and char, *Salvelinus alpinus* (L.). *J. Fish Dis.* 1:69-82.
- Riddle, L.M., Graham, T.E. and Amborski, R.L. 1981. Medium for the accumulation of extra-cellular hemolysin and protease by *Aeromonas hydrophila*. Infection and Immunity. 33(3):729-733.

- Roberts, R.J. 1975a. Melanin-containing cells of teleost fish and their relation to disease. In: The Pathology of Fish. Ed. W.E. Ribelin and G. Migaki. The university of Wisconsin Press. 399-428 pp.
- 
- 1975b. The effect of temperature on diseases and their histopathological manifestations in fish. In: The Pathology of Fish. Ed. W.E. Ribelin and G. Migaki. The university of Wisconsin Press. 477-496 pp.
- Roberts, R.J. (Ed.) 1978. Fish Pathology. Baillure Tindall, London. 318 pp.
- Roberts, R.J. and Bullock, A.M. 1976. The dermatology of marine teleost fish. II. Dermatopathology of the integument. Oceanogr. Mar. Biol. A. Rev. 14:227-246.
- Roberts, R.J., Ball, H.J., Munro, A.L.S. and Shearer, W.M. 1971. Studies on ulcerative dermal necrosis of salmonids. III. The healing process in fish maintained under experimental conditions. J. fish Biol. 3:221-224.
- Roberts, R.J., Macintosh, D.J., Tonguthai, K., Boonyaratpalin, S., Tayapatch, N., Phillips, M.J. and Miller, S.D. 1986. Field and laboratory investigations into ulcerative fish diseases in the Asia-Pacific Region. FAO. Technical Report TCP/RAS/4508. 214 pp.
- Roberts, R.J., McQueen, A., Shearer, W.M. and Young, H. 1973a. The histology of salmon tagging. II. The chronic tagging lesion in returning adult fish. J. Fish Biol. 5:615-620.
- 
- 1973b. The histology of salmon tagging. III. Secondary infections associated with tagging. J. Fish Biol. 5:621-623.
- Roberts, R.J., Shearer, W.M., Elson, K.G.R. and Munro, A.L.S. 1970. Studies on ulcerative dermal necrosis. I. The skin of the normal salmon head. J. Fish Biol. 2:223-229.
- Roberts, R.J., Young, H. and Milne, J.A. 1972. Studies on the skin of plaice (*Pleuronectes platessa* L.) 1. The structure and ultrastructure of normal plaice skin. J. Fish Biol. 4:87-98.
- Rock, L. and Nelson, H.M. 1965. Channel catfish and gizzard shad mortality caused by *Aeromonas liquefaciens*. Prog. Fish Cult. 27:138-141.
- Rosen, M.W. and Cornford, N.E. 1971. Fluid friction of fish slimes. Nature, Lond. 234:49-51.

- Roth, R.R. 1972. Some factors contributing to the development of fungus infection in freshwater fish. *J. Wildl. Dis.* 8:24-28.
- Rouf, M.A. and Rigney, M.M. 1971. Growth temperatures and temperature characteristics of *Aeromonas*. *Appl. Microbiol.* 22:503-506.
- Rovee, D.T., Kurowsky, C.A., Labun, J. and Downess, A.M. 1972. Effect of local wound environment on epidermal healing. In: *Epidermal wound healing*. Ed. H.T. Maibach and D.T. Rovee. Chicago: Year Book Medical Publishers. 159-181 pp.
- Russell, P.H. 1974. Lymphocystis in wild plaice (*Pleuronectes platessa* L.) and flounder (*Platichthys flesus* L.) in British coastal waters: a histopathological and serological study. *J. Fish Biol.* 6:771-778.
- Sage, M. 1970. Control of prolactin release and its role in color change in teleost *Gillichthys mirabilis*. *J. exp. Zool.* 173:121-128.
- Sakanari, J.A. and Moser, M. 1986. Lesion induction by the plerocercoid *Lacistorhynchus tenuis* (Cestoda) and wound healing in the striped bass, *Morone saxatilis* (Walbaum). *J. Fish Biol.* 28:289-296.
- Saxena, D.B. 1967. Studies on the physiology of respiration in fishes. VIII. Functional anatomy of the respiratory organo of the air-breathing fish, *Ophicephalus punctatus* with remarks on the modifications in vascular system of teleostmi due to air-breathing habits. *Ichthyologica.* 6:13-30.
- Saxena, M. and Kulshrestha, S.K. 1982. Studies on the effect of DDT on the regeneration of cutaneous wounds in *Mystus vittatus*. *Acta Hydrochim. Hydrobiol.* 10:353-360.
- Schaperclaus, W. 1930. *Pseudomonas punctata* als Krankheitserreger bei Fishchen. *Zeitung fur Fischerel.* 28:289-370.
- Schaperclaus, W. 1953. Fortpflanzung und Systematik von *Ichthyophonus*. *Aquar.-u. Terrar.-Z.* 6:177-182.
- Scott, W.W. 1964. Fungi associated with fish diseases. *Dev. Ind. Microbiol.* 5:109-123.
- Scott, W.W. and O'Bier, A.H. 1962. Aquatic fungi associated with diseased tropical fishes and fish eggs. *Prog. Fish Cult.* 24:3-15.

- Scott, W.W. and Warren, C.O. Jr. 1964. Studies of host range and chemical control of fungi associated with diseased tropical fish. Virginia Techn. Bull. 171:1-24.
- Secombes, C.J. 1985. The *in vitro* formation of teleost multinucleate giant cells. J. Fish Dis. 8:461-464.
- Shafiq, S.A., Gorycki, M.A. and Milhorat, A.T. 1967. An electron microscopic study of regeneration and cells in human muscle. Neurol. 17:567-575.
- Shah, K.L., Jha, B.C. and Jhingran, A.G. 1977. Observations on some aquatic phycomycetes pathogenic to eggs and fry of freshwater fish and prawn. Aquaculture. 12:141-147.
- Shieh, H.S. 1978. Changes of blood enzymes in brook trout induced by infection with *Aeromonas salmonicida*. J. Fish Biol. 12:13-18.
- Shotts, E.B., Gaines, J.L., Martin, L. and Prestwood, A. 1972. *Aeromonas* induced deaths among fish and reptiles in an eutrophic inland lake. J. Am. Vet. Med. Assoc. 161(6):603-607.
- Shotts, E.B. and Rimler, R.B. 1973. Medium for the isolation of *Aeromonas hydrophila*. Appl. Microbiol. 26:550-553.
- Shotts, E.B., Vanderwork, V.L. and Campbell, L.N. 1976. Occurrence of R-factors associated with *Aeromonas hydrophila* isolated from aquarium fish and waters. J. Fish. Res. Bd. Can. 33:736-740.
- Simpson, D.M. and Ross, R. 1972. The neutrophil leukocyte in wound repair: a study with antineutrophil serum. J. clin. Invest. 51:2009-2023.
- Singhal, R.N., Jeet, S. and Davies, R.W. 1987. Experimental transmission of *Saprolegnia* and *Achlya* to fish. Aquaculture. 64:1-7.
- Smith, G.M. 1931. The occurrence of melanophores in certain experimental wounds of the gold fish (*Carassius auratus*). Biol. Bull. mar. biol. Lab., Woods Hole. 61:73-83.
- Smith, H.M. 1965. Freshwater fishes of Siam or Thailand. Bulletin 188, United States National Museum. 465-474 pp.
- Smith, C.E. and Piper, R.G. 1972. Pathological effects in formalin-treated rainbow trout (*Salmo gairdneri*). J. Fish. Bd. of Can. 29(3):328-329.

- Snieszko, S.F. 1974 The effects of environmental stress on outbreaks of infectious diseases in fishes. *J. Fish Biol.* 6:197-208.
- Snieszko, S.F. and Axelrod, H.R. 1971. Disease of Fishes. Book 2A: Bacterial diseases of fishes. T.F.H. Publications.
- Snieszko, S.F. and Bullock, G.L. 1976. Diseases of freshwater fishes caused by bacteria of the genera *Aeromonas*, *Pseudomonas* and *Vibrio*. FDL-40. USDI, FWS. 10 pp.
- Snieszko, S., Piotrowska, W., Kocylowski, B. and Marex, K. 1938. Badania bakteriologiczne i serologiczne nad bakteriami posocznicy karpi. Rozprawy biologiczne Zakresu macyliny watery-naryjnet, rolnictwaihodowi 21:Zesz (1-2)
- Sohnle, P.G. and Chusid, M.J. 1983. Defense against infection with filamentous fungi in rainbow trout. *Comp. Biochem. Physiol.* 74A(1):71-76.
- Sparrow, F.K. Jr. 1960. Aquatic Phycomycetes. University of Michigan Press, Ann Arbor, Michigan.
- Spiczakow, T. 1933. Posocznica Karpi (Septicaemia haemorrhagica cyprinorum). *Przeglad Rybacki.* 6:253-265.
- Srivastava, R.C. 1976. Studies on fungi associated with fish disease. Ph.D. thesis, University of Gorakhpur, Gorakhpur, India.
- \_\_\_\_\_ 1980a. Studies in fish-mycopathology. A review. PartII. *Mykosen.* 23:380-391.
- \_\_\_\_\_ 1980b. Fungal parasites of certain freshwater fishes of India. *Aquaculture.* 21(4):387-392.
- Srivastava, R.C. and Srivastava, G.C. 1977. *Achlya caroliniana* Coker -a new record from India. *Curr. Sci.* 46:422.
- Srivastava, G.C. and Srivastava, R.C. 1977. Host range of *Achlya proliferans* (Nees) de Bary on certain fresh water teleost. *Mycopathologia.* 61:61-62.
- Stunkard, H.W. 1929. The life history of *Cryptocotyle lingua* with notes on the physiology of the metacercariae. *J. Morpho. Physiol.* 50:143-191.



- Sutherland, P.L. 1922. A tuberculosis-like disease in a salt water fish (halibut) associated with the presence of an acid fast tubercle-like bacillus. *J. Path. Bact.* 25:31-35.
- Sutton, J.S. and Weiss, L. 1966. Transformation of monocytes in tissue culture into macrophages epithelioid cells, and multinucleated giant cells. *J. Cell. Biol.* 28:303-330.
- Suzuki, K. 1986. Morphological and phagocytic characteristics of peritoneal exudate cells in tilapia, *Oreochromis niloticus* (Trewavas), and carp, *Cyprinus carpio* L. *J. Fish Biol.* 29:349-364.
- Testrake, D. 1959. Estuarine distribution and saline tolerance of some Saprolegniaceae. *International Journal of Experimental Botany.* 12:147-152.
- Thorpe, J.E. and Roberts, R.J. 1972. An Aeromonad epidemic in the brown trout (*Salmo trutta* L.). *J. Fish Biol.* 4:441-451.
- Thune, R.L., Graham, T.E., Riddle, L.M. and Amborski, R.L. 1982a. Extracellular products and endotoxin from *Aeromonas hydrophila*: effects on age-0 channel catfish. *Trans. Am. Fish. Soc.* 111:749-754.
- \_\_\_\_\_ 1982b. Extracellular proteases from *Aeromonas hydrophila*: Partial purification and effects on age-0 channel catfish. *Trans. Am. Fish. Soc.* 111:749-754.
- Tiffney, W.N. 1939a. The host range of *Saprolegnis parasitica*. *Mycologia.* 31:310-321.
- \_\_\_\_\_ 1939b. The identity of certain species of Saprolegniaceas parasitic to fish. *J. Elisha Mitch. Sci. Soc.* 55:134-153.
- Tiffney, W.N. and Wolf, F.T. 1937. *Achlya flagillata* as a fish parasite. *J. Elisha Mitch. Sci. Soc.* 53:298-300.
- Timur, G. 1975. Study of giant cells in inflammatory lesions of the plaice (*Pleuronectes platessa*). Ph.D. thesis, University of Stirling, Scotland.
- Timur, G., Roberts, R.J. and McQueen, A. 1977. The experimental pathogenesis of focal tuberculosis in the plaice (*Pleuronectes platessa*). *J. Comp. Path.* 87:83
- Timur, M. 1975. A study of carrageenin granuloma in the plaice, (*Pleuronectes platessa* L.). Ph.D. thesis, University of Stirling, Scotland.

- Timur, M., Roberts, R.J. and McQueen, A. 1977. Carrageenin granuloma in the plaice (*Pleuronectes platessa*): a histopathological study of chronic inflammation in a teleost fish. *J. Comp. Path.* 87:89
- Tonguthai, K. 1985. A preliminary account of ulcerative fish diseases in the Indo-Pacific Region (A comprehensive study based on Thai experiences). National Inland Fisheries Institute, Bangkok, FAO/TCP/ RAS/ 4508. 39 pp.
- Trust, T.J. and Sparrow, R.A.H. 1974. The bacterial flora in the alimentary tract of freshwater salmonid fishes. *Can. J. Microbiol.* 17:1101-1103.
- Tungtongphairoj, M. 1981. Life history of pla chon (*Ophicephalus striatus* Bleeker). National Inland Fisheries Institute Technical Paper No. 2/1981. 40 pp. (in Thai)
- Van Oosten, J. 1957. The skin and scales. In: *The Physiology of Fishes*. Vol.1 Ed. M.E. Brown. New York, Academic Press. 207-244 pp.
- Vasu, B.S. 1962. Cutaneous sense organ in *Ophicephalus striatus* (Bloch). *Curr. Sci. Bangalore.* 31:337-338.
- Ventura, M.T.H. 1985. Lesions associated with natural and experimental infections of *Aeromonas hydrophila* in channel catfish and evaluation of portals of entry. M.S. thesis, Department of Fisheries and Allied Aquaculture, Auburn University.
- Ventura, M.T.H. and Grizzle, J.M. 1987. Evaluation of portal of entry of *Aeromonas hydrophila* in channel catfish. *Aquaculture.* 65(3-4):205-214.
- Vishniac, H.S. and Nigrelli, R.F. 1957. The ability of Saprolegniaceae to parasitize platy fish. *Zoologica.* 42:131-134.
- Vivekanandan, E. 1976. Effects of feeding on the swimming activity and growth of *Ophicephalus striatus*. *J. Fish Biol.* 8:321-330.
- Vivekanandan, E. 1977. Ontogenetic development of surfacing behaviour in the obligatory air-breathing fish *Channa (Ophicephalus) striatus*. *Physiol. Behav.* 18:559-562.
- Viziam, C.B., Matolsty, A.G. and Mescon, H. 1964. Epithelialization of small wounds. *J. invest. Derm.* 43:499-507.

- Volkman, A. and Gowans, J.L. 1965. The production of macrophages in the rat. Br. J. Exp. Path. 46:50.
- Wakabayashi, H., Kanai, K, Hsu, T.C. and Egusa, S. 1981. Pathogenic activities of *Aeromonas hydrophila* biovar *hydrophila* (Chester, PoPoff & Vernon 1976) to fishes. Fish. Pathol. 15(3-4):319-325.
- Warren, J.H. 1917. Observations on the formation of giant cells in tuberculosis. J. Med. Res. 36: 225-230.
- Watson, L.J., Shechmeister, I.L. and Jackson, L.L. 1963. The hematology of goldfish, *Carassius auratus*. Cytologia. 28:118-130.
- Weber, M. and Beaufort, L.F. 1922. The fishes of the Indo-Australian Archipelago IV. 312-330 pp.
- Wee, K.L. 1982. Snakehead: Their Biology and Culture. In: Recent Advances in Aquaculture. Ed. J.F. Muir and R.J. Roberts. Croom Helm, London. 446pp.
- Weinreb, E.L. 1959. Studies on the histology and histopathology of the rainbow trout, *Salmo gairdneri irrideus*. II. Effects of induced inflammation and cortisone treatment on the digestive organs. Zoologica (N.Y.) 44:45-52.
- \_\_\_\_\_ 1963. Studies on the fine structure of teleost blood cells. 1. Peripheral blood. Anatomical Record. 147:219-238.
- Weinreb, E.L. and Weinreb, S. 1969. A study of experimentally induced endocytosis in a teleost. I. Light microscopy of peripheral blood cell responses. Zoologica (N.Y.). 54:25-34.
- Whitear, M. 1970. The skin surface of bony fishes. J. Zool., Lond. 160:437-454.
- Willey, A. 1910. Observations on the nests, eggs and larvae of *Ophicephalus striatus*. Spol. Zeyl. 8:108-123.
- Wilson, R.P. and Poe, W.E. 1973. Impaired collagen formation in the scorbutic channel catfish. J. Nutr. 103:1359-1364.
- Winter, C.A. 1964. Anti-inflammatory testing methods: comparative evaluation of indomethacin and other agents. In: Non-steroidal Anti-inflammatory Drugs. Ed. S. Garattini and M,N.G. Dukas. Excerpta Medica Internat. Cong. Series. No. 82. 190 pp.

- Wolke, R.E. 1975. Pathology of bacterial and fungal disease affecting fish. In: The Pathology of Fish. Ed. W.E. Ribelin and G. Migaki. University of Wisconsin Press, Madison, London. 33-116 pp.
- Wolke, R.E. and Stroud, R.K. 1978. Piscine Mycobacteriosis. In: Mycobacterial Infection of Zoo Animals. Ed. R.T. Montali. Suethscru Institute Press.
- Wolke, R.E. and Trainer, F.R. 1971. Granulomatous enteritis in *Catostomus commersoni* associated with diatoms. J. Wildl. Dis. 7:76-79.
- Wrathmell, A.B. and Parish, N.M. 1980. Cell surface receptors in the immune response in fish. In: Phylogeny of Immunological Memory. Ed. M.J. Manning. Elsevier, North Holland Biomedical Press, Amsterdam. 143-152 pp.
- Yamada, J. 1964. On the features of scales developed in the regenerated skin of the goldfish, with special reference to the formation of their ridges. Bull. Fac. Fish. Hokkaido Univ. 14:199-207.
- Yamada, J. 1968. A study on the structure of surface cell layers in the epidermis of some teleosts. Annotes Zool. Jap. 4(1):1-8.
- Yapchiongo, J.V. and Demonteverde, L.C. 1959. The biology of dalag (*Ophicephalus striatus* Bloch). The Philippine Journal of Fisheries. 7(1-2):105-140.
- Zweifach, B.W., Grant, L. and McCluskey, R.J. 1965. The Inflammatory Process. New York, Academic Press. 931 pp.