



Contents lists available at ScienceDirect

Performance Enhancement & Health

journal homepage: www.elsevier.com/locate/peh



“A slippery slope”: a scoping review of the self-injection of unlicensed oils and fillers as body enhancement

Rebekah Brennan^{a,*}, Marie Overbye^b, Marie Claire Van Hout^c, James McVeigh^d

^a University College Cork, Cork, Ireland

^b University of Stirling, UK

^c Liverpool John Moores University, Liverpool, UK

^d Manchester Metropolitan University, Manchester, UK

ARTICLE INFO

Article history:

Received 22 July 2020

Received in revised form

10 December 2020

Accepted 10 December 2020

Available online xxx

Keywords:

Body image enhancement

Human enhancement drugs

DIY body enhancement

Self injection of body fillers

Negative body image

ABSTRACT

Self-injection of a range of oils and fillers for body enhancement dates back to 1899, but due to significant associated harms and fatalities this practice has been largely linked to distinct cultural groups in recent times. This scoping review gathers what is currently known on the self injection of body fillers for aesthetic purposes, using Arksey and O'Malley's (2005) five stage iterative process scoping review methodology. Thematic manual coding then organised the data into themes through identified patterns: indicative profiling of individuals who self inject body fillers; motivation for use across types of oil injection; sourcing routes and documented harms. It was found that the majority of people who inject body fillers are male and do so to grossly increase muscle size. Injection of oils and other materials in the male genitalia was also described, in addition to female self-injection in the breast, hand and leg areas for augmentation. A range of health consequences were reviewed. Recommendations are made for further research into this unique phenomenon, which although is relatively rare warrant future research attention considering the documented increase in DIY facial fillers and contemporary body image culture.

© 2020 Elsevier Ltd. All rights reserved.

Contents

1. Background	00
2. Methods	00
3. Results	00
3.1. Profile of studies reviewed	00
3.2. Theme 1: Indicative profiling of individuals who self-inject body fillers	00
3.2.1. Muscle enhancement in males	00
3.2.2. Genital enhancement in males	00
3.2.3. Breast enhancement in females	00
3.2.4. Hand rejuvenation in females	00
3.2.5. Other	00
3.3. Theme 2: Motivation for use across types of oil injection	00
3.3.1. Muscle enhancement in males	00
3.3.2. Genital enhancement in males	00
3.3.3. Breast enhancement in females	00
3.3.4. Hand rejuvenation in females	00
3.3.5. Other	00
3.4. Theme 3: Sourcing routes	00

* Corresponding author.

E-mail address: rebekah.brennan@ucc.ie (R. Brennan).

¹ @RebekahLBrennan.

3.5.	Theme 4: Documented Harms	00
3.5.1.	Muscle enhancement in males	00
3.5.2.	Genital enhancement in males	00
3.5.3.	Breast enhancement in females	00
3.5.4.	Hand rejuvenation in females	00
3.5.5.	Other	00
4.	Discussion	00
5.	Conclusion	00
	Funding Sources	00
	Acknowledgements	00
	References	00

1. Background

The injection of unlicensed materials to change the appearance of the body was first documented in 1899 by an Austrian surgeon, Robert Gersuny, who injected vaseline into the scrotum of a patient who had undergone bilateral orchiectomy for genital tuberculosis (Gersuny, 1980). The practice of injecting body filler further popularised over the first twenty years of the twentieth century, expanding from quasi-medical use to purely cosmetic enhancement (in areas such as the breast or the penis) with paraffin building a reputation as a superior material to vaseline (Glicenstein, 2007). Despite emergent warnings about associated health harms, paraffin oil injections continued into the 1950s and 1960s particularly in the Far East (Peters & Fornasier, 2009) and in Italy (Di Benedetto, Pierangeli, Scalise, & Bertani, 2002). However, as reports of sporadic deaths began to emerge, the popularity of oil injection in the mainstream began to decline (Figueiredo, da Silva, De Souza, & De Rose, 2011; Peters & Fornasier, 2009).

Thereafter, self-injection for body enhancement has been largely linked to distinct cultural groups. A range of oils and fillers have been documented as being injected to enhance body parts, including unlicensed materials such as Johnsons brand Baby oil, mechanical transmission oil and vaseline (Figueiredo & Da Silva, 2014). One example is that of “Synthol” or “Syntherol” (typically 85% fat, 7.5% lidocaine and 7.5% alcohol), synonymous with bodybuilding culture since Christopher Clark, a German bodybuilder began to market “Esielene” (Formebolone) to augment the appearance of muscle, specifically to boost the definition of lagging muscle groups for competitive bodybuilding (Hall, Grogan, & Gough, 2016; Juel, Vestergaard Grejsen, & Pareek, 2017; Schafer, Hvolris, Karlsmark, & Plambech, 2012). Despite being widely described in the literature (Brennan, Kanayama, & Pope, 2013; Brennan, Van Hout, & Wells, 2013; Figueiredo & Da Silva, 2014; Schafer, Guldager, & Jorgensen, 2011, 2012) the injection of oils or fillers has a complex relationship with both professional and recreational bodybuilding communities, stigmatised where individuals inject large amounts (Hall et al., 2016) and sometimes even where small amounts are injected. “Synthol” has been documented as being rejected by the majority of bodybuilders, at least publicly, as ‘cheating’ in striving to quickly attain a physique which typically demands a great deal of training and discipline (Salinas, Floodgate, & Ralphs, 2019). The grossly exaggerated outcomes that are sometimes achieved through oil injection are also often a subject of disdain (Brennan, 2018). Existing survey data indicates that 5% of bodybuilders report ever injecting “Synthol” or other oils (Azevedo & Ferreira, 2009; Ghandourah, Hofer, Kießling, El-Zayat, & Schofer, 2012; Schafer et al., 2012).

Injection of body fillers such as paraffin, silicone and other materials for body enhancement in the breasts, buttocks and genitals has been previously described in transgender communities (Hage, Kanhai, Oen, Van Diest, & Karim, 2001; Restrepo et al., 2009; Wilson,

Rapues, & Raymond, 2014), often performed by backstreet doctors or beauticians (Carella, Romanzi, Ciotti, & Giuseppina Onesti, 2013). Penile self-injection for girth augmentation is described as being rare and primarily located in Asian and Eastern European countries (Figueiredo & Da Silva, 2014; Markopoulos et al., 2006; Pehlivanov, Kavaklieva, Kazandjieva, & Tsankov, 2008).

Harms documented as being associated with the injection of foreign body materials for aesthetic enhancement include paraffinoma, migration of the material, nodule formation, inflammation, foreign body granuloma, tissue necrosis (Ahmed et al., 2017), severe hypercalcaemia (e.g. Gyldenløve, Rørvig, Skov, & Hansen, 2014), chronic wounds and ulceration (Ikander, Nielsen, & Sørensen, 2015a) and in the case of penile augmentation, deformation, impaired sexual functioning and voiding difficulties (Pehlivanov et al., 2008). Harms can become evident several years after injection (Juel et al., 2017), with no records of these types of unlicensed materials being absorbed into the body or dissolving naturally in any other manner (Cohen, Keoleian, & Krull, 2002; Lee, Choi, Lee, & Lee, 1994; Steffens et al., 2000). The severity of intramuscular injections with paraffin oil has been underscored by Koldkjær Sølling et al. (2018) highlighting that no curative treatment currently exists.

Currently, body enhancement through DIY cosmetic procedures appear to be increasing (Thomas, Lee, Patton, & Choudhary, 2020; Torre, Murphy, & Ricketts, 2019), supported by online social media discourse (Hopkins, Moreno, & Secrest, 2020; Underwood, 2017), popular use of facial ‘filters’ and ‘selfie’ editing apps (Alkarzae, Aldosari, Alalula, Almuahaya, & Alawadh, 2020; Barker, 2020; Butkowski, Dixon, & Weeks, 2019) and celebrity “fandom” (Underwood, 2017). In 2018, a study which conducted content analysis of online discussion forum posts documented for the first time the self-injection of Botox and dermal filler through DIY “kits” purchased online by members of the general population (Brennan, Wells, & Van Hout, 2018). Since then, clinical case reports have emerged where individuals have self-injected similarly, with harms documented (Thomas et al., 2020; Torre et al., 2019). This new evidence may indicate an emergent trend of self-injection of facial materials for cosmetic enhancement. It is of interest where self-injection of body fillers is situated in this suggested trend of DIY body enhancement, as it has been documented as being subject to scorn within groups of people who use other human enhancement drugs (HED) for aesthetics, such as anabolic androgenic steroids (AAS) (Hall et al., 2016; Salinas et al., 2019) and the literature suggests that acceptable use of body filler may have much narrower margins. While acknowledging that people who inject body fillers are a heterogeneous group, who inject different materials for different reasons, this paper aims to collate and describe what is known on motivators for self-injection of oils, sourcing routes and harms. Why and how do people inject oils for body enhancement despite the associated stigma? What are the implications of injection of body fillers becoming mainstreamed as a contemporary trend, as indicated in the literature on DIY facial fillers? In discussing the findings of this review, the authors aim to further discussion

Table 1
Key search terms.

Language	Search Terms
English	'Paraffin oil injection', 'site enhancement oil injection', 'muscle fillers', 'body fillers', 'polyvitamin injection', 'synthol injection'
Danish	'paraffinolieinjektion', 'Site enhancement oil' injektion ('lokal olieinjektion'; 'muskelfremhævende olieinjektion'); 'muskelfremhævende'; 'multivitamin injektion'/'polyvitamin injektion', 'synthol injektion' ('synthololieinjektion')

on a dichotomous practice, on “trend” with contemporary body enhancement culture, yet historically stigmatised within it. This is the first known review of the literature on body enhancement through injection of fillers and oils. Although relatively rare, this review highlights types of injecting which warrant future research attention. This review aims to inform enhanced clinical reporting and seeks to raise awareness of potential harms so that a robust evidence base for effective interventions can be developed.

2. Methods

Scoping reviews are appropriate where broader research questions exist (Arksey & O'Malley, 2005; Khalil et al., 2016; Levac, Colquhoun, & O'Brien, 2010; Peters et al., 2015). They are used to identify gaps in knowledge, examine the extent (i.e. size), range (i.e. variety), and nature (i.e. characteristics) of the evidence on a certain topic or question (in this case, self-injection of body filler for cosmetic purposes), summarise findings from a wide range of sources and make research and policy recommendations (Arksey & O'Malley, 2005; Brandt, King, & Evans-Brown, 2014; Daudt, van Mossel, & Scott, 2013; Levac et al., 2010; Tricco et al., 2016). The research team for this review adhered to Arksey and O'Malley's (2005) five stage iterative process scoping review methodology. These stages included the following: (1) identifying the essential research question, (2) identifying relevant studies, (3) study selection, (4) charting the data, and (5) collecting, summarising, and reporting the results. The process was underpinned by the research question (“What is known about self-injection of body filler for aesthetic purposes?”) and reviewed all available published empirical and grey literature in the English and Danish language on this topic (grey literature appears in searches conducted on many of these databases). The reference list of included studies was also scrutinised for relevant studies. There was no restriction on date of publication or study type. The search was implemented in June 2020. The following databases were accessed: Web of Science; Cochrane Library; MEDLINE; PsycINFO; Social Science Citation Index; PubMed; Science Direct; and Researchgate. Key search terms identified by a transnational research team, who have research expertise in human enhancement drugs, informed the search strategy (see Table 1). Searches were run in English and Danish. The research team proactively sought out a collaboration with an interested Danish academic as we were aware of a number of Danish language papers and were not aware of any other non-English language ones. In addition to this rationale, the only specialist treatment providers we are aware of are in Denmark.

These search terms were searched separately and not combined, in line with the purpose of a scoping review to a broad range of literature and grey literature i.e. what is currently known on the topic.

Eligibility criteria focused on the self-injection of body fillers and oils for aesthetic purposes. Inclusion and exclusion criteria were discussed and agreed with all members of the research team (Table 2).

Table 2
Eligibility criteria.

Inclusion Criteria	Exclusion Criteria
English or Danish articles	Articles in any other language
Articles which referred to injection of oils for cosmetic purposes	Articles which referred to injection of oils for medical purposes
Articles which referred to body filler injection	Articles which referred to facial filler injection

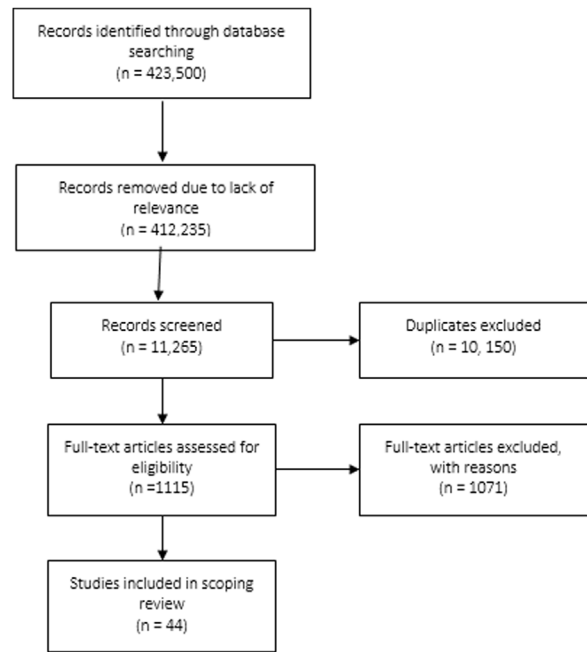


Fig. 1. Flow chart.

The initial search, conducted by author one, identified 423,500 records; and following initial screening, 412,235 were removed for lack of relevance, with the remaining 11,265 screened for inclusion in the study. Finally, duplicates (n = 10,150) and further records were removed which were not relevant to self-injection (n = 1071), leaving 44 records in total (see Fig. 1). The 44 records were charted and thematically analysed by author one, as per Arksey and O'Malley (2005).

Firstly, a table was created (see Table 3) to chart relevant data (year of publication, author, location, method and aim, key findings) and to analyse the extracted data thematically to identify commonalities, emergent issues, and gaps in the literature. Second, to help evaluate the nature and types of studies within each area the studies were classified into area of oil injection site into five areas - i.e. muscle enlargement; penis enlargement; breast enlargement; hand rejuvenation; and others (Table 4). Third, a qualitative content analyses was performed. More specifically the textual dataset was re-read numerous times by author one in order to become familiar with the data and identify and code emerging themes. Thematic manual coding then organised the data and subsequently structured into themes through patterns identified in associated categories (Crossley, 2007). The articles written in Danish language were translated and coded following the same procedure (by author two). Themes were reviewed and cross checked by authors two, three and four. Four themes were identified from the review: (1) indicative profiling of individuals who self-inject body fillers; (2) motivation that varied for use (that varied) across types of oil injection; (3) sourcing routes and (4) documented harms (including treatment applied).

Table 3
Studies Reviewed.

No	Date	Country	Type of Study	Title	Authors	Aim	Methods	Findings
1	2020	Canada	Clinical case report.	Myositis from intramuscular oil injections in a bodybuilder.	Prosperi-Porta, G., Oleynick, C. & Vaughan, S.	To document presentation of a clinical case of medical complications attributed to intramuscular oil injections.	Case report.	A 32-year-old male presented with bilateral upper-arm erythema, pain and swelling, with self-reported synthol injections administered ten years previously. An erythematous patch was discovered in the bicep area alongside plaque-like, multinodular heterogeneous tissue, fibrosis, a chronic lymphocytic infiltrate and multinucleated foreign-body giant cell reaction. The patient was treated with prednisone and was awaiting a bicep resection procedure at time of writing due to multiple flare ups.
2	2020	San Diego, U.S.	Conference presentation.	Acute Hypoxic Respiratory Failure and Diffuse Alveolar Haemorrhage Due to Intramuscular Injection of an Oil-Based Cosmetic Substance	Parkhurst, C.N., Weir, D.C., Rajwani, K. et al.	To document presentation of a clinical case of medical complications attributed to intramuscular oil injections.	Case report.	A 30 year old male with a history of anxiety and depression presented with fatigue and a dry cough for a week, he had self-reported use of cocaine, unprotected sex, and use of Synthol in his pectoral muscles. Acute lung injury to include acute respiratory failure and diffuse haemorrhage due to intramuscular injection of "Synthol" was diagnosed.
3	2020	Italy	Clinical study.	An overview on performance and image enhancing drugs (PIEDs) confiscated in Italy in the period 2017–2019.d	Odoardi, S., Mestria, S., Biosia, G et al.	To ascertain the composition of performance and image enhancement drugs (PIEDS) purchased online, and to evaluate the correspondence between what was declared on the label and the actual content, or to identify unknown products.	Confiscated products were analyzed by gas chromatography/mass spectrometry and liquid chromatography/high-resolution mass spectrometry.	Of sixteen products analysed where no active drug was detected, oils for injection in a sample marketed with the name "Synthol" were discovered.
4	2019	Russia	Clinical case report series.	Injected non-absorbable fillers in large volumes.	Sharobaro, V.I., Manturova, Yu. V., Ivanov, A.E. et al.	To present treatment strategy for large volumes of injectable non-absorbable soft tissue fillers (Vaseline, synthol, silicone etc.).	Case report (n = 8).	The injection of Vaseline into the breast area was found in 5 females and the injection of synthol into the muscle found in 3 males. Numerous harms were documented including cysts, inflammation, fibrosis and migration of fillers. Surgery was found to be the only option for treatment, leading to scars.
5	2019	Turkey	Clinical case report.	Exogenous Lipoid Pneumonia Due To Intramuscular Injection of Synthol in a Bodybuilder	Öcal, N., Gunal, A., Arslan, Y. et al.	To document presentation of a clinical case of medical complications attributed to intramuscular oil injections.	Case report.	A 40-year-old male presented with shortness of breath and chest pain, progressing within a year. He disclosed injecting use of "Synthol" into the pectoral and brachial muscles. The medical diagnosis given was lipoid pneumonia.

Table 3 (Continued)

No	Date	Country	Type of Study	Title	Authors	Aim	Methods	Findings
6	2018	Denmark	Clinical case report.	Bigoreksi med paraffinømdannelse kan give hyperkalcaemi [Paraffin oil injections due to bigorexia may cause hypercalcaemia]	Nerild, H.H.; Theilade, K.S. & Eldrup, E.	To document presentation of a clinical case of medical complications attributed to intramuscular oil injections.	Case report.	A 39-year-old male presented with severe hypercalcaemia and renal failure due to paraffin oil injections. The disease recurred the next two summers probably due to erroneous vitamin D supplement and sun exposure.
7	2018	Canada	Case Series and a Literature Review	"Fake Popeye Muscles". Soft Tissue Granulomas Secondary to Intramuscular Synthetic Oil Injections in Bodybuilding. Case Series and a Literature Review	AlShaqsí, S., A Qader Ali, M. & Albulushi, T.	To review the history of site enhancement oil injection in bodybuilding, and to document five clinical cases of granuloma attributed to site enhancement oil injection.	Case report (n = 5) and desk review.	Five cases of pathological massive muscle granulomas were found in male amateur bodybuilders. A literature review highlighted many consequences of "Synthol" injection including post injection pain and tenderness, irregularity and contour deformities, intravenous injections leading to cardio-respiratory problems and long-term chronic granulomatous disease.
8	2018	Denmark	Clinical case series report.	Non-parathyroid hypercalcemia associated with paraffin oil injection in 12 younger male bodybuilders: a case series	Sølling, K.A.S., Tougaard, B.G., Harsløf, T. et al.	To document a series of clinical case presentations of medical complications attributable to paraffin oil injections.	Case report.	A case series of 12 male bodybuilders who presented with non-parathyroid hypercalcemia. All had a history of using paraffin oil injections and were admitted on average five (range: 1–8) years after the injections.
9	2017	Turkey	Clinical case report.	The First Reported Case of Breast Granulomas Secondary to Huge Amount of Baby Oil Self-injection	Agac, A., Akturan, S., Hilal Guclu, T., et al.	To document presentation of a clinical case of medical complications attributed to oil injections in the breasts.	Case report.	A 46 year old female injected her breasts with baby oil with a syringe, 200 cc for each breast which resulted in sclerosing adenosis and foreign body granulation tissue.
10	2017	United Kingdom	Clinical case series report.	Self-injection of foreign materials into the penis	Ahmed, U., Freeman, A., Kirkham, A., et al.	To document presentation of a clinical case of medical complications attributed to oil injections in the penis.	Case report.	One case (male, 28) of penile oedema resulting in a phimosis due to self-injection of baby oil. One case (male, 61) of large, firm nodular masses in the penis and scrotum due to self-injection of baby oil. One case (male, 35) of indurated nodular masses along the shaft of the penis due to injections of silicone. One case (male, 41) of marked lymphoedema with a number of indurated nodules of varying size due to self-injection of silicone. One case (male, 47) a diffusely oedematous penile shaft with a number of indurated masses due to self-injection of mechanical oil.
11	2017	Lebanon	Clinical case report	Hypercalcemia and nephrocalcinosis induced by pump and pose intramuscular injection	Chiri, R., Gabriel, K., Chelala, D. et al.	To document presentation of a clinical case of medical complications attributed to intramuscular injections of "Synthol" and paraffin oil.	Case report.	A 30 year old male presented with severe hypercalcemia complicated by recurrent episodes of pancreatitis and nephrolithiasis following intramuscular injection of synthol and paraffin, and caused by formation of a granulomatous reaction to the foreign body in the muscle.

Table 3 (Continued)

No	Date	Country	Type of Study	Title	Authors	Aim	Methods	Findings
12	2017	Korea	Clinical case report and literature review.	Paraffin Granuloma Associated with Buried Glans Penis-Induced Sexual and Voiding Dysfunction	Chon, W., Yun Koo, J., Jung Park, M., et al.	To document presentation of a clinical case of medical complications attributed to injections of paraffin oil in the penis.	Case report.	A 64 year old male presented with penile pain and voiding dysfunction causing him to cease all sexual activities, after injecting paraffin oil in his penis in his early 30 s, was diagnosed with paraffin granuloma.
13	2017	USA	Clinical case report.	Pneumonitis and Acute Hypoxemic Respiratory Failure Following Synthol Intramuscular Injection in a Bodybuilder	Elfituri, A; Akkineni, S; Bebars, H. et al.	To document presentation of a clinical case of medical complications attributed to intramuscular injections of "Synthol".	Case report.	A 44 year old male presented with chest tightness, dyspnea, fever and chills after self-injecting "Synthol" intramuscularly. He was diagnosed with acute hypoxemic respiratory failure and pneumonitis.
14	2017	Denmark	Clinical case report.	Long-term adverse effects of intramuscular oil injection	Juel, J., Vestergaard Grejsen, D. et al	To document presentation of a clinical case of medical complications attributed to intramuscular injections of paraffin oil.	Case report.	A 33 year old male presented with painful swellings (paraffinomas) and paraesthesia attributed to paraffin oil injections for muscular enhancement ten years previously.
15	2017	USA	Clinical case report.	Intramuscular Steroid Injections for the Treatment of Wrist Drop Due to Excessive use of Muscle Enhancement Oil Site Injections: A Case Report	Leary, D., Smith, M.D. & Kent, R. E.	To document presentation of a clinical case of medical complications attributed to intramuscular injections of "Synthol".	Case report.	A 36 year old male (bodybuilder) with extreme wrist pain and limited wrist mobility due what medical professionals deemed "excessive" use of "Synthol" injected into muscle "heads" in the bicep region.
16	2017	Denmark	Clinical Case Report.	CT Findings Following Repeated Intramuscular Injections of "Site Enhancement Oil" in the Upper Extremities	Dejanović, D. & Loft, A.	To document presentation of a clinical case of medical complications attributed to intramuscular injections of "Synthol".	Case report.	A 50-year-old man known to self-administer intramuscular injections with site enhancement oil, presented with muscles in the upper arm appearing swollen with a moth-eaten appearance and surrounding edema and several "cystic" lesions diagnosed as oleomas.
17	2016	United Kingdom	Qualitative, exploratory	Bodybuilders' accounts of synthol use: The construction of lay expertise online	Hall, M., Grogan, S. & Gough, B.	To explore how lay expertise is worked up by Internet forum discussants in order to be able to provide each other with support and advice on their injecting use of "Synthol".	Content analysis of online forum discussion posts.	Forum discussants offered each other support and advice on how to inject "Synthol" safely and in order to achieve the best results. Individuals sought a natural result, however authors noted that these same results may appear "freakish" to others.
18	2016	Denmark	Clinical case report.	Extracorporeal membrane oxygenation after intravenous injection of paraffin oil.	Pasgaard, T., Thi Huynh, A & Gjedsted, J.	To document presentation of a clinical case of medical complications attributed to an accidental intravascular injection of paraffin oil.	Case report.	A 30-year-old male was admitted to the Emergency Department with acute onset respiratory distress following an accidental intravascular injection with paraffin oil, which the individual had been injecting intramuscularly for cosmetic purposes.

Table 3 (Continued)

No	Date	Country	Type of Study	Title	Authors	Aim	Methods	Findings
19	2015	Denmark	Clinical case report.	Injektion af synthololie hos bodybuilder gav kroniske sår og deformerende ar [Injection of synthol in a bodybuilder can cause chronic wounds and ulceration]	Ikander, P., Nielsen, A.M., Sørensen, J.A.	To document presentation of a clinical case of medical complications attributed to intramuscular injections of oils or other materials.	Case report.	One male (45 years old) presented with ulcerations, chronic wounds, pain or tenderness, following intramuscular "Synthol" and paraffin injections. Five other cases of individuals with symptoms related to SEO injections who consulting the doctors (plastic surgeons) within a short period of time (only a few months) are also presented briefly. Among these are four users of paraffin oil injection (age 21 to 38) and one user of synthol injection (age 25).
20	2015	Denmark	Clinical case report.	Subacute fat-embolism-like syndrome following high-volume intramuscular and accidental intravascular injection of mineral oil.	Hjort, M., Hoegberg LC: Almind, M. et al.	To document presentation of a clinical case of medical complications attributed to an accidental intravascular injection of mineral oil.	Case report.	A 40 year old male presented with a case of subacute fat-embolism-like syndrome (FES-like) following an accidental intravascular injection of mineral oil- steroid solution with delayed diagnosis, acute onset of pulmonary distress, and transient clinical deterioration.
21	2015	Denmark	Clinical case report.	Intramuscular Injection of "Site Enhancement Oil": Forensic Considerations	Petersen, M.L., Colville-Ebeling, B., Jensen, T.H.L., et al.	To document presentation of a clinical case of medical complications attributed to "Synthol" injections.	Case report.	A case of site enhancement oil use in a 42-year-old man who died from asphyxia due to hanging. Macroscopic and microscopic changes as well as computed tomographic changes in injected musculature are described and the potentially lethal adverse effects after site enhancement oil use are warranted.
22	2015	Brazil	Clinical case report	Oleoma treated with oral colchicine: Report of two cases and review of the literature.	Lym, C.I., Nakasato, F.K., Menezes, et al.	To document presentation of two clinical cases of medical complications attributed to injections of oils or other materials.	Case report.	A 47 year old woman presented with pain and hyper pigmented plaques on the lower limbs. At first oil injection was denied but the patient later disclosed injecting a "muscle strengthening oil" into her calves, but unable to say what the oil was or the volume. A 59 year old woman presented with painful nodules injecting silicone in her thighs for aesthetic purposes.
23	2014	Denmark	Clinical case report.	Severe hypercalcaemia, nephrocalcinosis, and multiple paraffinomas caused by paraffin oil injections in a young bodybuilder	Gyldenløve, M., Rørvig, S., Skov, L., et al.	To document presentation of a clinical case of medical complications attributed to intramuscular injections of paraffin oil.	Case report.	A 23 year old male bodybuilder presented with scrotal pain, and was diagnosed with severe hypercalcaemia, nephrocalcinosis and multiple paraffinomas caused by paraffin oil injections over a period of three years in the chest, arms and back.
24	2014	Brazil	Literature review and discussion of case reports.	Cosmetic Doping-When Anabolic-Androgenic Steroids are not enough.	Figueiredo, V.C. & Da Silva, P.R.P.	To describe the history and practice of illegal use of muscle fillers.	Desk review.	Although not a new trend, illegal use of muscle fillers has been increasing. This article reviews the available scientific literature up to 2014 and discusses the history of intramuscular oil injection.
25	2013	Italy	Clinical Case report	An unusual delayed complication of paraffin oil injection for penile girth augmentation.	De Siati, M., Selvaggio, O., Di Fino, et al.	To document presentation of a clinical case of medical complications attributed to intramuscular injections of paraffin oil.	Case report.	A 27 year old male with severe penile pain and urinary voiding difficulties was diagnosed with penile paraffinoma five years after self-injection for penis augmentation.

Table 3 (Continued)

No	Date	Country	Type of Study	Title	Authors	Aim	Methods	Findings
26	2013	Korea	Retrospective Review of Clinical Case Reports	Treatment of Foreign Body Granuloma of the Hand Associated with Unregulated Material Injection for Aesthetic Purposes.	Yeo, K.K., Park, T.H., Chang, C. H.	To document presentation of a clinical case of medical complications attributed to injection of paraffin, silicone and unidentified materials into the hand.	Desk review of clinical case presentation reports.	Seventeen cases of self-injection of foreign body granuloma attributed to the injection of various types of filler into the hand for rejuvenation purposes. Four patients were injected with paraffin, 3 patients with silicone oil, and remaining 10 patients with unknown materials. The main symptom was palpable mass and contour deformity.
27	2012	Denmark	Literature review and clinical case report.	Muscle enhancement using intramuscular injections of oil in bodybuilding: review on epidemiology, complications, clinical evaluation and treatment.	Schäfer, C. N., Hvolris, J., Karlsmark, T. et al.	To document presentation of a clinical case of medical complications attributed to AAS injection and one case of turpentine oil injection in a female.	Desk review of literature and a case report.	A review of the literature and available case reports of AAS injection intramuscularly in bodybuilding groups and one case of turpentine oil injection in a female, purposes unspecified. Although fairly uncommon the health consequences may be significant.
28	2012	Germany	Literature review and a case report	Irreversible Muscle Damage in Bodybuilding due to Long-Term Intramuscular Oil Injection	Banke, J., Proding, P.M., Waldt, S., Weirich, G., Holzapfel, B.M., Grading, R. & Rechl, H.	To document presentation of a clinical case of medical complications attributed to sesame seed oil injection in a male.	Desk review of literature and a case report	
29	2011	Brazil	Literature review and discussion of case reports.	Cosmetic Doping: the Problems of Intramuscular Application of Oils.	Figueiredo, V. C., da Silva, P.R.P., De Souza, T. et al.	To describe the practice of ADE oil injection intramuscularly and related harms.	Desk review of literature and clinical case reports.	A review of the literature and available case reports of ADE injection intramuscularly in bodybuilding groups. Although fairly uncommon the health consequences may be significant.
30	2011	Denmark	Literature review and clinical case report.	Multi-organ dysfunction in bodybuilding possibly caused by prolonged hypercalcemia due to multi-substance abuse: case report and review of literature	Schäfer, C.N., Guldager, H., Jørgensen, H.L.	To document presentation of a clinical case of medical complications attributed to injection of paraffin and use of other substances to promote muscularity.	Desk review of literature and a case report.	A 26-year-old male bodybuilder with a previous history of infections and chronic ulcers due to paraffin-oil injections in both upper arms one year before developed signs of multi-organ dysfunction, possibly caused by multi-substance-induced hypercalcemia.
31	2010	Turkey	Clinical Case Report.	Self-rejuvenation of the hand	Ozden, B., Arinci, A., Aydin, A et al..	To document presentation of a clinical case of medical complications attributed to injection of Baby oil into the hand.	Case report.	A 51 year old woman repeatedly injected her hands with baby oil over a five year period. The latest injection which was five years previously resulted in, an acute attack of anaphylactic symptoms with massive swelling at the injection sites, which yielded to hard, inflammatory lumps Diagnosis was. sclerosing lipogranulomatosis.
32	2010	Denmark	Clinical Case Report.	Paraffinjektioner hos bodybuildere skal forebygges [Paraffin oil injection in bodybuilders calls for preventive action]	Henriksen, T. F., Lovengald, J.B. & Matzen, S.H.	To document presentation of a clinical case of medical complications attributed to injection of paraffin oil intramuscularly.	Case report.	A 24 year old male self-injected one litre of paraffin oil into each arm. Authors warn of "reverse anorexia". A month after injection the patient develop redness, soreness and ulcers on both arms. Paraffinomas, oedema, scar tissue under the skin and in the muscles were present one year later.

Table 3 (Continued)

No	Date	Country	Type of Study	Title	Authors	Aim	Methods	Findings
33	2010	USA	Clinical Case Report.	1, 25-dihydroxyvitamin D-mediated hypercalcemia in oleogranulomatous mastitis (paraffinoma), ameliorated by glucocorticoid administration.	El Muayed, M., Costas, A. & Pick, A. J.	To document presentation of a clinical case of medical complications attributed to injection of Baby oil intramuscularly.	Case report.	A 58-year-old transgender woman with a history of injecting Baby oil into her chest to create breasts in an effort to transition presented with granulomatous mastitis (paraffinoma)-related hypercalcemia and renal failure. The patient ultimately died 11 months later of multiple paraffinoma related complications.
34	2009	Canada	Literature review and discussion of clinical case reports.	Complications from injectable materials used for breast augmentation.	Peters, W., & Fornasier, V.	To document the history of oil injection for augmentation of the breast and discussion of case presentations.	Case report.	Breast augmentation through injection of materials was common in the beginning of the 19 th century and continued in the Far East in the 1950s and 1960s despite emergent reports of paraffinoma and sporadic deaths. Some self-injection is described. Significant foreign body reactions in females are discussed.
35	2009	Poland	Report	[The usage of synthol in the body building]	Pupka, A., Sikora, J., Mauricz, J., et al.	To describe use of synthol in bodybuilding	Report	The authors describe the composition of Synthol is composed of 85% oil (medium-chain triglycerides), 7.5% lidocaine analgesic, and 7.5% alcohol and the purpose for which it is used in bodybuilding – for muscle augmentation. Associated harms are described.
36	2009	Denmark	Letter to the Editor.	Compression Bandage as Treatment for Ulcers Induced by Intramuscular Self-injection of Paraffin Oil.	Iversen, L.; Lemcke, A.; Bitsch, M et al.	To document presentation of a clinical case of medical complications attributed to paraffin oil intramuscularly.	Case report	A 24 year old bodybuilder with a history of injecting paraffin oil intramuscularly presented with pain in both arms. In total he had injected 1 litre of oil into each arm. He had skin necrosis and ulcers on both arms.
37	2007	Israel	Clinical case series report.	Three cases of penile paraffinoma, a conservative approach.	Rosenburg, E., Romanowsky, I., Asali, M. et al.	To document a series of clinical case presentations of medical complications attributable to paraffin oil injections in the penis.	Case report.	Three cases of penile paraffinoma. All Thai males which the authors refer to as “foreign workers”. Penile pain, difficulty voiding and erectile dysfunction were among the symptoms presented. Penile augmentation was described as rare.
38	2007	USA	Clinical Case Report.	Penile paraffinoma: the delayed presentation.	Eandi, J., Yao, A.P. & Javidan, J.	To document presentation of a clinical case of medical complications attributed to paraffin oil intramuscularly.	Case report.	A 71 year old man presented 40 years after the injection of foreign substances into his penis for the purpose of augmentation with erectile dysfunction, voiding difficulties, and severe deformity. Diagnosis was penile paraffinoma.
39	2003	Italy	Clinical case report.	Paraffinoma of the knee.	Catalano, O.A, Dal Pozzo, F., Grifi, DN	To document presentation of a clinical case of medical complications attributed to injection of paraffin oil into the knee.	Case report.	A 90-year - old man was reported to have a swollen, painful knee and admitted self-injecting paraffin to avoid military service during the Second World War, decades before.

Table 3 (Continued)

No	Date	Country	Type of Study	Title	Authors	Aim	Methods	Findings
40	2003	Germany	Clinical Case report	Self-injection of foreign materials into the penis	Hohaus, K., Bley, B., Köstler, E., et al.	To document presentation of a clinical case of medical complications attributed to oil injections in the penis.	Case report.	A 30-year-old-patient with penile sclerosing lipogranuloma following injections of Vaseline. He was successfully treated by complete surgical removal of the subcutaneous material and excision of atrophic skin, followed by penoplasty. Temporary impairment of wound healing was overcome by application of topical carbon dioxide gas.
41	2002	United Kingdom	Clinical case report.	Grease-gun injury to the penis.	Kalsi, J.S., Arya, M., Peters, J. et al.	To document a case of self-injection of oils in the penis with a grease gun for augmentation.	Case report.	A 31 year old man presented with a self-inflicted injury to the penis after injecting an unidentified oil with a high pressure pneumatic grease gun. Extensive fibrosis and foreign body granulomas were discovered causing loss of erectile function.
42	2001	Denmark	Clinical case report.	Bodybuilding ved hjælp af intramuskulær injektion af valnøddeolie [Body building aided by intramuscular injections of walnut oil]	Munch, I.C. & Hvolris, J.J.	To document presentation of a clinical case of medical complications attributed to injection of walnut oil intramuscularly.	Case report.	A 26-year-old body builder who had practiced several months of intramuscular self-injection of walnut oil, presented with swelling and tenderness overlying an injection site. Diagnosis was foreign body reaction known as paraffinoma and oleomas.
43	2000	Germany	Clinical Case report	Subcutaneous oleomas induced by self-injection of sesame seed oil for muscle augmentation	Darsow, U., Bruckbauer, H., Worret, W. et al.	To document presentation of a clinical case of medical complications attributed to injection of sesame oil intramuscularly.	Case report.	A 48 year old man injected large amounts of sesame seed oil into his pectoral area and presented with subcutaneous nodules and granulomas.
44	1995	Canada	Clinical Case report	Self-injection of olive oil into the scrotum	Bhagat, R., Holmes, I. H., Kulaga, A., et al.	To document presentation of a clinical case of medical complications attributed to olive oil injections in the scrotum	Case report.	A 48-year-old man with unipolar depression and a psychosexual problem concerning his body image was injecting his scrotum approx. every 15 days for 3 years with olive oil to increase the size of his genitals. He developed respiratory failure following accidental intravenous injection of olive oil and was found to have lipogranulomatous lesions in the lung and the scrotum.

Table 4
Indicative profile of people who self-inject body fillers.

No.	Study	Type of oil	Gender	Age	Other details	Motivation
1	Prosperi-Porta et al. (2020)	Synthol	Male (n = 1)	32	amateur bodybuilder	Muscle enhancement – is unclear whether used to significantly enlarge muscles.
2	Parkhurst et al. (2020)	Synthol	Male(n = 1)	30	History of mental health issues	Muscle enhancement – is unclear whether used to significantly enlarge muscles.
3	Sharobaro et al. (2019)	Synthol	Male (n = 3)	unspecified	unspecified	Muscle enhancement – large volumes of oil used to achieve significantly enlarged muscles.
4	Öcal et al. (2019)	Synthol	Male (n = 1)	40	bodybuilder (not specified whether professional or amateur)	Muscle enhancement – large volumes of oil used to achieve significantly enlarged muscles.
5	AlShaqsi et al. (2018)	Synthol	Male (n = 5)	40–45	amateur bodybuilder	Muscle enhancement – large volumes of oil used to achieve significantly enlarged muscles.
6	Koldkjær Sølling et al. (2018)	Paraffin	Male (n = 12)	29–40	former bodybuilders (not specified whether professional or amateur)	Muscle enhancement – is unclear whether used to significantly enlarge muscles.
7	Nerild et al. (2018)	Synthol	Male (n = 1)	39	former competitive bodybuilder	Muscle enhancement – large volumes of oil used to achieve significantly enlarged muscles.
8	Elfituri et al. (2017)	Synthol	Male (n = 1)	44	bodybuilder (not specified whether professional or amateur)	Muscle enhancement – does not appear to be in order to achieve significantly enlarged muscles (small volumes injected – 20 ml)
9	Leary et al. (2017)	Synthol	Male (n = 1)	33	former bodybuilder (not specified whether professional or amateur)	Muscle enhancement – is unclear whether used to significantly enlarge muscles. However, use deemed “excessive” use by medical professionals.
10	Chiri et al. (2017)	Synthol and paraffin	Male (n = 1)	30	unspecified	Muscle enhancement – is unclear whether used to significantly enlarge muscles.
11	Juel et al. (2017)	Paraffin	Male (n = 1)	33	former bodybuilder (not specified whether professional or amateur)	Muscle enhancement – is unclear whether used to significantly enlarge muscles.
12	Dejanović and Loft (2017)	Synthol	Male (n = 1)	50	unspecified	Muscle enhancement- unclear whether large volumes were used or not – specified use was in extremities which indicates particular muscle heads or peaks indicating potential conservative use.
13	Pasgaard, Thi Huynh & Gjedsted (2016)	Paraffin	Male (n = 1)	30	unspecified	Muscle enhancement – large volumes of oil used to achieve significantly enlarged muscles.
14	Hall et al. (2016)	Synthol	Male (n = 17)	unspecified	bodybuilders (not specified whether professional or amateur -- typically a mix of both in online bodybuilding forums (see Brennan, Wells, & Van Hout, 2019)	Muscle enhancement- individuals reported seeking a natural look, but authors noted that this may appear “freakish” to others.
15	Petersen et al. (2015)	Synthol	Male (n = 1)	42	former competitive bodybuilder.	Muscle enhancement – does not appear to be in order to achieve significantly enlarged muscles.
16	Hjort et al. (2015)	Mineral Oil	Male (n = 1)	40	amateur bodybuilder	Muscle enhancement – does not appear to be in order to achieve significantly enlarged muscles.
17	Gyldenløve et al. (2014).	Paraffin oil	Male (n = 1)	23	bodybuilder (not specified whether amateur or professional)	Muscle enhancement – is unclear whether used to significantly enlarge muscles.
18	Figueiredo and Da Silva (2014)	A range of muscle fillers are described, with a focus on “Synthol”	Varied	Unspecified	bodybuilders (professional and amateur)	Muscle enhancement both conservative and extreme with large volumes used.
19	Abdull-Gaffar (2014)	Silicone Vaseline Paraffin oil Unidentified material	Male (n = 4) (4 of 9 cases had injected oils or other materials, the other 5 had injected AAS/corticosteroids)	20 - 39 years	bodybuilders (not specified whether amateur or professional)	Muscle enhancement – is unclear whether used to significantly enlarge muscles. Buttock enhancement. Penis enlargement.

Table 4 (Continued)

No.	Study	Type of oil	Gender	Age	Other details	Motivation
20	Schafer et al. (2011).	Paraffin	Male (n = 1)	26	bodybuilders (not specified whether amateur or professional)	Muscle enhancement – is unclear whether used to significantly enlarge muscles.
21	Figueiredo et al. (2011)	ADE – otherwise known as “Synthol”	Varied	Unspecified	bodybuilders (not specified whether amateur or professional)	Muscle enhancement – is unclear whether used to significantly enlarge muscle. Buttock enhancement. Penis enlargement.
22	Henriksen et al. (2010).	Paraffin	Male (n = 1)	24	bodybuilder (not specified whether amateur or professional)	Muscle enhancement – large volumes of oil used to achieve significantly enlarged muscles.
23	Pupka et al. (2009) *	Synthol	Male (generally discussed)	Unspecified	bodybuilders (not specified whether amateur or professional)	Muscle enhancement both conservative and extreme with large volumes used.
24	Iversen et al. (2009)	Paraffin	Male (n = 1)	24	bodybuilder (not specified whether amateur or professional)	Muscle enhancement – large volumes of oil used to achieve significantly enlarged muscles.
25	Darsow et al. (2000)	Sesame seed oil	Male (n = 1)	48	bodybuilder (not specified whether amateur or professional)	Muscle enhancement – large volumes of oil used to achieve significantly enlarged muscles.
26	Banke et al. (2012)	Sesame seed oil	Male (n=1)	40	semi professional bodybuilder	Muscle enhancement – large volumes of oil used to achieve significantly enlarged muscles.
27	Ikander et al. (2015a)	Synthol and Paraffin	Male (n = 1)	45	bodybuilder	Muscle enhancement – large volumes of oil used to achieve significantly enlarged muscles.
	Ikander et al. (2015a)	Paraffin	Male (n = 1)	31	unspecified	Pectoralis and triceps (volume 150-200 ml)
	Ikander et al. (2015a)	Paraffin	Male (n = 1)	38	unspecified	Biceps and triceps (volume 360 ml)
	Ikander et al. (2015a)	Paraffin	Male (n = 2)	21	unspecified	Biceps and triceps (Volume 400 ml)
	Ikander et al. (2015a)	Synthol	Male (n = 1)	25	unspecified	Triceps (Volume 500 ml)
28	Munch and Hvolris (2001)	Walnut oil	Male (n = 1)	26	Bodybuilder	Intramuscular injections (Self-injection of the walnut oil 3*10 ml oil in biceps, triceps and shoulder blades muscles every fourth day for a couple of months)
1	Ahmed et al. (2017)	Baby oil	Male (n = 1)	61	unspecified	Penis enlargement
	Ahmed et al. (2017)	Silicone	Male (n = 2)	35, 41	unspecified	Penis enlargement
	Ahmed et al. (2017)	Mechanical oil	Male (n = 1)	47	unspecified	Penis enlargement
2	Chon et al. (2017)	Paraffin	Male (n = 1)	64	unspecified	Penis enlargement
3	Cormio et al. (2014).	Paraffin	Male (n = 1)	35	unspecified	Penis enlargement

Table 4 (Continued)

No.	Study	Type of oil	Gender	Age	Other details	Motivation
4	De Siati et al. (2013)	Paraffin	Male (n = 1)	27	unspecified	Penis enlargement
5	Rosenburg et al. (2007)	Paraffin	Male (n = 3)	38, 28, 35	Thai "foreign workers"	Penis enlargement.
6	Eandi et al. (2007)	Unidentified material	Male (n = 1)	71	unspecified	Penis enlargement.
7	Cohen et al. (2002)	Mineral oil	Male (n = 1)	64	unspecified	Penis enlargement
8	Kalsi et al. (2002)	Unspecified material	Male (n = 1)	31	unspecified	Penis enlargement.
9	Hohaus et al. (2003).	Mineral oil - specified as vaseline in the abstract	Male (n = 1)	30	Unspecified	Penis enlargement
10	Bhagat et al. (1995).	Olive oil	Male (n = 1)	48	unspecified	Enlargement of genitals (olive oil injected into the scotum every 15 days for 3 years)
1	Sharobaro et al. (2019)	Vaseline	Female (n = 3)	unspecified	unspecified	Breast enlargement
2	Agac et al. (2017)	Baby oil	Female (n = 1)	46	unspecified	Breast enlargement
3	El Muayed et al. (2010)	Baby oil	Transgender female (n = 1)	58	transgender	Breast enlargement.
4	Peters and Fornasier (2009)	PAH - an extensively cross-linked polymeric soft tissue filler	Female (n = 1)	29	Computer programmer	Breast enlargement.
1	Yeo et al. (2013)	Paraffin Silicone Unidentified materials	Female (n = 17)	n/a (abstract only available in English)	Unspecified	Hand rejuvenation.
2	Ozden et al. (2010)	Baby oil	Female (n = 1)	53	unspecified	Hand rejuvenation.
1	Lym et al. (2015)	An unknown material	Female (n = 1)	47	Unknown	Patient reported "a muscle strengthening oil" injected into the calves, which indicates calf muscle enhancement.
1	Lym et al. (2015) Schafer et al. (2012)	Silicone Turpentine oil (all other cases were in relation to AAS)	Female (n = 1) Female (n = 1)	59 22	Silicone Psychiatric Patient	Thigh augmentation. Unspecified
2	Di Benedetto et al. (2002)	Paraffin	Varied	Varied	Unspecified	Varied

3. Results

3.1. Profile of studies reviewed

Forty four records were included in this this scoping review and are comprised of thirty four clinical case/case series reports, one qualitative online study, one conference presentation, four narrative literature reviews, one retrospective review of clinical case presentations, a report, a clinical study and a letter to the editor (see Table 3). The findings from these will be presented here under headings which directly relate to the research question: *What do we know about self-injection of body filler for aesthetic purposes?* These are: indicative profile of people who inject body fillers; motivation for use across types of oil injection; sourcing routes and documented harms.

3.2. Theme 1: Indicative profiling of individuals who self-inject body fillers

Details which could be used to inform an indicative profile of individuals who inject were sporadically described in the literature and differed across the site of injection (see Table 3).

3.2.1. Muscle enhancement in males

Of the forty four studies included in this review, twenty eight described self- injection of oil or other materials for muscle enhancement in males. Sixteen studies identified individuals as current or former bodybuilders, with no clarification given on whether these were competitive or amateur bodybuilders (Abdull-Gaffar, 2014; Darsow, Bruckbauer, Worret, Hofmann, & Ring, 2000; Elfituri, Akkineni, Bebars, & Heller, 2017; Figueiredo et al., 2011; Gyldenløve et al., 2014; Hall et al., 2016; Henriksen, Lovengald, & Matzen, 2010; Ikander et al., 2015a; Iversen, Lemcke, Bitsch, & Karlsmark, 2009; Juel et al., 2017; Koldkjær Sølling et al., 2018; Leary, Smith, & Kent, 2017; Munch & Hvolris, 2001; Öcal et al., 2019; Pupka, Sikora, Mauricz, Cios, & Płonek, 2009; Schafer et al., 2011). One review discussed both competitive and amateur bodybuilders (Figueiredo & Da Silva, 2014). Four clinical case reports identified individuals as amateur bodybuilders (Banke et al., 2012) AlShaqsí, Qader Ali, & Albulushi, 2018; Koldkjær Sølling et al., 2018; Prosperí-Porta, Oleynick, & Vaughan, 2020). One clinical case report described the individual as a former competitive bodybuilder (Petersen, Colville-Ebeling, Jensen, & Hougen, 2015). One conference presentation on a clinical case report described the individual as having a history of mental health issues (Parkhurst, Weir, Rajwani, & Narula, 2020). Such descriptions of individuals were absent in five studies (Chiri, Gabriel, Chelala, & Azar, 2017; Dejanović & Loft, 2017; Nerild, Theilade, & Eldrup, 2018; Pasgaard, Thi Huynh, & Gjedsted, 2016; Sharobaro, Manturova, Ivanov, & Avdeev, 2019). The age range of these individuals across twenty five studies was between 21-50 years old.

3.2.2. Genital enhancement in males

Ten clinical case reports described self-injection of oils into the genitals for enlargement, typically specified as penile girth augmentation (Ahmed et al., 2017; Chon et al., 2017; Cohen et al., 2002; Cormio et al., 2014; De Siati et al., 2013; Eandi, Yao, & Javidan, 2007; Hohaus, Bley, Kostler, Schonlebe, & Wollina, 2003; Kalsi, Arya, Peters, Minhas, & Ralph, 2002; Rosenburg, Romanowsky, Asali, & Kaneti, 2007) with one case describing injection into the scrotum (Bhagat, Holmes, Kulaga, Murphy, & Cockcroft, 1995) Penis enlargement was also described in a case series of different types of self-injection of oils (Abdull-Gaffar, 2014). The age range of these individuals across these ten studies was between 26-71 years old. One study provided additional descriptive information on the individual Rosenburg et al. (2007) who indicated the cases were “Thai

foreign workers”. In one case the individual was described as having mental health issues (Bhagat et al., 1995).

3.2.3. Breast enhancement in females

Four clinical case reports described self-injection of oils into the breast area for enlargement purposes (Agac et al., 2017; El Muayed, Costas, & Pick, 2010; Peters & Fornasier, 2009; Sharobaro et al., 2019) (which also described muscle enhancement in males above). The age range of these individuals across four studies was between 29 and 58 years old. One case was a transgender female (El Muayed et al., 2010).

3.2.4. Hand rejuvenation in females

Two clinical case reports described self-injection of oils into the hand for rejuvenation purposes (Ozden, Arinci, Aydin, & Buyukbabani, 2010; Yeo, Park, & Chang, 2013). No age range was given for one study, which reviewed 17 cases (Yeo et al., 2013) and the other study stated that the individual was 58 years old (Ozden et al., 2010).

3.2.5. Other

One study (Lym et al., 2015) which reported on two clinical case presentations, described one case of oil injection into the calves, and a second case of silicone injection into the thighs for augmentation purposes. The individuals were 47 and 59 years old respectively. Schafer et al. (2012) included as part of their review paper a case of turpentine injection in a 22 year old female, described as a psychiatric patient, for unspecified purposes. Di Benedetto et al. (2002) described the practice of paraffin oil injection more generally, without providing specifics of individuals who self-inject. One case of paraffin injection into the knee described a 90 year old man who had injected decades previously to avoid military service (Catalano, Dal Pozzo, & Grifi, 2003).

3.3. Theme 2: Motivation for use across types of oil injection

3.3.1. Muscle enhancement in males

Of the twentyseven studies which described self-injection of oil for muscle enhancement, “Synthol” was named in sixteen studies (AlShaqsí et al., 2018; Chiri et al., 2017; Dejanović & Loft, 2017; Elfituri et al., 2017; Figueiredo & Da Silva, 2014; Figueiredo et al., 2011; Hall et al., 2016; Ikander et al., 2015a; Leary et al., 2017; Nerild et al., 2018; Öcal et al., 2019; Parkhurst et al., 2020; Petersen et al., 2015; Prosperí-Porta et al., 2020; Pupka et al., 2009; Sharobaro et al., 2019). Paraffin oil was named in ten studies (Abdull-Gaffar, 2014; Chiri et al., 2017; Gyldenløve et al., 2014; Henriksen et al., 2010; Iversen et al., 2009; Ikander et al., 2015a; Juel et al., 2017; Koldkjær Sølling et al., 2018; Pasgaard et al., 2016; Schafer et al., 2011), sesame seed oil in two studies (Banke et al., 2012; Darsow et al., 2000), mineral oil in one study (Hjort, Hoegberg, Almind, & Jansen, 2015) and walnut oil in one study (Munch & Hvolris, 2001). Of the individual cases discussed in these studies, a majority of thirteen cases were documented as self-injecting large volumes of oil in order to create grossly exaggerated muscles (AlShaqsí et al., 2018; Darsow et al., 2000; Figueiredo et al., 2011; Henriksen et al., 2010; Iversen et al., 2009; Öcal et al., 2019; Pasgaard et al., 2016; Sharobaro et al., 2019). In twelve individual cases it was unclear whether large volumes were used or a more conservative look was sought after (Abdull-Gaffar, 2014; Chiri et al., 2017; Figueiredo et al., 2011; Gyldenløve et al., 2014; Ikander et al., 2015a; Juel et al., 2017; Koldkjær Sølling et al., 2018; Leary et al., 2017; Nerild et al., 2018; Parkhurst et al., 2020; Prosperí-Porta et al., 2020; Schafer et al., 2011). However, one of these studies reported that use was deemed “excessive” by medical professionals (Leary et al., 2017). In a minority of four cases, conservative use of oil was described, to enhance particular

muscle “peaks” (Dejanović & Loft, 2017; Elfituri et al., 2017; Hjort et al., 2015; Petersen et al., 2015), while Munch and Hvolris (2001) reported on small volumes of walnut oil systematically used every few days for months. Figueiredo et al. (2011) also discussed conservative use in general. Of interest is that in a qualitative online study which examined the views and experiences of males who self-inject, many reported seeking a natural look, whereby the authors acknowledged that this look may appear “freakish” to others (Hall et al., 2016). Indications of mental health issues or body image disorder as motivators to self-inject body fillers were seen in Nerild et al. (2018) and Parkhurst et al. (2020).

3.3.2. Genital enhancement in males

Across ten studies that described genital enlargement through self-injection of oils (Abdull-Gaffar, 2014; Ahmed et al., 2017; Bhagat et al., 1995; Chon et al., 2017; Cohen et al., 2002; Cormio et al., 2014; De Siati et al., 2013; Eandi et al., 2007; Hohaus et al., 2003; Kalsi et al., 2002; Rosenburg et al., 2007), thirteen individual cases were identified. The most common oil used was paraffin, with four cases identified (Chon et al., 2017; Cormio et al., 2014; De Siati et al., 2013; Rosenburg et al., 2007). In one study, two cases self-injected silicone, one case self-injected baby oil and one case self-injected mechanical oil (Ahmed et al., 2017). Mineral oil was named as the injected substance in two cases (Cohen et al., 2002; Hohaus et al., 2003) and olive oil (Bhagat et al., 1995). Unidentified materials were injected into the penis in two cases (Eandi et al., 2007; Kalsi et al., 2002). Motivation for use, where described, was generally for penile girth augmentation. In one case genital augmentation was described as the outcome of a psychosexual disorder (Bhagat et al., 1995).

3.3.3. Breast enhancement in females

Within four clinical case reports (Agac et al., 2017; El Muayed et al., 2010; Peters & Fornasier, 2009; Sharobar et al., 2019), six individual cases of self-injection of oils into the breast area for enlargement purposes were described. Three cases of self-injection of vaseline were identified (Sharobar et al., 2019), two case where baby oil was used (Agac et al., 2017; El Muayed et al., 2010) and one case where PAH, an extensively cross-linked polymeric soft tissue filler, was named as the injected substance. One case was a transgender female (El Muayed et al., 2010) whose motivation for breast enlargement was part of the transitioning process.

3.3.4. Hand rejuvenation in females

Two clinical case reports described self-injection of oils into the hand for rejuvenation purposes i.e. to combat the signs of aging (Ozden et al., 2010; Yeo et al., 2013). Within these, eighteen individual cases were identified. A range of oils were used to include: paraffin; silicone; baby oil and an unidentified material. One case reported that she had always been unhappy with the ‘wasted’ appearance of her hands (Ozden et al., 2010).

3.3.5. Other

One study (Lym et al., 2015), which reported on two clinical case presentations, described one case of oil injection into the calves which the case reported as being “for strengthening purposes”. A second case of silicone injection into the thighs was attributed to an attempt at cosmetic augmentation. Schafer et al. (2012) included as part of their review paper a case of turpentine injection in a 22 year old female for unspecified purposes, and reported that this female was a psychiatric patient. One unusual case of paraffin injection into the knee described a 90 year old man who had self-injected decades previously to purposefully injure himself in order to avoid military service (Catalano et al., 2003).

3.4. Theme 3: Sourcing routes

Information on sourcing routes of oils and other materials for self-injection was scant in the literature reviewed. One clinical study which analysed performance and image enhancement drugs purchased online in order to verify their contents found that of sixteen products analysed where no active substance was detected, oils for injection labelled and marketed as “synthol” were discovered (Odoardi et al., 2020). Further cases of sourcing oils online were described in Ikander et al. (2015a); Munch and Hvolris (2001) and Abdull-Gaffar (2014). In Agac et al. (2017) a female reported finding the baby oil she had injected in her breasts “at home”. Two individuals (Chon et al., 2017; Pasgaard et al., 2016) had transitioned from having paraffin oil injections performed by others (non-medical personnel) to self-injection. Other sourcing routes were described in Abdull-Gaffar (2014) as being through gym trainers; friends and illegal prescriptions, with some oils and materials (i.e. vaseline and plant oils) being freely available in the local market. One case sourced oil for penile injection from a grease gun, which he also used to inject it (Kalsi et al., 2002).

3.5. Theme 4: Documented Harms

3.5.1. Muscle enhancement in males

A number of harms were documented in males who self-injected oils for muscle enhancement. These included paraffinomas and paraesthesia (Juel et al., 2017) bilateral upper-arm erythema, pain and swelling, irritation and flushing, ulcerations and chronic wounds (Ikander et al., 2015a, 2015b; Iversen et al., 2009; Banke et al., 2012), large ulcers (Henriksen et al., 2010), plaque-like, multinodular heterogeneous tissue, fibrosis, chronic lymphocytic infiltrate and multinucleated foreign-body giant cell reaction (Prosperi-Porta et al., 2020). Migration of filler, oleogranulomas (cyst of different sizes) (Darsow et al., 2000; Dejanović & Loft, 2017), widespread inflammation and tissue contour definition was also reported (AlShaqqi et al., 2018; Sharobar et al., 2019). Pain in areas of the body other than the site of injection were also documented. In one case, a male suffered extreme wrist pain and limited wrist mobility after self-injecting in the bicep region (Leary et al., 2017) and in another, a male presented with scrotal pain after injections in the chest, arms and back (Gyldenløve et al., 2014). Accidental intravascular injections were also reported causing acute onset respiratory distress (Hjort et al., 2015; Pasgaard et al., 2016). Chest pain and forms of pneumonia were documented in two studies (Elfituri et al., 2017; Öcal et al., 2019) and acute lung injury (Prosperi-Porta et al., 2020). Severe hypercalcemia was reported in four studies (Gyldenløve et al., 2014; Koldkjær Sølling et al., 2018; Nerild et al., 2018; Schafer et al., 2011). Many health harms appeared years after self-injection, most notably in the case of a classic sclerosing lipogranuloma-type reaction which occurred twenty years after a self-injection of “Synthol” (Petersen et al., 2015).

3.5.2. Genital enhancement in males

Penile pain, voiding dysfunction and sexual dysfunction were the most common health harms documented in the reviewed literature on self-injection of fillers in the penis (Chon et al., 2017; Cormio et al., 2014; De Siati et al., 2013; Eandi et al., 2007; Kalsi et al., 2002; Rosenburg et al., 2007). Oedema, nodules and granulomas were also reported (Ahmed et al., 2017; Hohaus et al., 2003; Kalsi et al., 2002) as well as irregular penile mass and deformity (Cormio et al., 2014; Eandi et al., 2007). In one case, symptoms did not become problematic until five years after self-injection (De Siati et al., 2013) and in another, a seventy one year old man presented with severe deformity forty years after self-injection (Eandi et al., 2007). One case had respiratory failure and was found to have

lipogranulomatous lesions in the lung and scrotum (Bhagat et al., 1995).

3.5.3. Breast enhancement in females

One death due to granulomatous mastitis (paraffinoma)-related hypercalcemia and renal failure was reported in 2010 in a patient (El Muayed et al., 2010). This is consistent with historic accounts of deaths in the 1950s and 60s associated with breast augmentation through self-injection of oils in a report included in this review (Peters & Fornasier, 2009). Other documented health harms include clerosing adenosis and foreign body granulation tissue, pain, and impaired movement (Agac et al., 2017).

3.5.4. Hand rejuvenation in females

In females who injected oils into their hands, foreign body granulomas, palpable mass and contour deformity are documented (Yeo et al., 2013). Additionally, an acute attack of anaphylactic symptoms with massive swelling at the injection sites, which yielded to hard, inflammatory lumps was documented in one female (Ozden et al., 2010).

3.5.5. Other

Pain and hyperpigmented plaques were found in a female who injected an unidentified oil into her calf muscles and painful nodules discovered in a female who self-injected silicone into her thighs (Lym et al., 2015). In the case of an elderly man who had injected paraffin into his knee decades before, he was unable to walk due to knee pain (Catalano et al., 2003).

4. Discussion

The aim of the scoping review was to compile what is known on the self-injection of oils and other materials for enhancement of the body, in order to yield a contemporary understanding of indicative groups who self-inject; motivators for self-injection of oils, sourcing routes and harms. Although the sample population reviewed are heterogenous in nature, a common driver for engagement in body enhancement through oil injection is to achieve a subjective body ideal.

In conducting this review, we aimed to further discussion on the practice of self-injection of oil for body enhancement, at a time when DIY cosmetic enhancement appears to be increasingly documented (Brennan et al., 2018; Thomas et al., 2020; Torre et al., 2019). Self-injection of body fillers is of particular interest for several reasons. Firstly, although, it is situated in bodywork culture it has attracted stigmatisation within distinct groups of people who practice bodywork (Hall et al., 2016; Salinas et al., 2019). This may be in part due to its sometimes perceived outlandish outcomes in terms of physical appearance and health, and due to its association with subcultural or marginalised groups e.g. transgender communities (Figueiredo & Da Silva, 2014; Hage et al., 2001; Restrepo et al., 2009; Wilson et al., 2014). Secondly, knowledge and understanding of oil injection as a cosmetic phenomenon remains scant. Finally, there is a need for increased awareness of the implications of injection of body fillers with regard to, potential harms as well as treatment options, their shortcomings and opportunities in relation to health side-effects.

Perhaps unsurprisingly, the reviewed literature found that self-injection of oils is seen most commonly in males seeking to enhance muscle size. Noteworthy is that in the majority of cases, large volumes of oil are injected to create grossly enlarged muscles. This practice has a longstanding association with fast tracking or 'cheating' to achieve a physique that bodybuilders perceive warrants investing a great deal of time, energy and work (Hall et al., 2016; Salinas et al., 2019). Due to this stigma, many males initially deny that they have self-injected oils when they present for

medical attention (Abdull-Gaffar, 2014). This reluctance to admit engagement in self-injection is also seen in males who present with complications due to penile augmentation with oils or fillers (Cohen et al., 2002) and can also delay the individual in making contact with medical services until deformity or dysfunction has reached an untenable level (Ahmed et al., 2017). Though external stigma is evidently absorbed and is consequential for individuals who self-inject body fillers, intrinsic motivation to continue this practice remains. Indeed, many individuals refuse to have the material fully excised when requiring surgery to excise the foreign body material (Ozden et al., 2010). Moreover, studies suggest that many individuals who self inject struggled to engage with healthcare service e.g. nonattendance at blood tests or other checks (Ikander et al., 2015a, 2015b online response to Gyldenløve & Hansen, 2015; Munch & Hvolris, 2001).

While the majority of individuals referred to in the reviewed studies appeared to go to what convention considers 'extreme lengths' to achieve their body ideals, internalized body ideals and self-comparison to those ideals contributes to a variety of harmful behaviours. According to Festinger (1954) this can extend to self-injury. DIY cosmetic surgery has been previously conceptualised as self-harm in the literature (Phillips & Menard, 2006), particularly where the outcomes impede healthy life functioning, for example where males were unable to fully urinate or engage in sex due to penile self-injection (Chon et al., 2017; Cormio et al., 2014; De Sisti et al., 2013; Eandi et al., 2007; Kalsi et al., 2002; Rosenberg et al., 2007). There were indications of psychiatric disorder in the studies reviewed (Nerild et al., 2018; Parkhurst et al., 2020; Schafer et al., 2012). Severe body image dissatisfaction is a feature of many formally recognized psychiatric disorders. These are likely to be observed among individuals who engage in body contouring procedures (Sarwer & Polonsky, 2016). Gender dysphoria may lead to injection of body fillers in the transgender community (Hage et al., 2001; Restrepo et al., 2009; Wilson et al., 2014). In this review, we refer to one case of self-injection in a transgender female (El Muayed et al., 2010) which ultimately led to the death of the individual concerned. Lack of access to specialised care (and long waiting lists) were attributed to the practice of "self-transitioning" in the literature (Metastasio, Negri, Martinotti, & Corazza, 2018), where the authors documented transgender individuals sourcing unregulated hormones online. These individuals were also receiving psychiatric care (Metastasio et al., 2018). Transgender individuals who cannot access proper medical care in order to transition may be at risk of self-injection of body fillers and the significantly deleterious harms to health involved in such practices.

Self-injection of body fillers may also be a new type of 'display work' (Mears & Connell, 2016). 'Display work' is a form of bodily capital (Wacquant, 2004), where individuals perform paid or unpaid work on their bodies as investment, such as engagement in fitness regimes, or cosmetic enhancement for sex work. It may also be for the purpose of visual consumption, to please others or to please the self. 'Display workers' expend significant energy on their appearance (Gimlin, 2002) for the reward of exhibitionism and external approval. It also involves regulation of emotionality enmeshed in body image (Entwistle & Wissinger, 2006). 'Display work' may be a performance of gender ideals, eroticism or beauty. The contemporary social media landscape includes unrealistic body types (Hopkins et al., 2020) and includes 'photoshopping' and digital alterations of images to promote 'simulacra' of ideal bodies, which are fluid and dictated by celebrity and popular cultural trends (Alkarzae et al., 2020; Barker, 2020; Butkowski et al., 2019). As such, we are positioned as social media consumers to become 'aesthetic labourers' in projecting the image, personality and energy which is likely to be embraced by an external audience. Vulnerable individuals engaging in 'display work' may be at risk of

taking dangerous action to build cultural capital within this sphere, including self-injection of oil or fillers to contour the body.

Of concern is that the documented harms associated with self-injection of unlicensed oils and fillers are plentiful and the medical responses available to healthcare practitioners are few. In one case we reviewed, where poison control were called for advice on how to treat an individual with chest pain and a form of pneumonia, no recommendations could be made to medical professionals due to lack of data on this particular practice (Elfituri et al., 2017). Presently, the medical response is restricted to the administration of corticosteroids (Juel et al., 2017), antibiotics, compression bandages (Schafer et al., 2011) and the option of surgery to excise the foreign body material, which as already stated, some individuals refuse (Ozden et al., 2010) or are hesitant about (Ikander et al., 2015a, 2015b). Long periods of time may pass before an individual presents for medical care. Stigmatisation around use might prevent some individuals from seeking treatment or delay this process. The time delay, however, makes treatment more difficult, and reduces the likelihood of a successful outcome.

Increased public awareness around the potentially devastating effects of self-injection of body fillers is needed, particular in the current climate of body enhancement and indications of increasing DIY procedures. Positive body image campaigns centred on the promotion of health and diversity are warranted. As scant details around motivations for self-injection and sourcing routes were found in this scoping review of extant literature, clinicians should nonetheless be made aware of the importance of building an evidence base on this relatively rare, but potentially increasing and dangerous practice. There is a gap in the literature pertaining to qualitative investigation with individuals who inject oils and body fillers to document their views, experiences and cognitive processes, including those who inject moderately. Future research should focus on the impact of social media discourse on DIY cosmetic procedures and the role of mental and emotional health in decision making processes in the self-injection of unlicensed materials for body enhancement, as well as the development of targeted interventions to reduce harm in individuals who practice DIY body filler injection.

5. Conclusion

People who inject body fillers are a heterogeneous group, who are motivated to inject for different reasons and who inject a range of oils and materials. This research aimed to collate what is known on profiles of individuals who self-inject; motivators for self-injection of oils; sourcing routes and harms. It was found that the majority of people who inject body fillers are male and do so to grossly increase muscle size. Injection of oils and other materials in the male genitalia was also described, in addition to female self-injection in the breast, hand and leg areas for augmentation. A range of health consequences were reviewed, including one death of a transgender woman. Recommendations are made for further research into this unique phenomenon, which although is relatively rare, warrants future research attention considering the documented increase in DIY facial fillers and contemporary body image culture, supported by unrealistic social media discourse. Public awareness campaigns centred on the promotion of positive body image, the potentially devastating harms associated with DIY body fillers and enhanced clinical reporting to build an evidence base for effective interventions, training of clinicians and healthcare responses are recommended.

Funding Sources

None

Declaration of Competing Interest

The authors declare no conflict of interest.

Acknowledgements

None

References

- Abdull-Gaffar, B. (2014). Illicit Injections in Bodybuilders: A Clinicopathological Study of 11 Cases in 9 Patients with a Spectrum of Histological Reaction Patterns. *International Journal of Surgical Pathology*, 22(8), 688–694.
- Agac, A., Akturan, S., Guclu, T. H., Alyanak, A., Gobut, H., & Gulten, K. (2017). The First Reported Case of Breast Granulomas Secondary to Huge Amount of Baby Oil Self-injection. *International Biological and Biomedical Journal*, 3(1), 44–46.
- Ahmed, U., Freeman, A., Kirkham, A., Ralph, D. J., Minhas, S., & Muneer. (2017). Self-injection of foreign materials into the penis. *Annals of the Royal College of Surgeons of England*, 99(2), 78–82.
- Alkarzae, M., Aldosari, B., Alalula, L., Almuhaaya, R., & Alawadh, I. (2020). The Effect of Selfies on Cosmetic Surgery. *ENT Updates*, 10(1), 251–260.
- Alshaqsi, S., A Qader Ali, M., & Albulushi, T. (2018). "Fake Popeye Muscles" - Soft Tissue Granulomas Secondary to Intramuscular Synthetic Oil Injections in Bodybuilding. Case Series and a Literature Review. *Orthopaedics and Sports Medicine*, 1(4), 72–75.
- Arksey, H., & O'Malley, L. (2005). Scoping studies: towards a methodological framework. *International Journal of Social Research Methodology*, 8(1), 19–32.
- Azevedo, M., & Ferreira, A. (2009). Oils of ILocal application inside of the muscle: epidemiology of the use in bodybuilding. *Revista Brasileira de Ciência e Movimento*, 17, 45–53.
- Bhagat, R., Holmes, I. H., Kulaga, A., Murphy, F., & Cockcroft, D. W. (1995). Self-injection With Olive Oil: A Cause of Lipoid Pneumonia. *Chest*, 107(3), 875–876.
- Banke, I. J., Proding, P. M., Walldt, S., Weirich, G., Holzapfel, B. M., Grading, R., et al. (2012). Irreversible muscle damage in bodybuilding due to long-term intramuscular oil injection. *International Journal of Sports Medicine*, 33(10), 829–834.
- Barker, J. (2020). Making-up on mobile: the pretty filters and ugly implications of Snapchat. *Fashion, Style and Popular Culture*, 7(2–3), 207–221.
- Brandt, S. D., King, L. A., & Evans-Brown, M. (2014). The new drug phenomenon. *Drug Testing and Analysis*, 6(7–8), 587–597.
- Brennan, B. P., Kanayama, G., & Pope, H. G. (2013). Performance-Enhancing Drugs on the Web: A Growing Public-Health Issue. *American Journal on Addictions*, 22(2), 158–161.
- Brennan, R., Van Hout, M. C., & Wells, J. (2013). Heuristics of human enhancement risk: a little chemical help? *International Journal of Health Promotion and Education*, 51(4), 212–227.
- Brennan, R., Wells, J. G., & Van Hout, M. C. (2019). Beauty through the eye of the needle: An online study of the injecting practices and beliefs of people who inject performance and image enhancing drugs (PIED). In Katinka Van de Ven, J. McVeigh, & K. Mulrooney (Eds.), *Human Enhancement Drugs*. London: Routledge.
- Brennan, R., Wells, J. G., & Van Hout, M. C. (2018). Saving Face" - an online study of the injecting use of DIY Botox and dermal filler kits. *Plastic Surgery*, 26(3), 154–159.
- Brennan, R. (2018). *An Ethnopharmacological Study of The Injecting Use of Performance and Image Enhancing Drugs (PIED) (Volumes I & II)* Waterford Institute of Technology. Doctoral thesis.
- Butkowski, C. P., Dixon, T. L., & Weeks, K. (2019). Body Surveillance on Instagram: Examining the role of selfie feedback investment in young adult women's body image concerns. *Sex Roles*, 81, 385–397.
- Carella, S., Romanzi, A., Ciotti, M., & Giuseppina Onesti, M. (2013). Skin Ulcer: A Long-Term Complication after Massive Liquid Silicone Oil Infiltration. *Aesthetic Plastic Surgery*, 37, 1220–1224.
- Catalano, O. A., Dal Pozzo, F., & Grifi, D. N. (2003). Paraffinoma of the knee. *Skeletal Radiology*, 32, 485, 8.
- Chiri, R., Gabriel, K., Chelala, D., & Azar, H. (2017). Hypercalcemia and Nephrocalcinosis induced by pump and poseinjection. *Nephrology Dialysis Transplantation*, 32(3), 434.
- Chon, W., Yun Koo, J., Jung Park, M., Choi, K., Park, H., & Park, N. (2017). Paraffin Granuloma Associated with Buried Glans Penis-Induced Sexual and Voiding Dysfunction. *World Journal of Men's Health*, 35(2), 129–132.
- Cohen, J. L., Keoleian, C. M., & Krull, E. A. (2002). Penile paraffinoma: Self-injection with mineral oil. *Journal of the American Academy of Dermatology*, 47, 251–253.
- Cormio, L., Di Fino, G., Scavone, C., Selvaggio, O., Massenio, P., Sanguedolce, F., et al. (2014). Magnetic resonance imaging of penile paraffinoma: case report. *BMC Medical Imaging*, 14(39), 1–4.
- Crossley, M. (2007). Narrative analysis. In E. Lyons, & A. Coyle (Eds.), *Analysing Qualitative Data in Psychology* (pp. 131–144.). <https://doi.org/10.4135/9781446207536>
- Daudt, H. M. L., van Mossel, C., & Scott, S. J. (2013). Enhancing the scoping study methodology: A large, inter professional team's experience with Arksey and

- O'Malley's framework. *BMC Medical Research Methodology*, 13(1) <https://doi.org/10.1186/1471-2288-13-48>
- Darsow, U., Bruckbauer, H., Worret, W., Hofmann, H., & Ring, J. (2000). Subcutaneous oleomas induced by self-injection of sesame seed oil for muscle augmentation. *Journal of the American Academy of Dermatology*, 42(2), 292–294.
- Dejanović, D., & Loft, A. (2017). CT Findings Following Repeated Intramuscular Injections of "Site Enhancement Oil" in the Upper Extremities. *Clinical Nuclear Medicine*, 42(10), 436–437.
- De Siati, M., Selvaggio, O., Di Fino, G., Luzzi, G., Massenio, P., Sanguedolce, F., et al. (2013). An unusual delayed complication of paraffin self-injection for penile girth augmentation. *BMC Urology*, 13(66), 1–4.
- Di Benedetto, G., Pierangeli, M., Scalise, A., & Bertani, A. (2002). Paraffin oil injection in the body: An obsolete and destructive procedure. *Annals of Plastic Surgery*, 49(4), 391–396.
- Eandi, J., Yao, A. P., & Javidan, J. (2007). Penile paraffinoma: the delayed presentation. *International Urology and Nephrology*, 39, 553–555 (2007).
- El Muayed, M., Costas, A., & Pick, A. J. (2010). 1, 25-dihydroxyvitamin D-mediated hypercalcemia in oleogranulomatous mastitis (paraffinoma), ameliorated by glucocorticoid administration. *Endocrine Practice*, 1(16), 102–107.
- Elfturi, A., Akkineni, S., Bebars, H., & Heller, D. (2017). A Pneumonitis and Acute Hypoxemic Respiratory Failure Following Synthol Intramuscular Injection in A Bodybuilder. *American Journal of Respiratory and Critical Care Medicine*, 195(1), A5563.
- Entwistle, J., & Wissinger, E. (2006). Keeping Up Appearances: Aesthetic Labour and Identity in the Fashion Modelling Industries of London and New York. *Sociological Review*, 54(4), 774–794.
- Festing, L. (1954). A Theory of Social Comparison Processes. *Human Relations*, 7(2), 117–140.
- Figueiredo, V. C., & Da Silva, P. R. P. (2014). Cosmetic Doping—When Anabolic–Androgenic Steroids are not enough. *Substance Use & Misuse*, 49(9), 1163–1167.
- Figueiredo, V. C., da Silva, P. R. P., De Souza, T., & De Rose, E. H. (2011). Cosmetic Doping: the Problems of Intramuscular Application of Oils. *A Revista Brasileira de Medicina do Esporte*, 17(1), 56–61.
- Ghandourah, S., Hofer, M. J., Kießling, A., El-Zayat, B., & Schofer, M. D. (2012). Painful muscle fibrosis following synthol injections in a bodybuilder: a case report. *Journal of Medical Case Reports*, 6, 248. <https://doi.org/10.1186/1752-1947-6-248>
- Gersuny, R. (1980). The classic reprint. Concerning a subcutaneous prosthesis. *Plastic and Reconstructive Surgery*, 65(4), 525–527.
- Glicenstein, J. (2007). The first "fillers", Vaseline and paraffin. From miracle to disaster. *Annales de Chirurgie Plastique Esthétique*, 52(2), 157–161.
- Gimlin, D. (2002). *Body Work: Beauty and Self-Image in American Culture*. Berkeley: University of California Press.
- Debat (response to lkander et al., 2015a). Muskelfremhævende paraffinolieinjektioner. Muskelfremhævende paraffinolieinjektioner kan forårsage svær hyperkalcæmi og systemisk spredning. *Ugeskrift for Læger*, 25, <https://ugeskriftet.dk/debat/muskelfremhævende-paraffinolieinjektioner>.
- Gyldenløve, M., Rørvig, S., Skov, L., & Hansen, D. (2014). Severe hypercalcaemia, nephrocalcinosis, and multiple paraffinomas caused by paraffin oil injections in a young bodybuilder. *The Lancet*, 383(9934), 2098.
- Hall, M., Grogan, S., & Gough, B. (2016). 'Bodybuilders' accounts of synthol use: the construction of lay expertise online. *Journal of Health Psychology*, 21(9), 1939–1948.
- Hopkins, Z. H., Moreno, C., & Secrest, A. M. (2020). Influence of Social Media on Cosmetic Procedure Interest. *Journal of Clinical Aesthetic Dermatology*, 13(1), 28–31.
- Hage, J. J., Kanhai, R. C., Oen, A. L., Van Diest, P. J., & Karim, R. B. (2001). The devastating outcome of massive subcutaneous injection of highly viscous fluids in male to female transsexuals. *Plastic and Reconstructive Surgery*, 107, 734–741.
- Henriksen, T. F., Lovengald, J. B., & Matzen, S. H. (2010). Paraffin oil injection in bodybuilders calls for preventive action. *Ugeskrift Læger*, 172(3), 219–220.
- Hjort, M., Hoegberg, L. C., Almind, M., & Jansen, T. (2015). Subacute fat-embolism-like syndrome following high-volume intramuscular and accidental intravascular injection of mineral oil. *Clinical Toxicology*, 53(4), 230–232.
- Hohaus, K., Bley, B., Kostler, E., Schonlebe, J., & Wollina, U. (2003). Mineral oil granuloma of the penis. *Journal of the European Academy of Dermatology and Venereology*, 17(5), 585–587.
- lkander, P., Nielsen, A. M., & Sørensen, J. A. (2015). Injektion af synthololie hos bodybuilder gav kroniske sår og deformerede ar [Injection of synthol in a bodybuilder can cause chronic wounds and ulceration]. *Ugeskrift for læger*, 177(20)
- lkander P; Nielsen AM; Sørensen JA. Online response to Gyldenløve, M and Hansen, D (2015). Muskelfremhævende paraffinolieinjektioner (response to lkander, Nielsen and Sørensen) in Ugeskrift for Lægers online debate forum <https://ugeskriftet.dk/debat/muskelfremhævende-paraffinolieinjektioner>.
- Iversen, L., Lemcke, A., Bitsch, M., & Karlsmark, T. (2009). Compression Bandage as Treatment for Ulcers Induced by Intramuscular Self-injection of Paraffin Oil. *Acta Dermato-Venereologica*, 89(2), 196–197.
- Kalsi, J. S., Arya, M., Peters, J., Minhas, S., & Ralph, D. J. (2002). Grease-gun injury to the penis. *Journal of the Royal Society of Medicine*, 95, 254.
- Khalil, H., Peters, M., Godfrey, C. M., McInerney, P., Soares, C. B., & Parker, D. (2016). An evidence-based approach to scoping reviews. *Worldviews on Evidence-Based Nursing*, 13(2), 118–123.
- Koldkjær Sølling, A. S., Tougaard, B. G., Harsløf, T., Langdahl, B., Kongsbak Brockstedt, H., Byg, K. E., et al. (2018). Non-parathyroid hypercalcaemia associated with paraffin oil injection in 12 younger male bodybuilders: a case series. *European Journal of Endocrinology*, 178(6), 29–37.
- Juel, J., Vestergaard Greisen, D., & Pareek, M. (2017). Long-term adverse effects of intramuscular oil injection. *British Medical Journal Case Reports*, <https://doi.org/10.1136/bcr-2017-220698>, available at:
- Leary, D., Smith, M. D., & Kent, R. E. (2017). Intramuscular Steroid Injections for the Treatment of Wrist Drop Due to Excessive use of Muscle Enhancement Oil Site Injections: A Case Report. *AAPM&R Annual Assembly Abstracts*, 9(1), 223.
- Levac, D., Colquhoun, H., & O'Brien, K. K. (2010). Scoping studies: advancing the methodology. *Implementation Science*, 5(1), 69. <https://doi.org/10.1186/1748-5908-5-69>
- Lee, T., Choi, H. R., Lee, Y. T., & Lee, Y. H. (1994). Paraffinoma of the penis. *Yonsei Medical Journal*, 35(3), 344–348.
- Lym, C. I., Nakasato, F. K., Menezes, M. C. S., Sodre, C. T., Gomes, M. K., Manela-Azuley, M., et al. (2015). Oleoma treated with oral colchicine: Report of two cases and review of the literature. *International Journal of Women's Dermatology*, 1, 47–50.
- Markopoulos, C., Mantas, D., Kouskos, E., Antonopoulou, Z., Revenas, C., & Yiacoumettis, A. (2006). Paraffinomas of the breast or oleogranulomatous mastitis – a rare entity. *Breast*, 15(4), 540–543.
- Mears, A., & Connell, C. (2016). The Paradoxical Value of Deviant Cases: Toward a Gendered Theory of Display Work. *Journal of Women in Culture and Society*, 41(2), 333–359.
- Metastasio, A., Negri, A., Martinotti, G., & Corazza, O. (2018). Transitioning Bodies. The Case of Self-Prescribing Sexual Hormones in Gender Affirmation in Individuals Attending Psychiatric Services. *Brain Science*, 8(88) <https://doi.org/10.3390/brainsci8050088>, available at:
- Munch, I. C., & Hvorslev, J. J. (2001). Bodybuilding ved hjælp af intramuskulær injektion af valnøddeolie. [Body building aided by intramuscular injections of walnut oil]. *Ugeskrift for læger*, 163(48), 6758.
- Nerild, H. H., Theilade, K. S., & Eldrup, E. (2018). Bigoreksi med paraffinomdannelse kan give hypercalcaemia' [Paraffin oil injections due to bigorexia may cause hypercalcaemia]. *Ugeskrift for læger*, 180(48), V04180256.
- Öcal, N., Gunal, A., Arslan, Y., Kacmaz, B., Coskun, A., Karan, B. C., et al. (2019). Exogenous Lipoid Pneumonia Due To Intramuscular Injection of Synthol in a Bodybuilder. *Medical Journal of Mugla Sıtkı Kocman University*, 6(1), 48–51.
- Odoardi, S., Mestria, S., Biosia, G., Valentini, V., Federici, S., & Rossi, S. S. (2020). An overview on performance and image enhancing drugs (PIEDs) confiscated in Italy in the period 2017–2019. *Clinical Toxicology*, <https://doi.org/10.1080/15563650.2020.1770277>
- Ozden, B., Arinci, A., Aydin, A., & Buyukbabani, N. (2010). Self-rejuvenation of the hand. *The Journal of Hand Surgery*, 35(6), 511–512.
- Pasgaard, T., Huynh, A. T., & Gjedsted, J. (2016). Extracorporeal membrane oxygenation after intravenous injection of paraffin oil. *Perfusion*, 31(8), 706–708. <https://doi.org/10.1177/0267659116646180>
- Parkhurst, C. N., Weir, D. C., Rajwani, K., & Narula, N. (2020). 'Acute Hypoxic Respiratory Failure and Diffuse Alveolar Haemorrhage Due to Intramuscular Injection of an Oil-Based Cosmetic Substance, D35 Drug Induced Lung Disease'. American Thoracic Society International Conference Abstracts Thematic Poster Session: Case Reports. May 23rd. San Diego Convention Centre. *American Journal of Respiratory and Critical Care Medicine*, 201, A6638.
- Pehlivanov, G., Kavaklieva, S., Kazandjieva, J., & Tsankov, N. (2008). Foreign-body granuloma of the penis in sexually active individuals (penile paraffinoma). *Journal of the European Academy of Dermatology and Venereology*, 22(7), 845–851.
- Peters, W., & Fornasier, V. (2009). Complications from injectable materials used for breast augmentation. *Canadian Journal of Plastic Surgery*, 17(3), 89–96.
- Peters, M. D. J., Godfrey, C. M., Khalil, H., McInerney, P., Parker, D., & Soares, C. B. (2015). Guidance for conducting systematic scoping reviews. *International Journal of Evidence-Based Healthcare*, 13(3), 141–146.
- Petersen, M. L., Colville-Ebeling, B., Jensen, T. H., & Hougen, H. P. (2015). Intramuscular Injection of "Site Enhancement Oil. *The American Journal of Forensic Medicine and Pathology*, 36(2), 53–55.
- Phillips, K. A., & Menard, W. (2006). Suicidality in body dysmorphic disorder: a prospective study. *American Journal of Psychiatry*, 163(7), 1280–1282.
- Prosperi-Porta, G., Oleynick, C., & Vaughan, S. (2020). Myositis from intramuscular oil injections in a bodybuilder available at: <https://doi.org/10.1503/cmaj.191500>
- Pupka, A., Sikora, J., Mauricz, J., Cios, D., & Płonek, T. (2009). The usage of synthol in the body building. *Polimery w Medycynie*, 39(1), 63–65.
- Restrepo, C. S., Artunduaga, M., Carrillo, J. A., Rivera, A. L., Ojeda, P., & Martinez-Jimenez, S. (2009). Silicone pulmonary embolism: report of 10 cases and review of the literature. *Journal of Computer Assisted Tomography*, 33, 233–237.
- Rosenburg, E., Romanowsky, I., Asali, M., & Kaneti, J. (2007). Three cases of penile paraffinoma, a conservative approach. *Urology*, 70, 371–372.
- Salinas, M., Floodgate, W., & Ralphs, R. (2019). Polydrug use and polydrug markets amongst image and performance enhancing drug users: Implications for harm reduction interventions and drug policy. *International Journal of Drug Policy*, 67, 43–51.
- Sarwer, D., & Polonsky, H. M. (2016). Body Image and Body Contouring Procedures. *Aesthetic Surgery Journal*, 36(9), 1039–1047.
- Sharobaro, V. I., Manturova, N. E., Ivanov, Y. V., Avdeev, Zabozaev, et al. (2019). Injected non-absorbable fillers in large volumes. *Khirurgiya*, 4, 42–51. <https://doi.org/10.17116/hirurgia201904142>, available at

- Schafer, C. N., Guldager, H., & Jorgensen, H. L. (2011). [Multi-organ dysfunction in bodybuilding possibly caused by prolonged hypercalcemia due to multi-substance abuse: case report and review of literature](#). *International Journal of Sports Medicine*, *32*(1), 60–65.
- Schafer, C. N., Hvolris, J., Karlsmark, T., & Plambech, M. Z. (2012). [Muscle enhancement using intramuscular injections of oil in bodybuilding: review on epidemiology, complications, clinical evaluation and treatment](#). *European Surgery-Acta Chirurgica Austriaca*, *44*(2), 109–115.
- Steffens, J., Kosharsky, B., Hiebl, R., Schönberger, B., Röttger, P., & Loening, S. (2000). [Paraffinoma of the external genitalia after auto injection of Vaseline](#). *European Journal of Urology*, *38*, 778–781.
- Thomas, J., Lee, J., Patton, T., & Choudhary, S. (2020). [Facial Sclerosing Lipogranuloma after Self-Injection of Homemade Tissue Filler: An Alarming New Practice](#). *Dermatologic Surgery*, *46*(5), 711–713.
- Torre, K., Murphy, M., & Ricketts, J. (2019). [Facial lipogranulomas due to self-injection of vitamin A oil](#). *International Journal of Women's Dermatology*, *5*(2), 126–128.
- Tricco, A. C., Lillie, E., Zarin, W., O'Brien, K., Colquhoun, H., & Kastner, M. (2016). [A scoping review on the conduct and reporting of scoping reviews](#). *BMC Medical Research Methodology*, *16*, 15.
- Wacquant, L. (2004). *Body & Soul: Notebooks of an Apprentice Boxer*. Oxford: Oxford University Press.
- Wilson, E., Rapues, J., & Raymond, H. (2014). [The use and correlates of illicit silicone or fillers in a population-based sample of transwomen](#). *The Journal of Sexual Medicine*, *11*, 1717–1724.
- Yeo, K. K., Park, T. H., & Chang, C. H. (2013). [Treatment of Foreign Body Granuloma of the Hand Associated with Unregulated Material Injection for Aesthetic Purpose](#). *Archives of Aesthetic Plastic Surgery*, *19*(1), 71–76.
- Underwood, Marie. (2017). [Exploring the social lives of image and performance enhancing drugs: an online ethnography of the yzzz fandom of recreational bodybuilders](#). *International Journal of Drug Policy*, *39*(1), 78–85.